



**RESEARCH ARTICLE**  
**MORPHOLOGICAL & HISTOLOGICAL STUDY OF THE KIDNEY IN GUINEA PIG**

**Hassaneen A.Al-Sharoot**

Department of Anatomy and Histology - College of Veterinary Medicine Al-Qadisiyah University

**ARTICLE INFO**

**Article History:**

Received 4<sup>th</sup>, October, 2014

Received in revised form 12<sup>th</sup>, October, 2014

Accepted 2<sup>nd</sup>, November, 2014

Published online 28<sup>th</sup>, November, 2014

**Key words:**

Morphological, Histological, Kidney, Guinea pig

**ABSTRACT**

The present work includes anatomical and histological study of the kidney of guinea pig. The current study was performed on (10) kidneys from (5) mature (male and female) gene pig clinically healthy. The animals were anaesthetized by the ether after which they were carefully dissected and examined.

The anatomic studies showed the urinary system of guinea pig was composed of two kidneys. The kidneys are retroperitoneal organs bean in shape, red pink in colour and situated in the posterior part of the abdomen on each side of the vertebral column. The mean weight of right and left kidney (0.205±1.998) mm. The mean length, width and thickness of right kidney (20.356± 0.850) mm, (14.396±830) mm, (8.198±0.450) mm respectively .While the mean length, width and thickness of left kidney (18.296±0.722) mm, (13.776±0.939) mm, (8.192±0.440) mm respectively. The cross section of kidney showed two anatomical distinct regions, the outer cortex and inner medulla, both terminate by renal papilla. The renal cortex is reddish brown in colour. The mean width of cortex and medulla of right kidney (5.554±0.371) mm, (5.508±0.180) mm respectively while the mean width of cortex and medulla of left kidney (5.780±1.792) mm, (5.492±0.205) mm respectively.

The result of histologic study demonstrate the kidney consist of outer dark red region (cortex) and inner lighter colored region (medulla) there is no evident boundary between the cortex and medulla . The renal corpuscle (malpighian) is a spherical structure formed of glomerulus, which is enclosed by a double-walled Bowman's capsule. Proximal convoluted thin tubules carctrestic by have widest lumen and internally lining by cuboidal epithelial cells which resting on the basement membrane. This cells characterized by have ground eosinophilic cytoplasm, large centrally nuclei and the apical surface covered by a brush border called microvilli. While the epithelial lining of distal convoluted tubules have extensive lumen and cuboidal cells have ground cytoplasm was clearly less eosinophilic than that of the proximal tubules and the apical surface of the distal convoluted tubule was uncovered by short microvilli.

© Copy Right, IJCLS, 2014, Academic Journals. All rights reserved.

**INTRODUCTION**

The experimental animals (mouse, rat, guinea pig and monkey) play important role for answering many problems in human medicine because the anatomical structure of the kidneys of different experimental animals was studied in order to understand the anatomical structure of human kidney (1, 2) because their anatomy and physiology resemble with human kidneys (3) .

The principle function of urinary system is conservation of water and electrolyte homeostasis and the second mager function of this system is the excretion of many toxic metabolic waste products particularly the urea and creatine (4).

The kidneys are complex organs play important role in removal of unwanted nitrogenous substances, excess water and relative maintenance of osmotic concentration of the blood(5,6).The present study was understand morphometric parameters and histology of the normal kidney in guinea pig ,this help to differentiate the abnormal status of kidneys while diagnosing and treating the animals, which are affected with different urinarytract diseases.

**MATERIAL AND METHODS**

**The Experimental Animals**

The material was consisted of 10 kidneys from five mature (male and female) clinically healthy of guinea pig. Guinea pigs were collected from a local commercial market of animals in Baghdad city weight between 500g and 800g. The animals were anaesthetized by the ether after which they were carefully dissected and examined.

**Anatomoto pographic study**

In this study, left and right kidneys were collected by abdomino-sternal approach. The biometrical parameters including (weight, length, width, circumference and thickness of right and left kidneys) were recorded.

The length, width and thickness of the kidneys were measured by use digital vernier calipers. Then the kidneys were bisected longitudinally to expose the inner structures subsequently, the thickness of cortex and medulla were estimated with the help of

\*Corresponding author : **Hassneen A.Al-sharoot**

Department of Anatomy and Histology - College of Veterinary Medicine Al-Qadisiyah University

digital vernier calipers (7).The results were documented with digital camera HTC (japan).

**Histologic study** Specimens for histology were collected immediately after gross examination .The specimens were fixed in 10% formal in for about 24 hours. The samples preserved in 70 % ethyl alcoholde hydrated in graded series of alcohol, cleared in xylene and embedded in paraffin wax as usual. Sections of 4–6 μ thickness were mounted on clean glass slides and stained with the haematoxylin and Eosin (Hx&E) for general structure.

**RESULTS**

**Gross study**

The urinary system of guinea pig was composed of two kidneys. The kidneys are retroperitoneal organsbean in shape, red pink in colure and situated in the posterior part of the abdomen on each side of the vertebral column.

They are attaching to the posterior extremity of the adrenal gland at the respective side. The right kidney was rostral and cranionmedially to the left kidney and cranial pole of the right kidney had impression on the caudal lobe of the liver. The kidneys are enclosed by a fibro connective smooth capsule and adipose tissue surrounding the hilus and sides of each kidney fig (1). Each kidney had cranial, caudal surface, medial, lateral border, upper and lower pole. The lateral border was convex in shape while the medial border was concave (2).

mm respectively table (2). The cross section of kidney showed two anatomical distinct regions, the outer cortex and inner medulla, both terminate by renal papilla. The renal cortex is reddish brown in colour. The mean width of cortex and medulla of right kidney (5.554±0.371) mm, (5.508±0.180) mm respectively table (1) while the mean width of cortex and medulla of left kidney (5.780±1.792) mm, (5.492±0.205) mm respectively table (2).

**Histologic study**

Observations the kidney consist of outer dark red region (cortex) and inner lighter colored region (medulla) there is no plain boundary between the cortex and medulla fig(3).

Microscopically the kidney isa compound tubular gland formed of components of the nephron includes the renal or (malpighian), the proximal convoluted tubule, the distal convoluted tubule, and the connecting tubule.The renal corpuscle (malpighian) is a spherical structure formed of glomerulus, which is enclosed by double-walled layers called(Bowman’s capsule). Bowman’s capsule has two layersvisceral and parietal layersfig (4). The internal or visceral layer surrounds the glomerular capillaries with modified epithelial cells called podocyte.

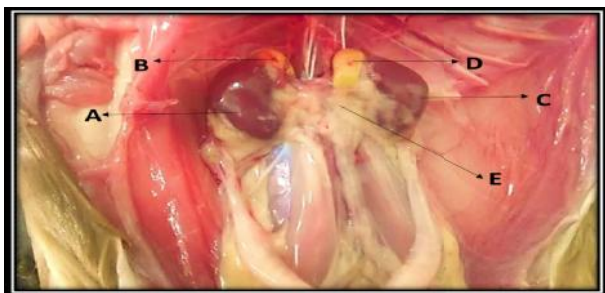
The space between the visceral layer and the parietal layer of the renal corpuscle is called the capsular (urinary) space fig (4).Proximal convoluted tubules is are thin structures carctrestic by have widest lumen and internally lining by cuboidal epithelial cells which resting on the basement

**Table1** Measurements Of Length, Width, Thickness Of Kidney, Width Of Cortex And Medullaof Right Kidney

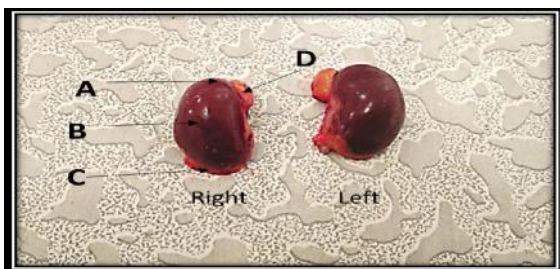
Width of medulla	Width of cortex	Thickness of kidney	Width of kidney	Length of kidney
5.508±0.180	5.554±0.371	8.198±0.450	14.396±0.830	20.356± 0.850

**Table 2** measurements of length, width, thickness of kidney,width of cortex and medulla of left kidney

Width of medulla	Width of cortex	Thickness of kidney	Width of kidney	Length of kidney
5.492±0.205	5.780±1.792	8.192±0.440	13.776±0.939	18.296± 0.722



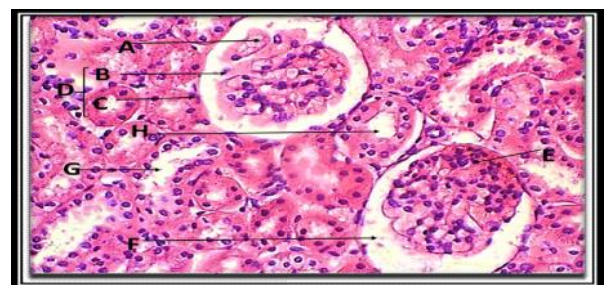
**Fig 1** A-Rightkidney B- Right adrenal gland C- leftkidney D- left adrenal glandE.Adipose tissue



**Fig (2)** A- Lateral border B- Cranial surface C- Medial border D- Adrenal gland

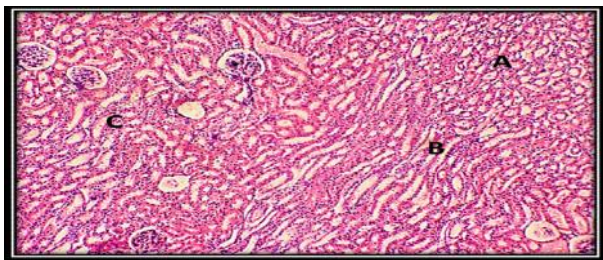
The mean weight of right and left kidney (0.205±1.998) mm. The mean length, width and thickness of right kidney (20.356±0.850) mm, (14.396±830) mm, (8.198±0.450) mm respectively table (1).While the mean length, width and thickness of left kidney (18.296±0.722) mm, (13.776±0.939) mm,(8.192±0.440)

membrane. This cells characterized by have ground eosinophilic cytoplasm, large centrally nuclei and have apical surface covered by a brush border called microvilli. While the epithelial lining of distal convoluted tubules have extensive lumen and cuboidal cells have ground cytoplasm was clearly less eosinophilic than that of the proximal tubules and the apical surface of the distal convoluted tubule was uncovered by short microvilli. Also found in the cortex are the medullary rays. The medullary rays include the following three types of tubules straight (descending) segments of the proximal tubules, straight (ascending) segments of the distal tubulesand the collecting tubules. The straight (descending) of the proximal tubules are muchrelated in the structure to the proximal convoluted tubules while the straight (ascending) segments of (5). The medulla contains only straight parts of the tubules and

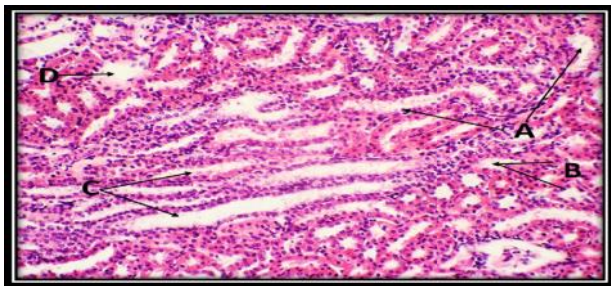


**Fig 4** Transversesection in cortex stain (H&E×400)  
A-Glomerulus, B- visceral layer, C- parietallayers,D- Bowman’s capsule, E-Podocyte , F- Capsular space ,G- convoluted tubule, H- proximal convoluted tubule.

the distal tubules are like to the distal convoluted tubules fig henle loop. Henle loop is the structure consists of(thick and thin descending segments and thin and thick ascending segments.



**Fig 3** Transverse section in kidney stain (H&E×100)  
Cortex B- Medulla C-corporcule



**Fig 5** Transverse section in cortex stain (H&E×400)  
A-Straight (descending) B- Straight (ascending) C- collecting tubules D- Henle loop

## DISCUSSION

The anatomical studies demonstrate urinary system of guinea pig was composed of two kidneys. The kidneys are retroperitoneal organs bean in shape and situated in the posterior part of the abdomen on each side of the vertebral column. The present observations are consistence with that observation of (8) in all mammals and (9) in desert rodents. The study confirmed the right kidney was rostral and cranionmedially to the left kidney. The irregular of the kidneys localization on each side of the vertebral column due to relative variation in growth of different organs in the abdominal and pelvic cavities during various phases of embryonic development ,that is agreement with the (10, 11) in laboratory animal while disagreed with the (12) who determine localization of the kidneys in rabbits correspond on the lumbar vertebrae and unlike with the (13) who presented disposal of the kidneys dependent of the level of artery vessel because not use artery vessel marker for the determine disposal of the kidneys .Also the results of this study showed slight difference between measurements of right and left kidney, these differences in values could be due to variations in age, breed and environmental factors, including the diets. The values in this study were also similar to those of (14) in laboratory rat.

Histologic study declares the normal kidney is subdivided into outer darker staining cortex and inner lighter staining medulla. The cortex contains distal, proximal convoluted tubule; glomerulus and medullary rays. The presence and development of this structure in large number in the cortex of kidney depend to functional renal disorders, species, gender and aging. This result confirmed the studies of (15) in normal rats and (16) in wistar rats.

Proximal convoluted thin tubules characteristic by have widest lumen and internally lining by cuboidal epithelial cells which covered by a brush border while the apical surface of the distal convoluted tubule was uncovered by short microvilli .That is agreement with

the (17) in rat. Presence of brush border significantly increases the surface area of the cell of the proximal convoluted tubule and thus permits the high rates of trans epithelial transport. In addition, brush border microvilli play a mechanosensory function in which fluid dynamic torque is transmitted to the actin cytoskeleton and modulates (Na<sup>+</sup>) absorption in proximal tubules. Similar observations are found by (18,19)

## Reference

1. Fourman, J. and Moffat, D. (1971). The blood vessels of the kidney. *Oxford Blackwell Scientific Publication*
2. Horacek, M.J. Earle; A.M and Gilmore, J.P. (1987). The renal vascular system of the monkey: a gross anatomical description. *Journal of Anatomy* 153:123-137.
3. Mc Dougall, EM; Clayman, RV. and Chandhoke, P.S. (1993). Laparoscopic partial nephrectomy in the pig model. *J. Urol* 149: 1633-1636.
4. Ojeda, J.L., Icardo, J.M. and Domezain, A. (2003). Introduction to Fishes. *Acipenseriformes*, 1: 285-293. Renal corpuscle of the sturgeon kidney: an ultrastructural, chemical dissection and lectin binding study. *The Anatomical Record. Pt:A.*, 272: 563-573.
5. Ritchison, G. (2008). Avian osmoregulation. Urinary system, salt glands and osmoregulation. *J. Exp. Biol.*, 554:17-31.
6. Salehi, E., and Morovati, M.S. (2012). Kidney Morphogenesis during Prenatal Development in Camelus dromedaries Embryoes. *J. Anim. Vet. Adv.*, 1(6), 822-825
7. Kamal, S., Bilal, A. (2007): Morphogenesis of Kidney in Crossbred Pig (*Sus scrofa*) Foetii. *Egypt. J. Morphol* 25 (1):129-132.
8. Young, Z. J. (1975): The Life of Mammals; Their anatomy and Physiology, second edition, clarendon press Oxford
9. El-salkh, B.A.; Zaki, Z.K; Basuony, M.I. and Khidr, H.A. (2008): Anatomical, Histological And Histochemical Studies On Some Organs Of True Desert Rodents In The Egyptian Habitats. *Egyptian Journal of Hospital Medicine* (2008) Vol., 33: 578- 306
10. Barone, R., and Chapitre. V. (2001): Anatomie comparée des mammifères domestiques. *Splanchnologie II. Tome quatrième, Troisième édition*, Editions Vigot, Paris, pp.843-859.
11. Brewer, N. (2006): Biology of rabbit. *Journal of the American Association for Laboratory Animal Science*, 45: 8-24, 2006.
12. Hristov, H., Kostov, D., and Vladova, D. (2006): Topographical anatomy of some organs in rabbits. *Trakia Journal of Sciences*, 4: 7-10. abdominal
13. Yokota, E., Kawashima, T., Oncubo, F., and Sasaki, H. (2005): Comparative anatomical study of the kidney position in amniotes using the origin of the renal artery as a landmark. *Okajimas Folia Anatomica Japonica*, 81:135-142.
14. Hebel, R. and Stromberg, M.W. (1976): Anatomy of the laboratory rat. *Williams and Wilkins Company*, Baltimore, pp: 62-65.
15. Bertram, J.F; Soosaipillai, M.C; Ricardo, S.D; and Ryan, G.B., (1992): Total numbers of glomeruli and individual glomerular cell types in the normal rat kidney. *Cell Tissue Res*; 270: 37-45.

16. Eze K. N. (2012): The reno-protective effects of coconut water on the kidneys of diabetic wistar rats. *Journal of Health Sciences*, 2(1): 1-4
17. El-gammal, A.R.; Ibrahim, O.y; shaban,S.F.and Dessouky,A.A.(2010): Postnatal development of the albino rat renal cortex (histological study) *Egypt. J. Histol.* Vol. 33, No. 4, Dec. 2010: 745 – 756.
18. Eurell, J.A.and Frappier, B.I. (2006): *Dellmanns Text book of veterinary histology* Black well publishing sixth Edition, Ames, usa.
19. Du,Z.; Duan , Y.; Yan , O.; Wein stein , A . M.; Weinbaum, S. and Wang, T (2004): Mech-anosensory function of microvilli of the kidney proximal tubule. *PNAS*, 101:13068-13073.

\*\*\*\*\*