

**RESEARCH ARTICLE**

**EXTRACRINAL MENINGIOMA OF PAROTID GLAND - RARE CASE**

**Dr.Nishant T.Chavhan**

Department of Zoology, Sir P. P. Institute of Science, Maharaja Krishnakumarsinhji Bhavnagar University, Bhavnagar, Gujarat, India

Received 14<sup>th</sup>, May, 2015 Received in revised form 23<sup>th</sup>, May, 2015 Accepted 13<sup>th</sup>, June, 2015 Published online 28<sup>th</sup>, June, 2015

**Key words:**

Meningioma , Parotid Gland

**Copyright © Dr.Nishant T.Chavhan.** This is an open-access article distributed under the terms of the Creative Commons Attribution License, which permits unrestricted use, distribution and reproduction in any medium, provided the original work is properly cited.

**INTRODUCTION**

Meningioma is a tumour arising from arachnoidal cells and, in the majority of cases, its behaviour is benign. It accounts for 24-30% of all intracranial tumours and has an incidence of 13/100,000 per year in Italy and 1.4-4.5/100,000 elsewhere<sup>1</sup>. Primary extracranial meningiomas are rare neoplasms of parotid gland which is frequently misdiagnosed, resulting in inappropriate clinical management.

**Case report**

32yrs old female patient having swelling over Lt parotid region since 1 yrs.

No history of facial palsy, pain, headache, vomiting, convulsion, wt.loss.

Local examination – there was swelling of size 5 x 3 cm present in Lt. parotid region, mobile, firm in consistency, not fixed to skin.

**CTscan neck & face-** benign swelling in the parotid region.

**Plan for superficial parotidectomy** - Modified Blair incision taken, Flap was raised, Facial nerve identified, All branches were identified. Superficial lobe was removed, incision closed in layer.(fig1,2,3)

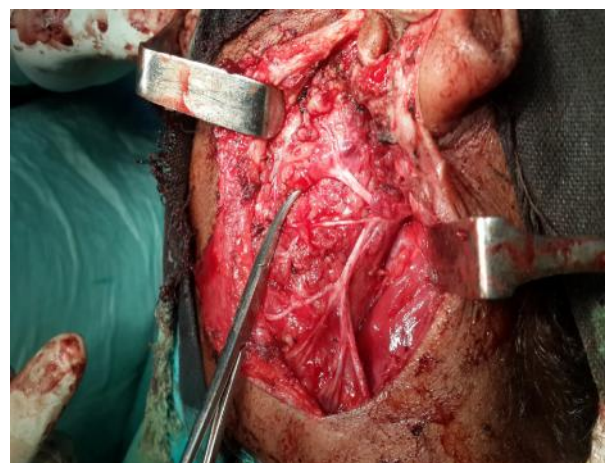
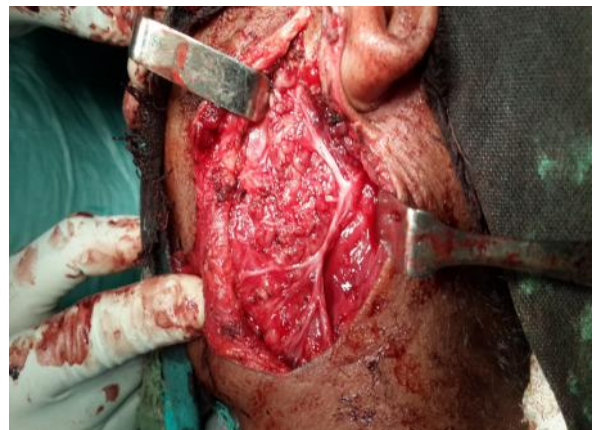**Histopathology report-** the section shows a nodular proliferation of polygonal & oval cells admits an infiltrate of lymphocytes & histiocytes.

The cells shows true nuclear chromatin, nucleoli & eosinophilic cytoplasm.

There is distinct whirling pattern seen at places.

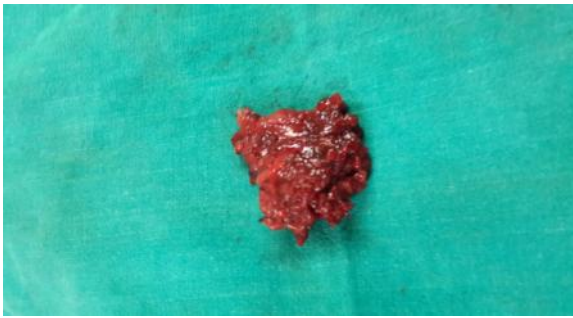
The tumour cell express EMA diffusely & S-100 protein focally.

There is no expression of the melanocytic marker (HMB-45), dendritic cell marker (CD21, CD35 & CD23), histiocytic markers CD68,CD163.



\*Corresponding author: **Dr.Nishant T.Chavhan**

Department of Zoology, Sir P. P. Institute of Science, Maharaja Krishnakumarsinhji Bhavnagar University, Bhavnagar, Gujarat, India



The tumour cells are immunonegative for cytokeratin, ERG, CD31, Alk-1, CD-30, CD1a & CK. The histological appearances are unusual. After exclusion of histiocytic dendritic cell sarcoma and an epithelial tumour, the diagnosis of an Extracranial Meningioma of the parotid gland. CT scan brain within normal limit.

## DISCUSSION

Primary extra cranial Meningiomas of head and neck region are rare tumours, the majority being a secondary location of a primary intracranial tumour, accounting for 1-2% of all meningiomas and with a generally favourable prognosis. Therefore, once the diagnosis of meningioma is established, the presence of a meningioma of the neuraxis or extension of a primary central meningioma should be excluded.

**Extracranial meningiomas**, also known as **primary extradural meningiomas** or ectopic meningioma, are rare location-specific type of meningiomas that arise outside the dural covering of the brain and spinal cord. They are basically extracranial tumours, most often occurring in the head and neck region, specifically in the sinonasal tract, temporal bone and ear, and in the scalp.

Extradural meningiomas do not have connections to the dura or any other intracranial structure<sup>2</sup>, while **secondary extradural meningioma** refers to those intradural meningiomas with extradural extension and/or metastasis.

The aetiopathogenesis of extracranial meningiomas resides in the migration of arachnoid cells deriving from the neural crest, but different theories assume that extradural meningiomas arise from the meningotheial cells that were entrapped within the skull sutures or fracture lines either congenitally or post traumatic respectively. Cutaneous meningiomas are believed to arise due to defect of neural tube closure led to entrapped meningocytes in subcutaneous tissue. Other theories postulate that meningiomas can arise from multipotent mesenchymal cells.

Extracranial meningiomas can occur in multiple locations like paranasal sinuses, skin, orbit, temporal fossa and oral cavity<sup>3</sup>. Other rare sites include nasal cavity, salivary glands, scalp and carotid artery bifurcation.

The largest series of extracranial head and neck meningiomas encompass 146 cases<sup>4</sup>, among which the majority was of the skin and scalp (n = 59), middle ear (n = 26), nasal cavity (n =

17), temporal bone (n = 2) and parotid gland (n = 1). Other large series consider the sinonasal tract (n = 30). Extracranial meningiomas exhibit various different histologic patterns just as their intracranial counterparts<sup>5</sup>. By cytology, meningotheiomatous cells show bland nuclei with delicate chromatin and intranuclear pseudoinclusions. The immunohistochemical profile of extracranial meningiomas is indistinguishable from intracranial lesions. All tumours expressed epithelial membrane antigen and vimentin, variable expression of protein S-100 and were negative for acidic gliofibrillary protein.

Differential diagnosis includes different benign and malignant tumours, such as epithelial neoplasms (carcinoma), tumours originating from the neural crest (melanoma, olfactory neuroblastoma) and vascular and mesenchymal tumours (angiofibroma, paraganglioma, ossifying fibroma)<sup>5</sup>. Histologic features and immunohistochemical findings can easily separate these entities, especially in the differential diagnosis between carcinoma and melanoma; in more intriguing cases immunohistochemistry for cytokeratins, S-100 protein and HM B-45 allows distinction from meningiomas. Prognosis of primary meningioma is generally excellent, thus supporting the indolent growth of meningiomas, except for rare malignant forms<sup>6</sup>. Therefore, histopathologic examination is necessary as it can distinguish these neoplasms from other head and neck tumours. In particular, frozen sections are particularly useful in assessing the surgical procedure and should be performed whenever possible to exclude the malignant nature of the lesion and avoid overtreatment. As for the clinical course, surgical excision was curative in these cases, in agreement with the lack of morphological features of aggressive behavior.

In general, the prognosis of extracranial meningiomas appears to be excellent, with an overall median survival of 28 years. This is tempered by the specific anatomic site, histologic type, tumor grade, gender, and age of the patient. The recurrence rate for meningiomas after total excision varies from 7% to 84% depending upon the number of years of follow-up<sup>4</sup>. Our patients are alive and disease-free after surgery.

## References

1. Louis DN, Ohgaki H, Wiestler OD, Cavenee WK, editors. WHO Classification of Tumours of the Central Nervous System. Lyon: International Agency for Research on Cancer; 2007. pp. 164–172.
2. Tokgoz N, Oner YA, Kaymaz M *et al*. Primary intraosseous meningioma: CT and MRI appearance. *AJNR Am J Neuroradiol*. 2005;26 (8): 2053-6
3. Rushing EJ, Bouffard JP, McCall S *et al*. Primary extracranial meningiomas: an analysis of 146 cases. *Head Neck Pathol*. 2009;3 (2): 116-30
4. Primary Extracranial Meningiomas: An Analysis of 146 Cases Elisabeth J. Rushing, John-Paul Bouffard, *et al*
5. Scheithauer BW. Tumors of the central nervous system. 3rd series ed. Washington, DC: Armed Forces Institute of Pathology; 1994. Tumors of meningotheial cells;
6. Huzar M, Fanburg JC, Richard Dickersin G *et al*. Retroperitoneal malignant meningioma. *AMJ Surg Pathol* 1996. 492-499