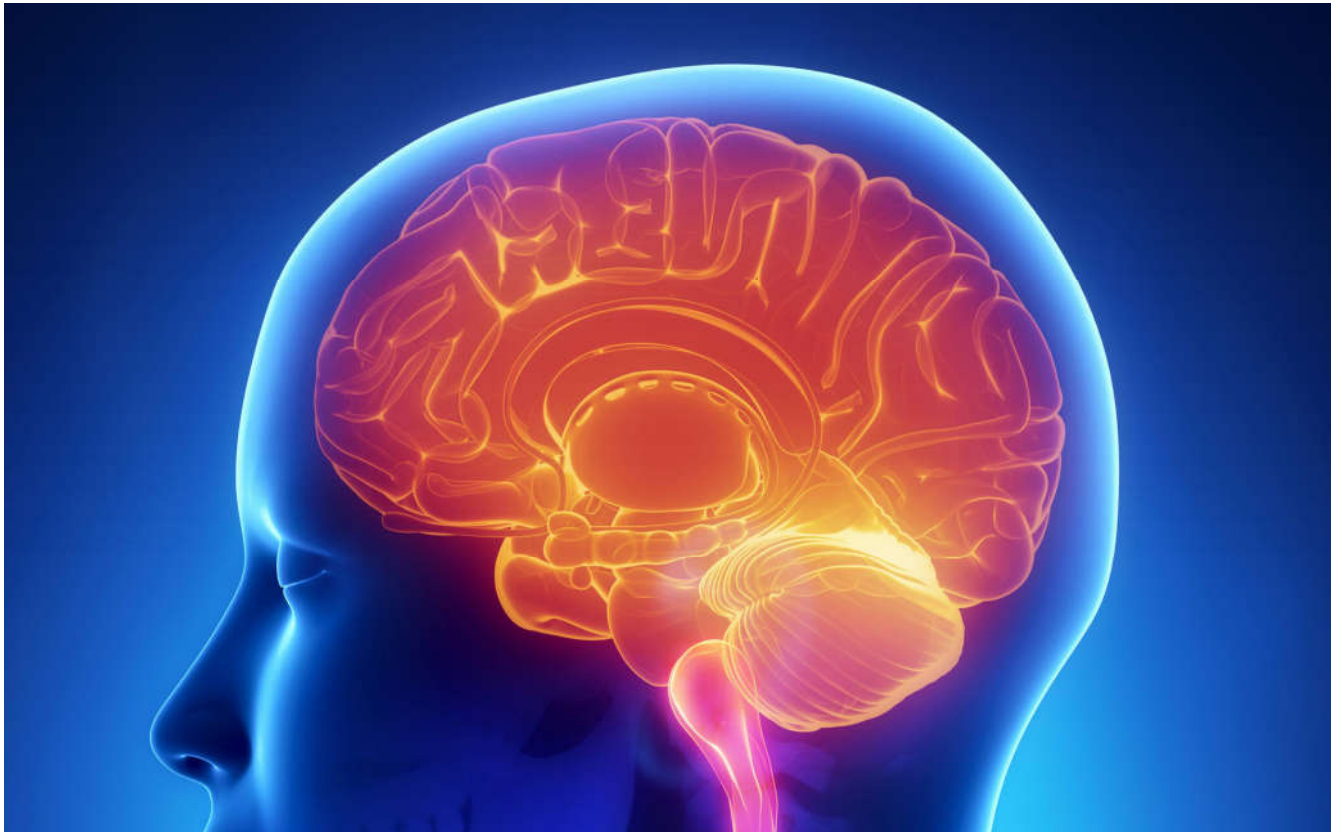



International Journal Of
**Recent Scientific
Research**

ISSN: 0976-3031

Volume: 7(11) November -2015

PREGNANCY ASSOCIATED BREAST CARCINOMA: A DIAGNOSTIC DILEMMA

Shilpa, Vikranth Suresh Nandurkar, Suresh T.N
and Mohan Kumar.K



THE OFFICIAL PUBLICATION OF
INTERNATIONAL JOURNAL OF RECENT SCIENTIFIC RESEARCH (IJRSR)
<http://www.recentscientific.com/> recentscientific@gmail.com

RESEARCH ARTICLE**PREGNANCY ASSOCIATED BREAST CARCINOMA: A DIAGNOSTIC DILEMMA*****Shilpa, Vikranth Suresh Nandurkar, Suresh T.N and Mohan Kumar.K**

Sri Devaraj Urs Medical College and Research hospital, Tamaka kolar, Karnataka. 563101

ARTICLE INFO**Article History:**Received 06th August, 2015Received in revised form 14th September, 2015Accepted 23rd October, 2015Published online 28st November, 2015**Key words:**

Breast, Carcinoma, Pregnancy, lactation

ABSTRACT

Breast carcinoma is uncommon in pregnancy. Pregnancy associated breast cancer is defined as breast cancer diagnosed during pregnancy or in the first postpartum year. Since breast carcinoma is very aggressive during this period it is important to diagnose as early as possible. The case report presented is of a 25yr old female para 2 living 1 presented with lump in the breast since 6 months. Patient had delivered a male baby 20 days back. On physical examination left breast was irregular and enlarged. Clinical diagnosis of Phyllodes tumour was made. Ultrasound was done & on FNAC diagnosis of Phyllodes tumour with malignancy cannot be ruled out was given. She underwent surgery and final diagnosis of ductal carcinoma was made on histopathological examination. Within a period of 8 wks she presented with lump in the opposite breast, axilla & local recurrence over the operated site. Also distant spread was seen in the form of skin nodules over neck region. Although majority of palpable breast lumps are benign high index of suspicion of malignancy is important even in pregnant women due to its aggressive nature.

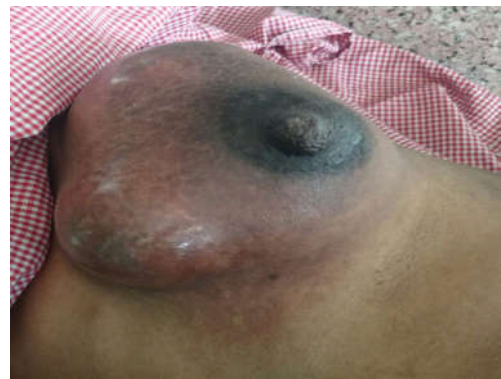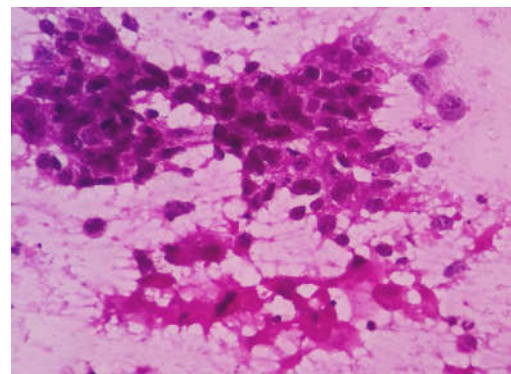
Copyright © Shilpa., 2015, This is an open-access article distributed under the terms of the Creative Commons Attribution License, which permits unrestricted use, distribution and reproduction in any medium, provided the original work is properly cited.

INTRODUCTION

Gestation or pregnancy associated breast cancer (PABC) is defined as breast cancer that is diagnosed during pregnancy, lactation or in the first 12 months postpartum. The incidence of breast cancer in pregnancy and post partum ranges from 2.3 to 40 cases/ 100000 women. (1) PABC is the malignancy that can occur concurrently with pregnancy and lactation. It carries worse prognosis when compared to breast cancer in non pregnant women. (2) It is found that in the age group of 25-29 years at least 20% of breast cancer are associated with pregnancy. (1) It is important to rule out breast carcinoma in pregnancy since the physiological changes induced by pregnancy and lactation may obscure the physical signs of the cancer and becomes difficult for detection of the malignancy.

Case Report

A 25yr old, para 2 living 1 postnatal women had delivered a male baby 20 days back came to surgery department with h/o lump in left breast since 6 months. It was rapidly increasing in size. On examination breast was enlarged and lump noted which was fully occupying the breast. Nipple and areola were normal (Fig 1). There was no nipple discharge & axillary lymphadenopathy. No significant family history. Routine lab investigations were done and was within normal limits. Clinical diagnosis of Phyllodes tumour was made.

**Fig 1** Gross photograph of the breast on physical examination**Fig 2** Microphotograph of FNAC showing cells with highly pleomorphic nuclei with prominent nucleoli and foamy cytoplasm (H&E 400X)

***Corresponding author: Shilpa**

Sri Devaraj Urs Medical College and Research hospital, Tamaka kolar, Karnataka. 563101

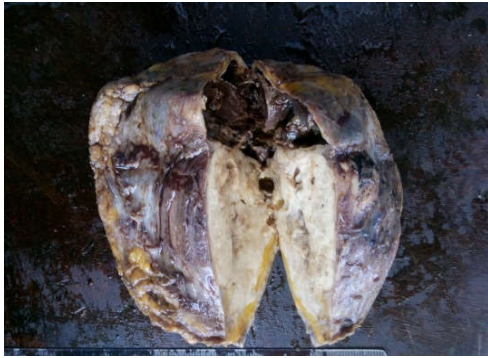

Fig 3 Gross photograph of the breast showing solid and cystic areas

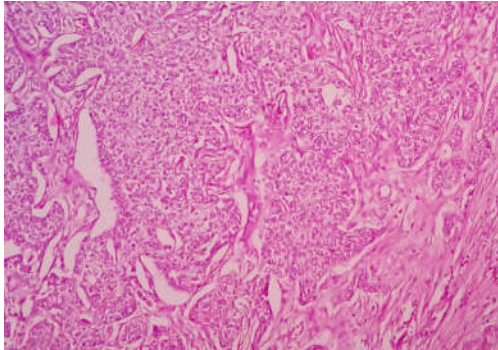


Fig 4 Microphotograph of infiltrating ductal carcinoma (H&E X 100)

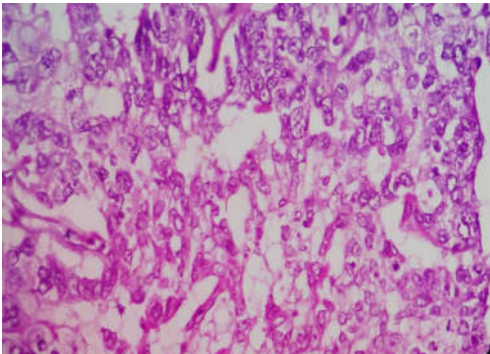


Fig 5 Microphotograph of infiltrating ductal carcinoma showing tumour cells with moderate amount of cytoplasm & vacuolation (H&E X 400)

Ultrasound was done and report of infected galactocele was given. FNAC was performed and reported as phyllodes tumour with lactational change with a note i.e., in view of cytological atypia possibility of malignancy cannot be ruled out (Fig 2)

Patient underwent modified radical mastectomy & was sent for histopathological examination. Grossly tumour was measuring 12x6.5x3cm and showed variegated appearance with solid and cystic areas. Cystic areas showed necrotic material. (Fig 3). Axillary tissue showed 26 lymphnodes. Microscopy showed round to polygonal tumour cells arranged in lobules, sheets and in clusters with moderate cytoplasm (Fig 4 & 5). At places tumour cells showed abundant eosinophilic to clear cytoplasm with moderately pleomorphic nuclei. Due to this feature we had a differential diagnosis of infiltrating ductal carcinoma with lactational changes, glycogen rich carcinoma, secretory carcinoma & apocrine carcinoma.

PAS stain was done it showed focal positivity. Areas of necrosis were also noted along with mitotic figures (5-6/10 hpf) on H&E. Out of 26 lymphnodes 24 lymphnodes showed

positive for metastasis. Final impression of infiltrating ductal carcinoma with lactational changes with stage pT3N2Mx & Bloom Richardson grading of 6 was given. IHC was done and it showed ER, PR & HER2neu negativity. Patient was advised chemotherapy but due to family problems she told will come back after few months. After 8wks she came with h/o swelling in the right breast & at the site of surgery. FNAC was done and it was signed out as infiltrating ductal carcinoma of right breast with metastasis to right axilla & recurrence at the site of surgery. On examination small tiny skin nodules were also found in the neck region. Further workup was done like USG-abdomen, X-ray chest and CT brain which were normal. Patient was referred to oncologist and now she is on chemotherapy treatment.

DISCUSSION

Malignant tumours in pregnant women are rare. Breast carcinoma is the second most common malignancy in pregnancy following carcinoma cervix (3). Leukemias and lymphomas are the most common malignant neoplasms in pregnant women under the age of 25years (4) but breast cancer during pregnancy and lactation at this age is very rare. Our case is unique on the basis of the age & she presented especially in the vicinity of no family history.

Majority of women with breast cancer during pregnancy present with painless lump in the breast (2). It is difficult to detect small malignant lumps in pregnant women because of breast engorgement and tenderness of the breast during pregnancy and lactation. Our patient was post partum and presented with painless lump in the breast which was gradually increasing in size.

Carriers of mutations in the genes BRCA1 & BRCA 2 may present a specific high risk group for PABC especially at younger ages.(1) The systemic and micro environmental changes during post lactational involution has been recognized in the pathogenesis of PABC.(5,6) Jesssica McCready *et al* study shows that the lactating microenvironment could promote the tumour to be more aggressive and also helps in tumour progression when compared to tumour in other stages of pregnancy.(7)

Breast ultrasonography in pregnancy is useful to distinguish between cystic and solid mass but not always possible to distinguish benign from malignant solid masses. The physiological alterations of pregnancy and lactation will obscure a malignant mass and can give raise to low index of suspicion of malignancy (2) which happened in our case in which diagnosis was missed both on ultrasound and FNAC. MRI is the another useful tool which can be used during pregnancy and lactation due to less radiation exposure when compared to mammography.

Microscopically it is a diagnostic challenge to diagnose breast cancer due to anatomical and physiological variation represented by lactation changes with increased N: C ratio and prominent nucleoli. The most commonly reported subtype during pregnancy is infiltrating ductal carcinoma. (8, 9). Since this case also showed lactational changes other differential

diagnosis like secretory carcinoma, glycogen rich carcinoma, apocrine carcinoma were also considered and were ruled out. The incidence of lymphnode involvement in pregnant and lactating women has been reported between 56% to 89 %.(10) Lymphnode involvement indicates the clinical aggressiveness and is the indicator of poor prognosis.

The estrogen and progesterone status of the PABC is most oftenly negative and theory behind this is mainly due to down regulation of the receptors due to increased levels of the estrogen and progesterone. (1) This case also showed ER and PR negativity. The treatment goal for breast cancer in a pregnant and lactating women is similar as for a non pregnant women i.e., to achieve local and systemic control of the disease. Surgery is the first line of treatment. If the women is not delivered radiotherapy and chemotherapy is not advised due to increase chance of foetal malformations. Majority of studies have showed that PABC has more advanced clinical and histological grading (1, 8, 11) Zemlickins *et al* noted that pregnant women with breast cancer had a twofold increased risk of metastasis with poor prognosis. (1)

CONCLUSION

Breast cancer during pregnancy and lactation is a rare medical problem. It is often diagnosed at an advanced stage. Therefore high index of suspicion is very important for the evaluation of the breast lump during pregnancy & lactation. Screening of the breast in all pregnant women is must during antenatal visits to prevent delay in diagnosis. Diagnosis of PABC requires histopathological examination.

References

1. Bure LE, Azoulay L, Benjamin A, Abenheim HA. Pregnancy-Associated breast cancer: *A Review for the Obstetrical Care Provider*. JOGC 2011; 330-337.

2. Al-Amri AM. Breast carcinoma in pregnancy and lactation: A diagnostic and therapeutic dilemma. *International Journal of Collaborative Research on Internal Medicine & Public Health* 2011; 3(7): 542-546.
3. Mathew M, Valiathan V, Rao L. Pregnancy and lactation- associated breast carcinomas. *Indian Journal of Pathology and Microbiology* 2010; 53(4): 884-886.
4. Jakubik J, Gottwald L, Kukulska M, Gora E *et al*. Breast cancer in pregnant women: report of two cases and review of the literature. *Arch Med Sci* 2008; 4(2): 204-207.
5. Gupta PB, Proia D, Cingoz O, Weremowicz J, Naber SP, Weinberg RA, Kuperwasser C. Systemic stromal effects of estrogen promote the growth of estrogen receptor-negative cancers. *Cancer Res* 2007, 67: 2062 –2071.
6. Lyons TR, O ' Brien J, Borges VF, Conklin MW, Keely PJ, Eliceiri KW, Marusyk A, Tan AC, Schedin P. Postpartum mammary gland involution drives progression of ductal carcinoma in situ through collagen and cox-2. *Nat Med* 2011, 17: 1109 –1115.
7. Mc Cready J, Arendt LM, Glover E *et al*. Pregnancy-associated breast cancers are driven by differences in adipose stromal cells present during lactation. *Breast cancer research* 2014, 16: 1-19.
8. Kihara AB, Gladewell K, Eunice CJ *et al*. Breast cancer in pregnancy; routine examination, diagnosis and management: A case report. *Case reports in clinical medicine* 2013; 2(2): 119-122.
9. Barnes DM, Newman LA. Pregnancy- Associated breast cancer: *A Literature review*. *Surg Clin N Am* 2007; 87: 417-430
10. Middleton LP, Amin M, Gwyn K *et al*. Breast Carcinoma in Pregnant Women. *Cancer* 2003; 98 (5): 1055-1060.
11. Ives AD, Saunders CM, Semmens JB. The Western Australian gestational breast cancer project: *a population based study of the incidence, management and outcomes*. *Breast* 2005; 14:276-82.

How to cite this article:

Shilpa., Pregnancy Associated Breast Carcinoma: A Diagnostic Dilemma. *International Journal of Recent Scientific Research Vol. 6, Issue, 11, pp. 7533-7535, November, 2015*

ISSN 0976-3031



9 770976 303009 >