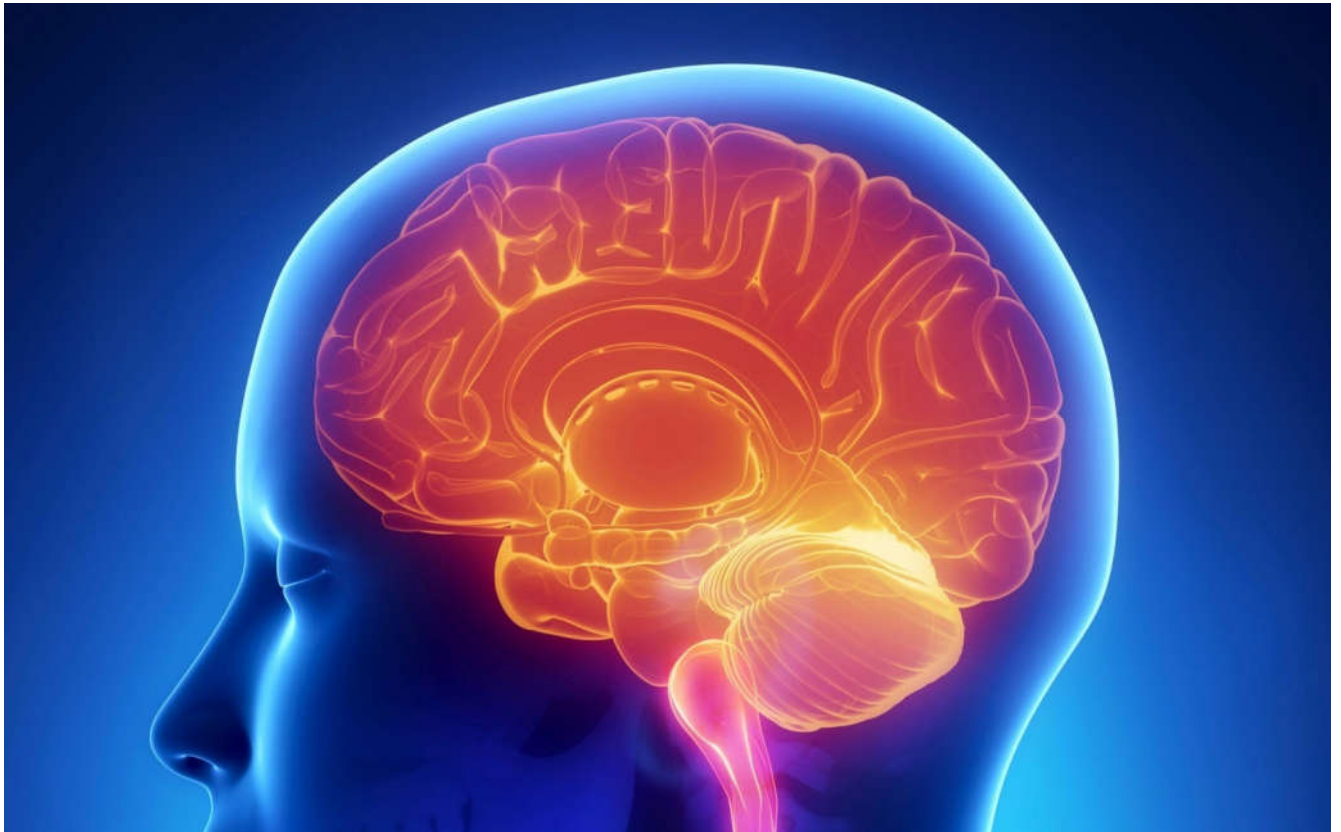



*International Journal Of*  
**Recent Scientific  
Research**

ISSN: 0976-3031  
Volume: 7(6) June -2016

DENTIGEROUS CYST ASSOCIATED WITH MANDIBULAR SECOND MOLAR – A RARE  
PRESENTATION AND REVIEW OF LITERATURE

Santosh Kurimilla MDS., Aditya Mohan MDS.,  
Gali Pradeep MDS and Arvind U.D



THE OFFICIAL PUBLICATION OF  
INTERNATIONAL JOURNAL OF RECENT SCIENTIFIC RESEARCH (IJRSR)  
<http://www.recentscientific.com/> [recentscientific@gmail.com](mailto:recentscientific@gmail.com)



ISSN: 0976-3031

Available Online at <http://www.recentscientific.com>

International Journal of Recent Scientific Research  
Vol. 7, Issue, 6, pp. 12020-12023, June, 2016

**International Journal of  
Recent Scientific  
Research**

## CASE REPORT

### DENTIGEROUS CYST ASSOCIATED WITH MANDIBULAR SECOND MOLAR – A RARE PRESENTATION AND REVIEW OF LITERATURE

Santosh Kurimilla MDS<sup>1</sup>, Aditya Mohan MDS<sup>2</sup>, Gali Pradeep MDS<sup>3</sup> and Arvind U.D<sup>2</sup>

<sup>1</sup>Mallareddy Dental College for Women, Secunderabad, Telangana, 500017

<sup>2</sup>Department of Oral & Maxillofacial Surgery, Panineeya Dental College, Hyderabad, Telangana, 500060

<sup>3</sup>CKS Teja Dental College Tirupathi, Chittoor, Andhra Pradesh, 517001

#### ARTICLE INFO

##### Article History:

Received 05<sup>th</sup> March, 2016

Received in revised form 08<sup>th</sup> April, 2016

Accepted 10<sup>th</sup> May, 2016

Published online 28<sup>st</sup> June, 2016

##### Key Words:

Unilocular radiolucency, Delayed eruption, Dentigerous cyst, Enucleation

#### ABSTRACT

**Introduction:** A dentigerous cyst is the most common developmental odontogenic cyst and is frequently noted as an incidental finding on radiographs. The most common teeth affected are impacted mandibular third molars and permanent maxillary canines. This case involves a dentigerous cyst of the right impacted second mandibular molar. This is a rare presentation of a dentigerous cyst involving second permanent molar.

**Case presentation:** The patient presented to the clinic for orthodontic treatment. The patient was a 14-year, one-month-old Asian boy. On radiographic evaluation, there was a unilocular radiolucency of 8 mm around mandibular second molar. A CT Scan was taken. Aspiration of the lesion resulted in a straw yellow colored aspirate. A diagnosis of dentigerous cyst was made. Surgical excision of the cyst along with the extraction of the offending tooth was done. The histopathological examination confirmed the clinical diagnosis.

**Conclusion:** This case involves an unusual presentation of a dentigerous cyst in association with the second molar. It shows a rare presentation that medical professionals, specifically dentists and radiologists, should be aware of. This additional knowledge is important for inclusion on differential diagnosis lists and aids in the development of a proper treatment plan.

Copyright © Santosh Kurimilla MDS *et al.*, 2016, this is an open-access article distributed under the terms of the Creative Commons Attribution License, which permits unrestricted use, distribution and reproduction in any medium, provided the original work is properly cited.

## INTRODUCTION

Cysts of the jaw usually present as asymptomatic swellings of the Maxillofacial region. Odontogenic cysts are the ones that develop from odontogenic epithelium or the epithelial remnants of the odontogenic apparatus. [1]. Dentigerous cysts are the second most common odontogenic cysts after radicular cysts, accounting for approximately 24% of all true cysts in the jaws. Their frequency in the general population has been estimated to be 1.44 cysts for every 100 unerupted teeth. [2]. The formation of a tooth occurs inside a developmental sac known as the dental follicle or the dental sac which surrounds the papillae of the tooth and enamel. Damante [3] has characterized the follicle as a remnant of tissues that participate in the odontogenesis and remained circum adjacent to the crown of a tooth which has not erupted normally. Dentigerous cysts are associated with crown of unerupted teeth, odontomas [4], or

supernumerary teeth [5] and deciduous teeth [6]. The second molars are very rarely associated with the dentigerous cyst. The incidence is more common in males than females [7]. It occurs at any age but the greatest incidence is in the second and third decade [8]. The cyst being asymptomatic may attain a large size with resorption of the roots of teeth till it manifest clinically or become evident radiographically. It is now documented that the dentigerous cyst lining has the potential to develop into an aggressive ameloblastoma [9]. Treatment includes enucleation of the cyst with the removal of the unerupted tooth. Marsupialization is occasionally done with very large cyst to decompress the cyst. Prognosis is excellent and recurrence is rare if completely removed.

## CASE REPORT

A 14 year old boy attended to a dental clinic for the correction of irregular teeth. On routine clinical examination, mandibular

\*Corresponding author: Santosh Kurimilla MDS

Mallareddy Dental College for Women, Secunderabad, Telangana, 500017

2<sup>nd</sup> molar was missing clinically. No pathology was found during extraoral examination. The patient was advised for routine radiographs. The orthopantomogram revealed an unerupted second molar surrounded by a unilocular radiolucency of around 8 mm on the crown. For a better special orientation of the lesion, a Computed tomographic scan was advised.

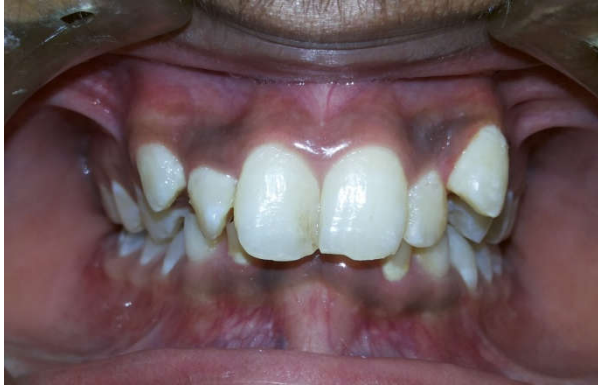

Fig 1 Intra oral Picture of the crowding

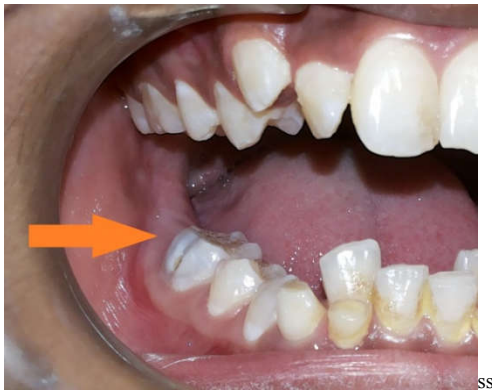

Fig 2 Missing 2nd molar

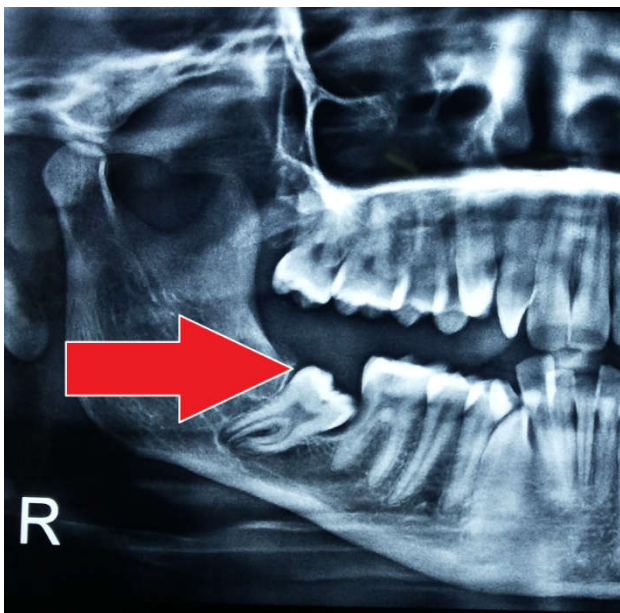


Fig 3 OPG Showing impacted tooth with a radiolucent lesion around it.

The CT scan reveals evidence of unilocular radiolucency around unerupted tooth at the posterior border of the mandible measuring about 9 × 8 mm. the lesion has caused cortical thinning. The case was posted for surgical excision. On

aspiration, there was a straw yellow colored fluid. The provisional diagnosis of Dentigerous cyst was made.

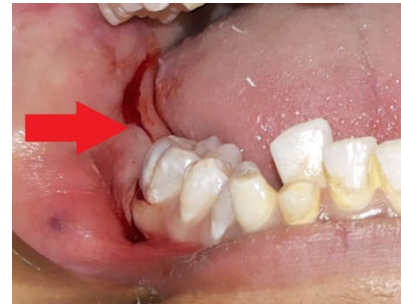

Fig 4 Incision

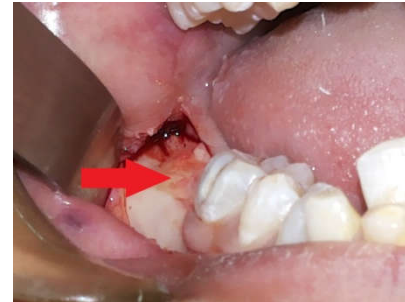

Fig 5 Exposure of the lesion

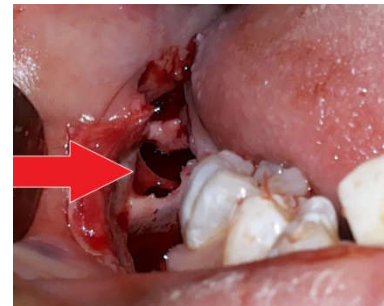
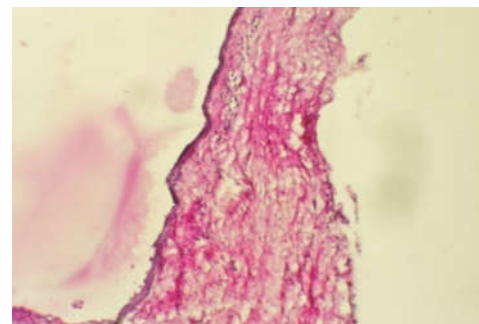
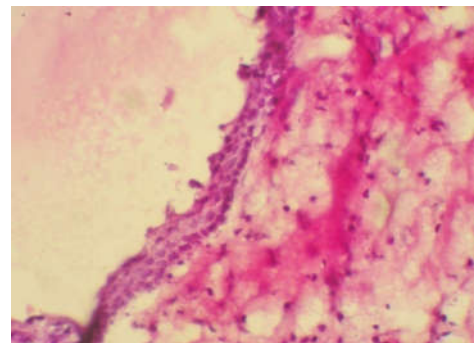


Fig 6 Enucleation of lesion



Under all aseptic conditions, a crevicular incision along with anterior and posterior releasing incisions was given. The cyst

was identified and carefully dissected from the surrounding bone. Enucleation along with the tooth was done. The tissue was sent for histopathologic examination.

The histopathological examination showed cystic cavity lined by single layered squamous cells. The connective tissue capsule is delicate with few chronic inflammatory cells.

## DISCUSSION

An impacted tooth is one of the most common complaints of patients presenting to an Oral and Maxillofacial surgeon for treatment. Any teeth in the oral cavity can be impacted but the most commonly affected tooth is the lower third molar. The impaction of the second molar is a rare complication in tooth eruption. The incidence is approximately 0.03% to as high as 3%, depending on the study. It usually occurs unilaterally more commonly than bilaterally and occurs slightly more often in men. It is more common in the mandible than maxilla [10]. A study by Mourshed state that 1.44 % of the impacted teeth may show dentigerous cyst formation [11].

A dentigerous cyst is one that encloses the crown of an unerupted tooth by expansion of its follicle, and is attached to its neck [12]. It was called as follicular cyst. The term dentigerous is preferred, the literal meaning being 'tooth bearing' [13]. The diagnostic feature of this cyst is the presence of the unerupted tooth in its cavity [14]. In order of its frequency, dentigerous cysts are associated mandibular third molars, maxillary canines, mandibular second premolars and maxillary third molars [15]. Our case was related with permanent mandibular second molar which is a very rare entity. Most of the dentigerous cysts are small asymptomatic lesions that are discovered serendipitously on routine radiographs, although some may grow to considerable size causing bony expansion that is usually painless until secondary infection occurs [9]. Our case was also found incidentally during the radiographic examination.

The pathogenesis of dentigerous cyst is still controversial. Shear advocates an inter-follicular origin in the development of dentigerous cyst. He presumes that it starts with fluid accumulating between the reduced enamel epithelium and the enamel, or between the layers of the reduced enamel epithelium and the enamel. The pressure of the erupting tooth may cause obstruction of the venous flow resulting in exudation of serum from the capillary walls. Toller postulated that dentigerous cysts develop from the follicular proliferation, which would eventually lead to impaction, however the induction of proliferation is not known. It appears that in certain cyst-prone individuals the cyst develops between the reduced enamel epithelium and the crown of an unerupted tooth and genetic factors are believed to contribute to the process [16].

Radiographically, the dentigerous cyst presents as a well-defined unilocular radiolucency, often with a sclerotic border. Three types of dentigerous cyst have been described radiographically: The central variety, the lateral variety and the circumferential variant. The histological features of dentigerous cysts may vary greatly depending mainly on whether or not the cyst is inflamed [17]. Our case was radiographically a classic presentation of the circumferential variety and a non inflamed one.

The standard treatment for a dentigerous cyst is enucleation [18]. However, large dentigerous cysts may be marsupialized and the cyst can be excised at a later date with a less extensive surgical procedure [19]. However, most reports agree that the treatment of choice is enucleation with the removal of the tooth. In addition to, it must not be forgotten that the major disadvantage of the marsupialization is that, pathologic tissue is left insitu without thorough histologic examination.

Although dentigerous cyst was considered to be a benign lesion, the epithelial lining has the potential to undergo neoplastic change and development of carcinoma is possible [20]. In this case considering all the conditions, cyst enucleation with the removal of the tooth was done.

## CONCLUSION

Though dentigerous cyst is a common odontogenic cyst of Maxillofacial region, its association with an impacted permanent mandibular second molar is a rare phenomenon. Therefore it must be considered that whenever there is absence of any permanent tooth, early detection consisting of a thorough clinical and radiographic examination is necessary for accurate diagnosis and proper treatment planning to avoid unwanted effects on adjacent teeth. In the present case, the dentigerous cyst was treated with surgical enucleation along with the tooth.

## References

1. Bela Dave, Dilip Dave, Dhaval N Mehta, VIRAL Thakker & Hitesh Vadera: A Rare Case of Expansile Keratocystic Odontogenic Tumour within Ramus of Mandible: *J Res Adv Dent* 2014; 3:1:172-179.
2. Jagveer Singh Saluja, M. J. Ramakrishnan, G. B. Vinit, And C. Jaiswara: Multiple dentigerous cysts in a nonsyndromic minor patient: Report of an unusual case: *Natl J Maxillofac Surg.* 2010 Jul-Dec; 1(2): 168-172.
3. Jose Humberto Damante E, Raul Negrao Fleury: A contribution to the diagnosis of the small dentigerous cyst or the paradental cysts. *Pesqui Odontol Bras*2001; 15(3):238-246.
4. Sangeeta P. Wanjari, Satyajitraje A. Tekade, Rajkumar N. Parwani, and Sunita A. Managutti: Dentigerous cyst associated with multiple complex composite odontomas: *Contemp Clin Dent.* 2011 Jul-Sep; 2(3): 215-217.
5. Qian Jiang, Guang-Zhou Xu, Chi Yang, Chuang-Qi Yu, Dong-Mei He, and Zhi-Yuan Zhang : Dentigerous cysts associated with impacted supernumerary teeth in the anterior maxilla: *Exp Ther Med.* 2011 Sep-Oct; 2(5): 805-809.
6. Kusukawa J, Irie K, Morimatsu M, Koyanagi S, Kameyama T: Dentigerous cyst associated with a deciduous tooth. A case report: *Oral Surg Oral Med Oral Pathol.* 1992 Apr; 73(4):415-8.
7. Vikrant O. Kasat, Freny R. Karjodkar, and Ruchi S. Laddha: Dentigerous cyst associated with an ectopic third molar in the maxillary sinus: A case report and review of literature: *Contemp Clin Dent.* 2012 Jul-Sep; 3(3): 373-376.
8. Rs Desai, Ss Vanaki, Rs Puranik, As Tegginamani: Dentigerous cyst associated with permanent central

- incisor: A rare entity: J Indian Soc Pedo Prev Dent Mar : 2005 | Volume : 23 | Issue : 1 | Page : 49-50.
9. Shubhangi Mhaske, Raju Ragavendra T, J J Doshi, Imtiyaz Nadaf: Dentigerous Cyst associated with impacted permanent maxillary canine: People's Journal of Scientific Research 17 Vol.2 (2), July 2009.
  10. Pamela L. Alberto: Management of the Impacted Canine and Second Molar Oral Maxillofacial Surg Clin N Am 19 (2007) 59–68.
  11. Mourshed F. A roentgenographic study of dentigerous cysts: incidence in a population sample. Oral Surg Oral Med Oral Pathol 1964; 18: 47-53
  12. Shear M, Speight P: Cysts of the Oral and Maxillofacial Regions. 4th Edn.; Blackwell Publishing Ltd., 2007:pp59-78.
  13. Browne RM, Smith AJ: Pathogenesis of odontogenic cysts. In: Investigative Pathology of the Odontogenic Cyst. CRC Press Boca Raton, 1991; pp. 88–109
  14. Johnson LM, Sapp JP, MC Intire DN: Squamous cell carcinoma arising in a dentigerous cyst. *Journal of Oral & Maxillofacial Surgery*, 1994; 52: 987–90.
  15. Neville BW, Damm DD, Allen CM, Bouquot JE. Odontogenic cysts and tumors. In: Neville BW, Damm DD, Allen CM, Bouquot JE, editors. Oral and Maxillofacial Pathology. 2nd ed. Philadelphia: WB Saunders; 2002. pp. 589–642.
  16. K.Ramesh, Maya.R, G.M. Karthik, Stephen Arokiaraj. C. J, Karthik Venkataraghavan: Management of Dentigerous Cyst Occurring in an Uncommon Maxillary Anterior Region – A Report of 2 Cases: *Int. Journal of Contemporary Dentistry*: December, 2011, 2(6) .
  17. Karthik Rajaram Mohan, Balan Natarajan, Sudhaamani Mani, Yasmeen Ahmed Sahuthullah, Arivukkadal Vijaya Kannan, And Haritha Doraiswamy: An Infected dentigerous cyst Associated with an Impacted Permanent Maxillary Canine, Inverted Mesiodens and Impacted Supernumerary Teeth : *J Pharm Bioallied Sci*. Jul 2013; 5(Suppl 2): S135–S138.
  18. M.C. Buyukkurt, M.M. Omezli, O. Miloglu: Dentigerous cyst associated with an ectopic tooth in the maxillary sinus: a report of 3 cases and review of the literature: *Oral Surgery, Oral Medicine, Oral Pathology, Oral Radiology and Endodontics*: Volume 109, Issue 1, Pages 67–71, January 2010
  19. Mahmut Sumer, Burcu BAŞ, Levent Yildiz: Inferior Alveolar Nerve Paresthesia Caused by a Dentigerous cyst associated with three teeth: *Med Oral Patol Oral Cir Bucal* 2007; 12:E388-90.
  20. K. M. K. Masthan, S. Rajkumari, M. Deepasree, N. Aravindha Babu AND S. Leena Sankari: Neoplasms Associated With Odontogenic Cysts: *Journal of Dentistry and Oral Hygiene* Vol. 3(10), pp.123-130, 18 November, 2011

\*\*\*\*\*

**How to cite this article:**

Santosh Kurimilla MDS et al. 2016, Dentigerous Cyst Associated With Mandibular Second Molar – A Rare Presentation And Review of Literature. *Int J Recent Sci Res*. 7(6), pp. 12020-12023.

T.SSN 0976-3031



9 770976 303009 >