



ISSN: 0976-3031

Available Online at <http://www.recentscientific.com>

International Journal of Recent Scientific Research  
Vol. 7, Issue, 7, pp. 12400-12404, July, 2016

**International Journal of  
Recent Scientific  
Research**

## Research Article

### DERMATOGLYPHICS-AS A DIAGNOSTIC TOOL IN DETECTION OF MALOCCLUSION

**Jaskiran Kaur, Vijender Khokhar and Anuradha pathak**

Department of Pedodontics and Preventive Dentistry, GDC Patiala

#### ARTICLE INFO

##### Article History:

Received 05<sup>th</sup> April, 2016

Received in revised form 08<sup>th</sup> May, 2016

Accepted 10<sup>th</sup> June, 2016

Published online 28<sup>st</sup> July, 2016

##### Key Words:

Malocclusion Children Dermatoglyphic

#### ABSTRACT

**Aim:** "To Study the Relation of Dermatoglyphics With Malocclusion In Children Of 12-14 Years."

**Material and methodology:** - A total of 70 children aged 12-14 years, were selected. Fingerprints were collected using fingerprint bioscanner machine. The fingerprints were analyzed using the classification given by Galton and fingertip pattern frequencies were calculated. The molar relation was determined according to Angle's classification of malocclusion. The relation of fingerprints was studied with the molar relation recorded using the study models. Dermatoglyphic parameters were examined in these subjects

**Results:** The percentage frequency of occurrence of fingertip patterns was noted separately for right and left hands and finally combined scores for each of these were recorded. Comparison of fingerprint pattern with the type of occlusion was done. It was seen that no fingerprint pattern was specific for a particular class of malocclusion, increased tendencies toward high frequencies of whorls in subjects with class II malocclusion with a percentage frequency of 49.38% was seen. Ulnar loop fingertip pattern was common in children with ideal occlusion with a percentage frequency of 73.3%.

**Conclusion:** Establishment of the genetic component of malocclusion and individual susceptibility to this condition early in life could aid the planning of preventive and interceptive procedures. Dermatoglyphic analysis can be used as an indicator of malocclusion at an early age, thereby aiding the development of treatment aiming to establish favorable occlusion. Prospective studies would be valuable for the establishment of dermatoglyphic markers of malocclusion.

Copyright © Jaskiran Kaur, Vijender Khokhar and Anuradha pathak, 2016, this is an open-access article distributed under the terms of the Creative Commons Attribution License, which permits unrestricted use, distribution and reproduction in any medium, provided the original work is properly cited.

## INTRODUCTION

Malocclusion is one of the most commonly reported oral condition. It can be prevented, intercepted and corrected. The first step towards its prevention is knowing about the level of risk for malocclusion. Preventive and interceptive orthodontics can be best applied if early diagnosis of malocclusion is done. Since, genetic factors are one of the implicated putative aetiologic factors for malocclusion, thus their role in early diagnosis is important to study.

As stated by Cummins and Mildo, dermatoglyphics (Dermaskin, glype-carve) is the dermal ridge configuration of digits, palms and soles. In ancient India, ridge pattern study was known as "Samudra Shastra". Arches, loops, and whorls (Galton) are the common ridge patterns present on the fingertips. Loops may be Ulnar or Radial. These patterns are characterized by presence or absence of tri radii i.e. confluences of three ridge systems. An arch has no tri radius, a loop has one and a whorl has 2 or more tri radius.

Dermatoglyphics is considered to be a window of congenital abnormalities and is also an indicator of intrauterine anomalies.

Grew in 1684 was the first person, in the Western World, to study dermatoglyphics. Holt (1968) and Verbov<sup>15</sup> (1970) strengthened the predictive validity of dermatoglyphics in medical biology, suggesting that it can aid the diagnosis of genetically and non genetically determined diseases. Cummins (1939) first reported association of specific dermatoglyphic patterns in patients with Down's syndrome which is a genetic disorder. Many investigators noted dermatoglyphic variations between normal individuals and patients affected by chromosomal anomalies like trisomy 8, trisomy 13, trisomy 18, Adams and Niswander noted dermatoglyphic variations in cleft lip and palate cases. Reasons for the above variations in dermatoglyphic findings associated with various diseases and syndromes may be attributed to the fact that morphogenesis of dermatoglyphic structures and organogenesis are co-incident with same time period and programmed by genetic expressions which are interrelated. It is known that any factor active during the time period of genetic expression is bound to affect the structures developing at that time. The development of palate and dermal ridges occur simultaneously during the first trimester of intrauterine life. The epidermal ridges of the fingers and palm and the facial structures originate from the

\*Corresponding author: **Jaskiran Kaur**

Department of Pedodontics and Preventive Dentistry, GDC Patiala

same embryonic tissue: ectoderm. Dermal ridges originate from volar pads, which appear at 6–7 weeks of gestation. The dermal ridge configuration reaches its maximum at around 13 weeks of gestation and is completely established by the 24th week of gestation. After that they remain constant and the configuration changes only in its size (Cummins and Midlo, 1961). Facial development begins as early as the 4th week of gestation. Development of the palate begins in the 6th week and is completed by the 12th week of gestation (Kumar, 2008)<sup>6</sup>. Thus, the face and dermal ridges not only have same origins, but also develop concurrently; so the genetic message contained in the genome is deciphered during this period and is also reflected in dermatoglyphic patterns.

Since both dermal patterns and oral structures are strongly but not exclusively genetically governed structures, it may be stated that hereditary and genetic factors causing changes in the palate may also cause peculiarities in fingerprint pattern. Hence, any abnormality in the genome could be reflected through dermatoglyphics. This might lead to a possible association of dermatoglyphics with malocclusion.

Also, relation of dermatoglyphics with dental occlusion is studied due to the fact that after the complete formation of dermal ridges, there is no change in their shape and remain in position throughout person's life.

Thus, the present study was undertaken to ascertain the reliability of dermatoglyphics as a predictive tool for malocclusion in order to apply preventive and interceptive orthodontics to the high risk groups. The purpose of the study was to study the relation of dermatoglyphics with malocclusion in children of 12-14 years.

## MATERIALS AND METHODS

The study sample consisted of 70 children in the age group of 12 to 14 years. Details of procedure were explained to parents and informed consent was obtained prior to study.

### Criteria for selection

The criteria for selection of the subjects were as follows:-

1. All permanent teeth present in each arch (excluding third molars).
2. No previous history of orthodontic treatment in either arch.
3. No large coronal restorations that might have altered both coronal shape and size.
4. Patient with a history of trauma or surgical procedures done in orofacial region were not included.

## MATERIALS

1. Gloves.
2. Mask.
3. Mouth mirror.
4. Impression trays.
5. Alginate impression material.
6. Dental stone.
7. Fingerprint bioscanner.
8. Magnifying lens.

## METHODOLOGY

The study sample consisted of 70 children between the age group of 12-14 years.

For recording the fingerprints, the hands of the subjects were cleaned with soap and water. The impression of individual digits was made by placing the bulb of the digit onto the surface of the bioscanner. The impression of remaining digits of both right and left hand were made in a similar manner. The fingerprints were analyzed using the following classification<sup>4</sup>:

Description of dermatoglyphic parameters recorded in the study:

1. Arch (figure 1)	The plain arch is composed of ridges which pass across the finger with slight bow distally. There are no triradii.
2. Whorl (figure 1)	The shape of the pattern area may be either circular or elliptical. Whorls have two triradii
3. loop (figure 1)	It possesses only one triradius. Twist site of ridges is called head of the loop. From the opposite extremity of the pattern, the ridges flow to the margin of digits. If the loop opens to the ulnar side, it is an ulnar loop and if to the radial margin, it is called a radial loop.

### Finger tip Dermatoglyphic patterns (figure 1)

For recording the molar relation, alginate impressions of both the maxillary and mandibular arch were made and study models were prepared.


On the study models, the molar relation was determined according to Angle's<sup>[1]</sup> classification of malocclusion.(figure 2)

1. Angle's Class I relation: Mesiobuccal cusp of the maxillary first permanent molar articulates in the mesiobuccal groove of the mandibular first permanent molar.
2. Angle's Class II relation: The mesiobuccal cusp of maxillary first permanent molar articulates mesial to mesiobuccal groove of mandibular first molar.
  - Angle's Class II Division 1: A class II molar relation in which maxillary incisors are inclined labially, and increased overjet is present.
  - Angle's Class II Division 2: A class II molar relation in which maxillary central incisors are inclined lingually, and maxillary lateral incisors have tipped.
3. Angle's Class III relation: The mesiobuccal cusp of maxillary first permanent molar occludes distal to mesiobuccal groove of mandibular first molar.

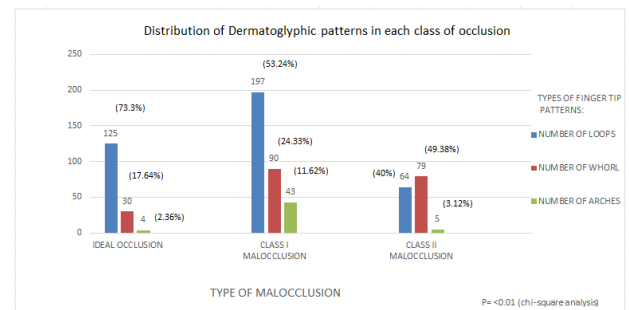
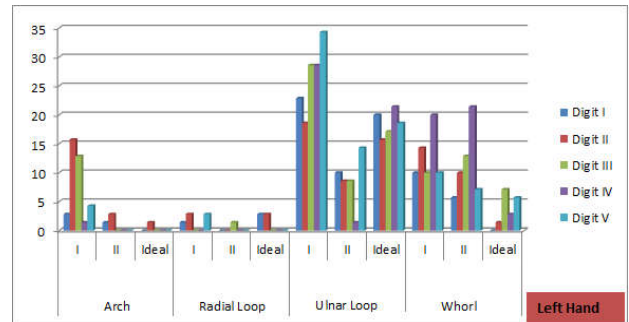
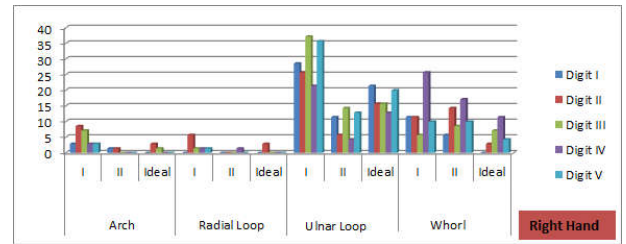
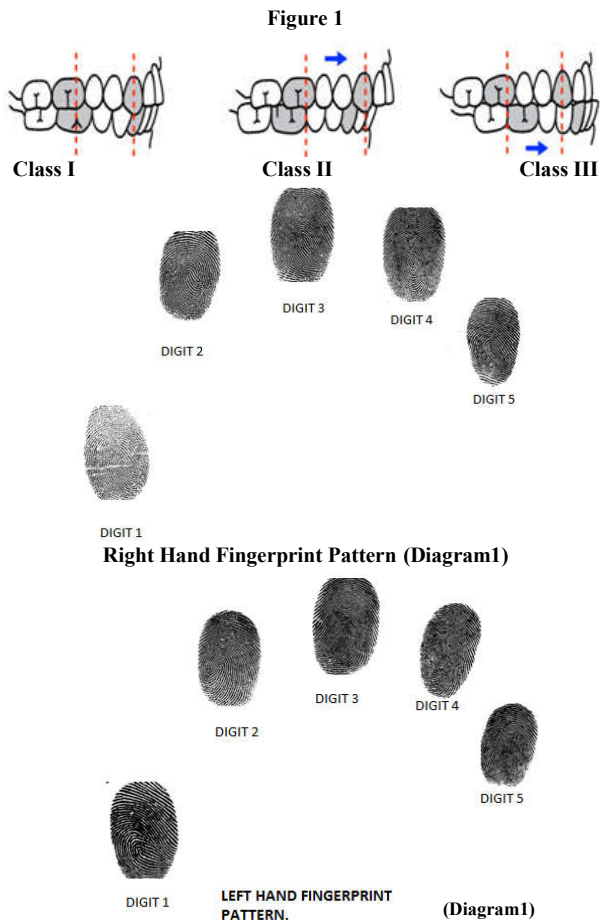
The relation of fingerprints was studied with the molar relation recorded using the study models.

## RESULT

TABLE 1: Percentage frequency distribution of different type of pattern- Arch, radial loop, ulnar loops and whorl of ideal occlusion, Class I and Class II malocclusion on right and left hand separately.(diagram 1 and 2)



Finger tip dermatoglyphic patterns figure 1



**Table 1** Percentage frequency distribution of different type of pattern- Arch, radial loop, ulnar loops and whorl of ideal occlusion, Class I and Class II malocclusion on right and left hand separately.

Type of pattern	Hand	Arch			Radial Loop			Ulnar Loop			Whorl		
		I	II	Ideal	I	II	Ideal	I	II	Ideal	I	II	Ideal
Digit I	Right	2.86	1.43	0	0	0	0	28.57	11.43	21.43	11.43	5.71	0
	Left	2.86	1.43	0	1.43	0	2.86	22.86	10.00	20.00	10.00	5.71	0
Digit II	Right	8.57	1.43	2.86	5.71	0	2.86	25.71	5.71	15.71	11.43	14.29	2.86
	Left	15.71	2.86	1.43	2.86	0	2.86	18.57	8.57	15.71	14.29	10.00	1.43
Digit III	Right	7.14	0	1.43	1.43	0	0	37.14	14.29	15.71	5.71	8.57	7.14
	Left	12.86	0	0	0	1.43	0	28.57	8.57	17.14	10.00	12.86	7.14
Digit IV	Right	2.86	0	0	1.43	1.43	0	21.43	4.29	12.86	25.71	17.14	11.43
	Left	1.43	0	0	0	0	0	28.57	1.43	21.43	20.00	21.43	2.86
Digit V	Right	2.86	0	0	1.43	0	0	35.71	12.86	20.00	10.00	10.00	4.29
	Left	4.29	0	0	2.86	0	0	34.29	14.29	18.57	10.00	7.14	5.71

**Table 2** Distribution of dermatoglyphic patterns in each class of occlusion.

Types of finger tip patterns	Type Of Malocclusion		
	Ideal Occlusion	Class I Malocclusion	Class II Malocclusion
Number of loops	125 (73.3%)	197(53.24%)	64(40.00%)
Number of whorl	30(17.64%)	90(24.33%)	79(49.38)
Number of arches	4(2.36%)	43(11.62%)	5(3.12%)

The percentage frequency of occurrence of fingertip patterns was noted separately for right and left hands and finally combined scores for each of these were recorded. Comparison of fingerprint pattern with the type of occlusion was done. It was seen that ulnar loop fingertip pattern was common in children with ideal occlusion with a percentage frequency of 73.3%. Whorl fingertip pattern was common in children with class II malocclusion with a percentage frequency of 49.38%. (Table 2)



## DISCUSSION

Dermatoglyphics (Cummins and Midlo, 1926)<sup>3</sup> refers to the epidermal ridge configuration of the hands and feet. Dermatoglyphic morphogenesis of both hand and feet begins at 4-5 weeks of gestation by initiation of volar pad formation. Migration of neural crest cells starts at 35<sup>th</sup> day after gestation and their proper migration along the cleavage plane is necessary for proper dermatoglyphic development<sup>12</sup>. Proper distribution of capillary-neurite pair under dermis is also a requisite for pattern development. The key figure in the development of dermatoglyphic study was done by Czech doctor Jan Purkinje. He suggested that the dermatoglyphic patterns might have both genetic and diagnostic importance. Towards the end of the 19<sup>th</sup> century, Galton put forth a rule called 'proof of no change', which states that an individual's dermatoglyphics remain unchanged throughout his/her lifetime. Since it is unique for each person, and is not same even in monozygotic twins, studying them can determine a number of parameters which could be helpful in diagnosing and treatment of examined individuals. Thus, it is considered to be an important tool in assessing the genetic trait, evaluation of children with suspected genetic disorders and also in forensics. It is noted that subjects with chromosomal abnormalities had unusual ridge formations. The ridges are influenced by blood vessel-nerve pairs at the border between the dermis and epidermis during prenatal development and factors, such as inadequate oxygen supply, unusual distribution of sweat glands and alterations of epithelial growths could influence the ridge patterns. The development of occlusion is a result of the interaction and synergistic effects of genetic and environmental factors. The effect of a particular environmental factor on phenotype varies depending on genetic background, which ultimately determines facial and dental morphology (Mossey, 1999)<sup>9</sup>.

Malocclusion may be defined as a significant deviation from what is defined as normal or ideal occlusion (Andrews 1972). Many components are involved in normal occlusion. The most important are –

1. The of the maxilla
2. The size of mandible, both ramus and body
3. The factors which determine the relationship the two skeletal bases, such as cranial base and environmental factors.
4. The size and morphology of tooth
5. The number of teeth present
6. Soft tissue morphology

According to the functional matrix theory of Moss and Salentijn (1969)<sup>8</sup>, genetic information is located in the neurological, muscular, and neuromuscular fields, which indirectly influence the skeleton. Mastication, facial expression, speech, and swallowing are examples of neuromuscular patterns. The functional matrix is believed to encompass neuromuscular activity, which is influenced by genetics as well as environmentally influenced behavioral and postural adaptations. A proper understanding of dermatoglyphics and dental structures in man can be obtained with knowledge on their phylogenetic and odontogenic histories. . The epidermal ridges of the fingers and palm and the facial structures originate from the same embryonic tissue

i.e. ectoderm. Dermal ridges and craniofacial structures are both formed during second trimester of IU life ,in around 6-8 weeks .Thus, the face and the dermatoglyphic pattern not only have same origins, but also develop concurrently; the genetic message contained in the genome is deciphered during this period and is also reflected in dermatoglyphic patterns.

In the present study it was seen that ulnar loop fingertip pattern was common in children with ideal occlusion with a percentage frequency of 73.3%. Whorl fingertip pattern was common in children with class II malocclusion with a percentage frequency of 49.38%. Few authors {Reddy *et al.*<sup>11</sup> (1997), Trehan *et al.*<sup>14</sup> (2001) and Tikare *et al.*<sup>13</sup>(2010)} have investigated associations of dermatoglyphic features with malocclusion. Reddy BRM *et al* in his study found significant increase in whorls in patients with Class II div 1 malocclusion. Rajput *et al* conducted a study and concluded whorls were more frequent in class I malocclusion subjects and loops were more frequent in class II and malocclusion subjects ,this variation in result may be attributed to the fact that the sample size was small i.e 24 subjects with malocclusion. In a study on 237 subjects, Jindal *et al*<sup>5</sup> (2014) observed an increased tendency towards high frequency of whorls in subjects with Class II Malocclusion. Tikare *et al* (2010) conducted a study and found that whorl pattern was commonly associated with class II malocclusion. Reddy *et al*<sup>10</sup>(2013) reported that dermatoglyphics can be a predictor of malocclusion in his study on 196 found increased frequency of ulnar loops in ideal occlusion cases i.e 85%. Similar results was seen in the present study. In the present study ulnar loops was a common pattern in ideal occlusion and whorl was a common finding in Class II malocclusion. The present study was performed in North Indian subjects; the associations examined here should be investigated further in samples with diverse demographic and ethnic characteristics and with specific DNA analysis. Prospective studies would be valuable for the establishment of dermatoglyphic markers of malocclusion. Determination of the genetic and environmental origin of malocclusion is important for orthodontic treatment planning and selection of appropriate treatment modalities. Establishment of the genetic component of malocclusion and individual susceptibility to this condition early in life could aid the planning of preventive and interceptive procedures. Dermatoglyphics, in turn, can be immensely helpful for the easy, accessible, noninvasive and economical identification of groups at high risk of developing malocclusion and for timely prevention, especially in developing countries with enormous populations and limited health budgets. However this is a pilot study conducted on a smaller sample further investigations on a larger sample may be required to substantiate the findings presented herein.

## Bibliography

1. Angle EH. Classification of malocclusion. Dent. Cosmos.1899; 4:248–64.
2. Babler WJ. Embryologic development of epidermal ridges and their configurations. Birth Defects. Orig. Artic. Ser.1991; 27 (2): 95–112.
3. Cummins H. Dermatoglyphic stigmata in mongoloid imbeciles. Anat. Rec.1939; 73:407–415.
4. Galton F Sir. Finger Prints. Da Capo Press, New York;1965.p 67-9

5. Jindal G, Pandey RK, Gupta S, Sandhu M. A comparative evaluation of dermatoglyphics in different classes of malocclusion. *The Saudi Dental Journal* 2015; 27:88-92.
6. Kumar G. Orban's Oral Histology and Embryology, 12<sup>th</sup> ed. Reed Elsevier India Private Limited, New Delhi; 2008.p 89-94
7. Mathew L, Hegde AM, Rai K,. Dermatoglyphic peculiarities in children with oral clefts. *J. Indian Soc. Pedod. Prev. Dent.* 2005; 23:179–182.
8. Moss ML, Salentijn L. The primary role of functional matrices in facial growth. *Am. J. Orthod.* 1969; 55:566–75.
9. Mossey PA. The heritability of malocclusion: part 2. The influence of genetics in malocclusion. *Br. J. Orthod.* 1999; 26 (3): 195–03.
10. Reddy BR, Sankar SG, Roy ET, Govulla SA. Comparative study of dermatoglyphics in individuals with normal occlusions and malocclusions. *J Clin Diagn Res* 2013; 7(12):3060-65.
11. Reddy S, Prabhakar AR, Reddy VV. A dermatoglyphic predictive and comparative study of Class I, Class II, div. 1, div.2 and Class III malocclusions. *J Indian Soc Pedod Prev Dent.* 1997 Mar; 15(1):13-19.
12. Sengupta AB, Bazmi BA, Sarkar S, Kar S, Ghosh C, Mubtasum H. A cross sectional study of dermatoglyphics and dental caries in Bengalee children. *J Indian Soc Pedod Prev Dent.* 2013 Oct; 31(4):245-48.
13. Tikare S, Rajesh G, Prasad KW, Thippeswamy V, Javali SB. Dermatoglyphics—a marker for malocclusion? *Int Dent J.* 2010 Aug; 60(4):300-04.
14. Trehan M, Kapoor DN, Tandon P *et al.* Dermatoglyphic study of normal occlusion and malocclusion. *J Ind Orthod Soc* 2000; 34: 114-25.
15. Verbov J. Clinical significance and genetics of epidermal ridges-a review of dermatoglyphics. *J. Invest. Dermatol.* 1970; 54: 261–71.

\*\*\*\*\*

**How to cite this article:**

Jaskiran Kaur, Vijender Khokhar and Anuradha pathak.2016, Dermatoglyphics-As A Diagnostic Tool In Detection of Malocclusion. *Int J Recent Sci Res.* 7(7), pp. 12400-12404.