ISSN: 0976-3031

Available Online at http://www.recentscientific.com

International Journal of Recent Scientific Research
Vol. 7, Issue, 12, pp. 14755-14760, December, 2016

International Journal of Recent Scientific Research

Review Article

ZYGOMATIC IMPLANTS IN MAXILLOFACIAL REHABILITATION – A CRITICAL REVIEW

Aziz Pahadwala*., Padmasree Patowary., Sanyukta Raut., Santhosh Kumar SN., Kalyani Bhate and Manju Singh

Department of Oral and Maxillofacial Surgery. Dr. D. Y. Patil Dental College and Hospital, Pimpri, Pune- 411018

ARTICLE INFO

Article History:

Received 17th September, 2016
Received in revised form 21st October, 2016
Accepted 05th November, 2016
Published online 28th December, 2016

Key Words:

Zygomatic implant, atrophic maxilla, graftless solution, edentulous maxilla, maxillectomy defect.

ABSTRACT

Dental implants have been ray of hope in dental rehabilitation for last four decades. However, due to anatomical factors, implants in maxilla is always more complicated than mandible. The situation becomes undesirable when the maxilla is severely resorbed and atrophic, so various protocols such as sinus augmentation & hipbone grafts have been recommended to provide an optimal solution for this complex problem. A new implant technology was developed in 1998 to rehabilitate the upper jaw without using the bone graft. This "graft-less technique", also called the "Zygoma technique" using the cheekbone (zygoma bone) to anchor the longer zygoma implants known as zygomatic implants was developed by Branemark as an alternative to atrophic maxilla.

INTRODUCTION

The replacement of soft tissue and hard tissue is essential to rehabilitate and improve function and esthetic of orofacial region. The entire scope of replacement therapy has progressed originally from tooth replacement to surgically oriented implant reconstruction to the current and more correct prosthetically driven approach to this sophisticated arena of rehabilitation of the somatognathic system (Mish CE).

Dental implants are commonly used for replacing missing teeth, in spite of anatomical factors limiting the placement of implants in maxilla or mandible. With a high predictability for some systems, increased applications have been developed for compromised patients. Also, conventional implants have always been sensitive in the maxilla than in the mandible (Baig MR *et al*., 2012). The situation becomes undesirable when the maxilla is severely resorbed and atrophic or in cases of post-maxillectomy defects. Therefore, various protocols have been recommended to provide an optimal solution for this complex problem.

Zygomatic implants, specialized long implants, are especially suitable for patients with advanced atrophy of the maxilla and who refuse or have suffered a complication after bone grafting procedures. The high survival rates (higher than 90 %) and the low incidence of complications reported in the reviewed papers, make zygomatic implants a good treatment option for the rehabilitation of severely resorbed maxilla (Cotter E, 2011).

Historical Perspective

Zygoma implants were first introduced in 1998 by Per Ingvar Branemark widely acknowledged as the "*Father of Dental Implantology*" (Kato *et al* 2005).

After Branemark, Malevez *et al* described zygomatic implants as self-tapping screws in commercially pure titanium with a well-defined machined surface. They are available in 8 different lengths, ranging from 30 to 52.5 mm. They present a unique 45 degree angulated head to compensate for the angulation between the zygoma and the maxilla. Traditionally, these implants had a palatal emergence, crossed the maxillary sinus and were anchored in the zygomatic bone. Nowadays, the palatal emergence can be avoided by using the "extramaxillary" implants technique, where the zygomatic implant goes through the lateral wall of the maxillary sinus (Malevez *et al* 2000).

At the moment three companies are selling threaded titanium zygomatic implants:

1. Nobel Biocare AB (Göteborg, Sweden) the Zygoma Implant.

*Corresponding author: **Aziz Pahadwala***
Department of Oral and Maxillofacial Surgery. Dr. D. Y. Patil Dental College and Hospital, Pimpri, Pune- 411018

2. Brånemark Integration AB (Göteborg, Sweden) the Z Fixture.
3. Southern Implants (Irene, South Africa) the Zygomatic Implant, a similar design to the Nobel Biocare implant.

Surgical Anatomy of Zygomatic Bone

The zygomatic bone could be compared to a pyramid, offering a solid anatomic structure for implant anchorage. A histological analysis of this area revealed the presence of a regular and dense bone with very high osseous density (up to 98 %). Due to these features, the zygomatic bone has already been used to place miniplates as a part of the orthodontic treatment. When occlusal forces are applied to the implant fixture, the load is transferred to the trabecular and cortical bone. According to an anatomical study, the mean length of useful bone in this region is 14 mm (Candel E *et al*., 2012).

Micro-computerized tomography (CT) analysis of zygomatic bone revealed that the greatest thickness/density of trabecular bone was found in the *jugale* region, which is the most concave point between the lateral margin of the upper zygomatic bone and the upper margin of the zygomatic arch. It was revealed that bone density in this region does not decrease as it does in other regions following loss of teeth because of the insertion of masseter muscles, which provide adequate stress to continue successful osteoblastic activation and bone turnover. Thus, adequate thickness of zygomatic bone is sufficient to provide anchorage and then load bearing for a zygomatic implant (Kato *et al*., 2005).

Figure no 1 Front view of zygoma

Figure no 2 Worm's eye view of zygoma

Figure no 3 Side view of zygoma

Indications And Contraindications For Zygomatic Implants

The indications and contraindications of zygomatic implants are enlisted in table no. 1 & 2 respectively.

Table No 1 Indications For Zygomatic Implants

Sr. No.	Indications
1.	Treatment of severely atrophic edentulous maxilla.
2.	Free-end situations in maxilla with insufficient bone height. Maxillary reconstruction after partial or total maxillectomy.
3.	Zygomatic implants can be used to fix maxillary obturators as an alternative to non-implant retained obturators, local and regional flaps, and microvascular free flaps.
4.	Patients with systemic pathology causing severe maxillary atrophy such as cleft palate or epidermolysis bullosa.

Table No -2 Contraindications For Zygomatic Implants

Sr. No.	Contraindications
1.	Acute sinusitis.
2.	Zygoma pathology.
3.	Adequate maxillary bone for conventional implants (relative contraindication).
4.	Medically compromised patient such as, metabolic disorders, or uncontrolled diseases (relative contraindication).
5.	Chronic infectious sinusitis (relative contraindication).
6.	Patients on bisphosphonate therapy (relative contraindication).
7.	Chronic smokers, smoking more than 20 cigarettes a day (relative contraindication).
8.	Severe trismus (relative contraindication).
9.	Previous history of head and neck radiation therapy (relative contraindication).

Advantages and Disadvantages of Zygomatic Implants

Like any other techniques, even zygomatic implants have advantages and disadvantages, which are enumerated in table no. 3 & 4.

Table NO- 3 Advantages of Zygomatic Implants

Sr. No.	Advantages
1.	Avoids use of grafts in atrophic maxilla.
2.	No additional donor site surgery and morbidity.
3.	Zygomatic implants placed with two to four traditional premaxillary implants can be either immediately loaded, or more traditionally, a final fixed prosthesis can be placed after a 6- month healing period.
4.	Good anchorage from tough zygomatic bone which enhances stability of prosthesis.
5.	Zygomatic implants do not necessarily require hospitalization, which is usually needed for autogenous bone harvesting from the iliac crest.
6.	The total treatment time is routinely 6 months or less for zygomatic implants compared with grafting with subsequent implant placement.
7.	Less number of patient visits.
8.	Fewer implants are required to support a prosthesis compared with traditional bone grafting and implant placement.
9.	The overall laboratory fees are equal to or slightly less than those for traditional implants.

Table No-4 Disadvantages of Zygomatic Implants

Sr. No.	Disadvantages
1.	Difficulty in implant placement and the palatal emergence profile.
2.	Because the platform of the zygomatic implant might be palatal to the crest, the perception is that the patient will feel excess bulk and have problems with the prosthesis. The restorative dentist must have the clinical proficiency to fabricate a full arch implant supported prosthesis, which could exclude dentists who do not have the clinical experience with this type of prosthesis.
3.	The placement of the zygomatic implant is limited by the anatomy of the zygoma.
4.	In patients with concave lateral walls of the maxilla, surgical placement of the zygomatic implant within the bone might be difficult. The surgical access to the zygoma and orbital rim requires a surgeon who has experience with surgery in this area.
5.	Although the palatal emergence of the implant does add to the difficulty of maintaining oral hygiene, minimal long-term phonetic sequelae from the prosthesis design have been reported.
6.	The surgeon must attain training for surgical placement of zygomatic implant.

Classification

Aparicio C in 2011 proposed a classification for zygomatic implant patients based on the zygoma anatomy guided approach (ZAGA). The morphology of the lateral sinus wall, residual alveolar crest and the zygomatic buttress was taken into major concern. The five basic anatomical groups were named as ZAGA 0, ZAGA 1, ZAGA 2, ZAGA 3 & ZAGA 4 (Aparicio C *et al*., 2011).

Presurgical Evaluation

Inserting implants from the maxillary level through the sinus and up to the zygoma is a challenging venture. Three levels have to be investigated: the maxillary level, the sinus and the zygoma. Clinical examination is not sufficient for this evaluation and radiologic assessment has to be considered.

Table NO 5 Anatomical Types For Zygomatic Implant Patients

Classification	Description	Inference	Schematic diagram
ZAGA O	The anterior maxillary wall is very flat.	The implant body has an intra-sinus path.	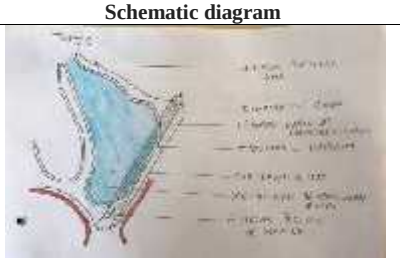
ZAGA 1	The anterior maxillary wall is slightly concave.	The implant can be seen through the wall, most of the implant body has an intra-sinus path.	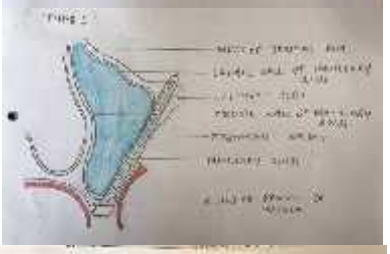
ZAGA 2	The anterior maxillary wall is concave.	The implant can be seen through the wall and most of the body has an extra-sinus path.	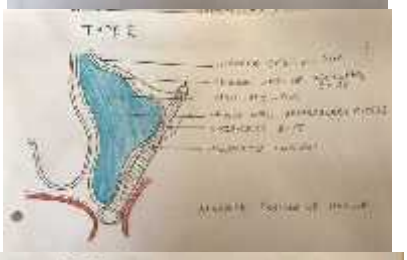
ZAGA 3	The anterior maxillary wall is very concave.	Most of the implant body has an anterior extra-sinus path.	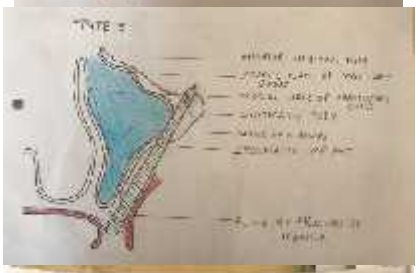
ZAGA 4	The maxilla and the alveolar bone show extreme vertical and horizontal atrophy.	Most of the implant body has an extra-sinus/extra-maxillary path. Just the apical part of the implant is surrounded by bone.	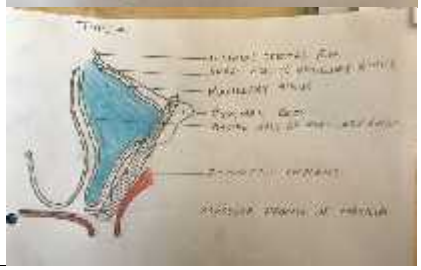

The OPG can give distorted information and therefore, the examination of choice is computed tomography (CT) scan, which makes two- and three-dimensional imaging possible. Bothur *et al* published a technical note on a modified technique for zygomatic implant placement in 2003 in which, they said that preoperative considerations should involve shape of the face, degree of resorption, sinus status, maxillomandibular jaw relationship, and patient expectations (Bothur *et al*., 2003).

The CT scan also gives the opportunity to visualize the health of the maxilla and the sinus. Sinusitis, polyps or any sinusal pathology can be excluded. The density, length and volume of the zygoma can be evaluated and special templates for inserting the zygomatic implants can be constructed on stereolithographic models to facilitate the orientation of the zygomatic implants during the surgery with minimal errors in angulation and position (van Steenberghe D *et al*., 2003).

Armamentarium

Brånemark System Zygoma TiUnite Implants Regular Platform (RP)

Zygoma implants: RP machined
Implants: 30, 35, 40, 45, 50, 52.5 mm
Zygoma healing abutments (40-degree angle, 3-mm diameter; 40-degree angle, 5-mm diameter)
Multiunit abutments RP
Multiunit: 3, 15 mm
17-degree angle, multiunit: 2 and 3 mm
Zygoma drills
Round bur
Twist drill: 2.9 mm
Twist drill: 2.9 mm short
Pilot drill: 3.5 mm
Pilot drill: 3.5 mm short
Twist drill: 3.5 mm
Twist drill: 3.5 mm short
Zygoma instruments
Zygoma surgical kit
Z handle, Z drill guard,
Z drill guard short, Z depth indicator straight,
Z depth indicator angled.
Cover screwdriver: Brånemark System hexagon
Screwdriver: machine Unigrip 25 mm (to implant mount screw)
Screwdriver: manual Unigrip 28 mm (to implant mount screw)
Zygoma handpiece (to be used with OsseoSet 100) (semistraight ratio 20:1)
Connection to the handpiece
Motor: OsseoSet 100 handpiece
Drill: Zygoma 20:1
Surgical drill guide: NobelGuide (If the NobelGuide is used, the guided surgery kit for the Zygoma implants must be used.)
Forceps: Gerald (toothed)
Hemostats: long, curved (i.e., tonsillar)
Hemostats: mosquito
Impression material and adhesive: Impregum PVS
Needles: hypodermic 20 gauge, 1½-inch
Pliers: crimping
Retractors: beaver tails (Henahan), Army-Navy
Scissors: Mayo
Scalpel: long handle
Suture: 2-0 black silk
Suture: 4-0 dyed Vicryl
Tissue conditioner: Coe-Comfort, Viscogel

Figure no 4 Zygomatic kit

Surgical Procedure

Intrasinus technique

The classical approach was first introduced by Brånemark in 1998. General anaesthesia in conjunction with the administration of a local anaesthesia is the traditional recommendation for the management of patient undergoing zygomatic implants placement. More recently, some authors have also used intravenous conscious sedation techniques for the same purpose. Blocks of the alveolar superior nerves, infraorbitary nerves, and palatal nerves are required.

Figure no 5 Frontal view intra-sinus technique.

Figure no 6 Worm's eye view of intra-sinus technique showing palatal emergence.

A buccal approach using the traditional Le Fort I incision, can be made between the first molar regions. Another option is to perform a crestal incision allowing improved palatal access for implant placement. After raising the mucoperiosteal flap, soft tissue dissection has to be extended along the inferior and frontal lateral surfaces of the zygomatic bone, with identification of the infraorbital foramen. Special care has to be taken to avoid invasion of the orbit or sectioning the insertion of the masseter muscles in excess, as important bleeding could occur.

The palatal mucosa has then to be detached, especially in the zone of the second premolar/first molar. Afterwards, a 10 x 5 mm infrazygomatic window in the lateral wall of the maxillary sinus should be created to keep the Schneiderian membrane intact. This window should allow the observation of the drilling sequence as well as the implant placement. Branemark *et al* recommend placing gauze soaked in adrenaline inside the sinus for a few minutes to prevent bleeding and deter mucosal tissue from blocking the view (Candel E *et al*., 2012).

Technique modifications

The main disadvantage of this technique is related to the palatal emergence of the implants that complicates the design of the prosthesis, reduces the patient's ability to speak and compromises the long-term health of the peri-implant tissues due to the difficulty that patients have to clean this area. Secondly, due to the intrasinusal path of the implants the risk of sinus pathology development must be considered. Recently, some authors have proposed modifications of the classical technique described before (Aghabeigi B *et al*., 2007).

Extramaxillary implants

The extramaxillary approach was first introduced by Migliorança *et al*. in 2006 and is also called of "exteriorized implants" or "extrasinus zygomatic implants" Basically, it consists of a modification of the implant entrance in the alveolar process and its trajectory up to the zygomatic bone. In this technique, the implant emergence is located just in the middle of the alveolar process, hence correcting the palatal entrance of the Branemark technique (Migliorança *et al*., 2006). In its trajectory to the zygomatic bone, the fixture goes through the lateral sinus wall keeping the Schneiderian membrane intact. This technique not only improves the design of the prosthesis but also seems to reduce the incidence of sinusitis. Malo *et al* and Aparicio *et al* have already published some reports with excellent results (98.5–100 % survival rates). On the other hand, the main complaint would be the fact that the middle part of the implant rests in direct contact with the soft tissue of the cheek (Candel E *et al*., 2012).

Zygomatic implants without anterior standard implants

Frequently, the high degree of maxillary atrophy of these patients forces the surgeon to perform bone grafting techniques in the anterior area of the maxilla in order to place four standard implants. A modification first described by Bothur *et al* recommended the placement of four to six zygomatic implants in order to avoid the need of anterior fixtures and therefore to reduce the necessity of bone grafting in this area. In a study with 40 edentulous skulls, with atrophic alveolar processes and premaxillas, Rossi *et al* measured the distances between the alveolar process emergence at the canine region and the premolar/molar region to the zygomatic bone. The authors stressed the fact that the mean length of distance between the canine regions to the zygomatic bone was 53.42 mm and the maximum distance was 61.94 mm. Given that the longest commercially available implant is 52.5 mm, the authors emphasize the importance of a precise presurgical evaluation of the available distance when the placement of four zygomatic implants is planned.

Sinus-slot technique

Stella and Warner described this method in 2000. Mainly, the "slot technique" is a reduction of the sinus wall perforation doing a slot instead of a window. Likewise, this modification permits a good control of the drilling direction and insertion of the zygomatic fixture. Furthermore, according to the authors a higher amount of bone is preserved and also the flap size can be reduced, improving the patients' postoperative recovery. Peñarrocha *et al* published in 2007 a series of 21 cases with the "Slot technique" with a 100% survival rate, but the Schneiderian membrane was perforated in all cases, even though the incidence of sinus pathology was low (two cases) (Peñarrocha *et al*., 2007).

Immediate loading

Traditionally, the zygomatic implant loading protocol has been a two-stage approach. Nowadays, just a few numbers of authors have published results with an immediate loading protocol. To our knowledge, the first case-series was published in 2006 by Bedrossian *et al*. The review included a total of 28 zygomatic implants and 55 standard implants that were loaded immediately after surgery. The authors reported very good results with a survival rate of 100% and without any complications. Other recent studies have also reported similar findings with survival rates ranging from 95.8 % to 100%

Complications of Zygomatic Implants

1. The reported complications associated with zygomatic implants include postoperative sinusitis, oroantral fistula formation, periorbital and subconjunctival hematoma or oedema, lip lacerations, pain, facial oedema, temporary paraesthesia, epistaxis, gingival inflammation and orbital penetration/injury.
2. Post-operative concerns regarding difficulty with speech articulation and hygiene caused by the palatal emergence of the zygomatic implant and its effect on the prosthesis suprastructure.
3. The zygomatic implant prosthesis system is complex from the biologic point of view as a result of the interfaces towards different tissues such as bone, oral mucosa and sinus mucosa.
4. Zygomatic implants were associated with peri-implant bleeding and increased probing depths, possibly caused by difficulties in implementing appropriate hygiene because of the positioning of the zygomatic implant head and abutment, and the design of the prosthesis. Thus, the risk of soft tissue problems and sinusitis should not be underestimated.

DISCUSSION

The insufficient bone volume in posterior maxilla can be due to bone resorption as well as to pneumatisation of the sinus or to a

combination of both. In any case, insertion of implants in this region remains extremely unpredictable. Treatment with zygomatic implants was introduced for the rehabilitation of atrophic maxillae without the use of grafts. Zygomatic implants are long screw shaped titanium endosteal implants ranging in length from 30 mm to 52.5 mm & inserted through the posterior alveolar crest passing through or externally to the maxillary sinus to engage the body of zygomatic bone. A couple of conventional dental implants may also be needed in the frontal region of the maxilla to stabilise the prosthesis (Balshi TJ *et al*., 2000). The potential main advantages of zygomatic implants could be that bone grafting may not be needed and a fixed prosthesis could be fitted sooner. Another specific indication for zygomatic implants could be maxillary reconstruction after maxillectomy in cancer patients. The surgical procedure is carried out under general anaesthesia. Bilateral elevation of the buccal mucoperiosteal tissue is done after anaesthesia. Lateral sinus bony window is removed from its posterior aspect and antral mucosal lining is reflected. Two zygomatic implants are then inserted engaging the dense bone of the body of zygomatic arch, emerging intraorally in the upper premolar region just palatal to the alveolar crest. Each implant is introduced into the second premolar area, traversing the maxillary sinus, and is placed into the body of the zygomatic bone (Stella JP *et al*., 2000).

CONCLUSION

The zygomatic implant, the zygomaticus fixture appears to be a promising development in implant technology. It offers an interesting alternative solution to heavy bone grafting in the severely resorbed posterior maxilla. It has been in use for more than 10 years and gives a predictable outcome in the rehabilitation of totally as well as partially edentulous patients without the use of bone grafts from extragenous donor sites.

References

Aparicio C. A proposed classification for zygomatic implant patient based on the zygoma anatomy guided approach (ZAGA): A cross-sectional survey. *Eur J Oral Implantol*. 2011 Autumn; 4(3):269-75.

Aparicio C, Ouazzani W, Aparicio A, *et al*. Extrasinus zygomatic implants: A new surgical approach for patients with pronounced buccal concavities in the edentulous maxilla. Clin Implant Dent Relat Res. 2010; 12:55–61.

Aghabeigi B, Bousdras VA. Rehabilitation of severe maxillary atrophy with zygomatic implants. Clinical report of four cases. *Brit Dent J*. 2007; 202:669–75.

Baig MR, Rajan G, Yunus N. Zygomatic implant-retained fixed complete denture for an elderly patient. Gerodontol 2012 Jun; 29(2):1140-5.

Balshi TJ, Wolfinger GJ. Management of the posterior maxilla in the compromised patient: Historical, current, and future perspectives. Periodontol. 2000, 2003; 33:67-81.

Bothur S, Jonsson G, Sandahl L. Modified technique using multiple zygomatic implants in reconstruction of the atrophic maxilla: A technical note. *Int J Oral Maxillofac Implants*. 2003; 18:902–4.

Candel E, Peñarrocha D, Peñarrocha M. Rehabilitation of the atrophic posterior maxilla with pterygoid implants: A review. *J Oral Implantol* 2012; 38(S1):461–6.

Jude Sudhakar, Syed Ashraf Ali, Suma Karthikeyan. Zygomatic implants- A review. JIADS 2011; 2(2):24-8.

Kato, Yorihisa; Kizu, Yasuhiro; Tonogi, Morio (2005). "Internal Structure of Zygomatic Bone Related to Zygomatic Fixture". *J Oral Maxillofac Surg*. 63: 1325–1329.

Malevez C, Daelemans P, Adriaenssens P, Durdu F. Use of zygomatic implants to deal with resorbed posterior maxillae. Periodontol 2000. 2003; 33:82-9.

Mish CE: Contemporary Implant dentistry 2nd Ed. Indiana University, Mosby Elsevier, 2008.

Penarrocha M, García B, Martí E, Boronat A. Rehabilitation of severely atrophic maxillae with fixed implant-supported prostheses using zygomatic implants placed using the sinus slot technique: Clinical report on a series of 21 patients. *Int J Oral Maxillofac Implants*. 2007 Jul-Aug; 22(4):645-50.

Petruson B. Sinuscopy in patients with titanium implants in the nose and sinuses. *Scand J Plast Reconstr Surg Hand Surg*. 2004; 38:86–93.

Sharma A. Zygomatic implants/fixture: A systematic review. *J Oral Implantol*. 2013 Apr; 39(2):215-24.

Stella JP, Warner MR. Sinus slot technique for simplification and improved orientation of zygomaticus dental implants: A technical note. *Int J Oral Maxillofac Implants*. 2000 Nov-Dec; 15(6):889-93.

van Steenberghe D, Malevez C, Van Cleynenbreugel J, Bou Serhal C, Dhoore E, Schutyser F, Suetens P, Jacobs R. Accuracy of drilling guides for the transfer from 3-D CT based planning to placement of zygomatic implants in human cadavers. Clin Oral Implants Res 2003: 14: 131–136.

****

How to cite this article:

Aziz Pahadwala *et al*.2016, Zygomatic Implants in Maxillofacial Rehabilitation – A Critical Review. *Int J Recent Sci Res.* 7(12), pp. 14755-14760.