

**Case Report****Synovial hemangioma of the Hoffa's fat pad: a case report****\*Gotecha D S, Bhalerao N A, Arora K S**

Department of Orthopedics, PDVPF's Medical College, Ahmednagar, Maharashtra, India

**ARTICLE INFO****Article History:**Received 15<sup>th</sup> October, 2016  
Received in revised form 25<sup>th</sup>  
November, 2016  
Accepted 23<sup>rd</sup> December, 2016  
Published online 28<sup>th</sup> January, 2017**ABSTRACT**

Synovial hemangioma is a rare benign tumor, most commonly arising from the knee joint. We report a case of a 19 years old female presenting with pain and swelling in the left knee joint. Plain radiography was inconclusive. Magnetic Resonance Imaging revealed the lesion arising from the Hoffa's fat pad, with hyperintensity on T2-weighted images. Arthroscopic surgical excision was performed and histopathological examination proved the lesion to be a cavernous hemangioma.

**Key Words:**Arthroscopy, cavernous hemangioma,  
Hoffa's fat pad, knee pain.

**Copyright © Gotecha D S, Bhalerao N A, Arora K S., 2017**, this is an open-access article distributed under the terms of the Creative Commons Attribution License, which permits unrestricted use, distribution and reproduction in any medium, provided the original work is properly cited.

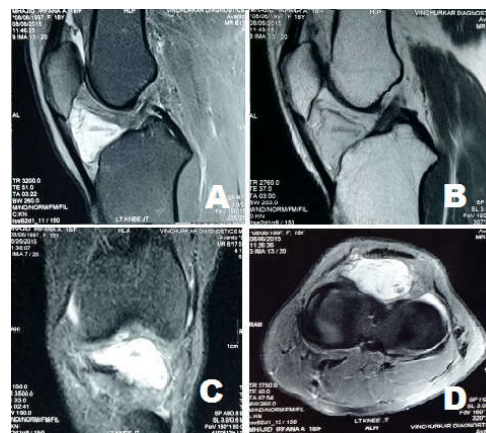
**INTRODUCTION**

Synovial hemangiomas are rare lesions arising from synovium lined surfaces, typically occurring in young adults (Ramsier *et al*, 2004). It presents with pain, tenderness, restriction of movements, soft tissue swelling and effusion without any history of trauma. As its clinical features are non-specific, it is difficult to diagnose and often leads to delay in treatment. Although the knee joint is the most commonly involved joint, its origin from the Hoffa's fat pad is rare; very few cases have been reported in literature (Peterson *et al*, 1999). There is not much mention of arthroscopic treatment of such lesions. We report a case of an infrapatellar hemangioma arising from the Hoffa's fat pad in an adult female treated arthroscopically, with satisfactory results obtained through post operative follow up evaluation.

**Case Report**

A 19 year old female presented to the out-patient department with complaints of intermittent left knee pain and swelling below the patella since 9 months. The range of movement was 0° to 110°. She gave no history of trauma or massage to the knee. Her past history was negative for any local/systemic diseases. On examination, there was fullness of the knee joint with a small cystic swelling present around the inferior pole of the patella. There was no ligamentous laxity. McMurray's test was possible for a medial meniscus tear. MRI of the patient revealed an approximately 2.2 x 3.6 x 3.3 cm size well defined lobulated lesion seen in the infrapatellar region involving

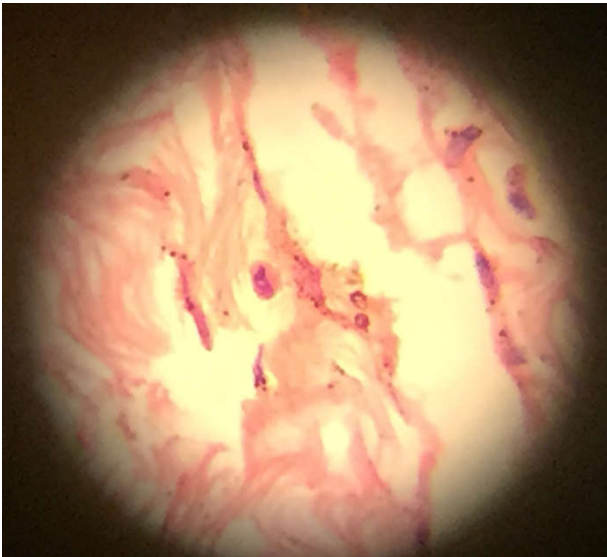Hoffa's fat pad, showing few thin septae and tiny hypointensities within (Figure 1). A diagnostic arthroscopy of the knee was performed, which revealed a round reddish tumor within the infrapatellar fat pad. Anteriorly the lesion was abutting the inner cortex of inferior pole of patella. Posteriorly it was abutting the anterior horns of the medial and lateral menisci and the tibial attachment site of the anterior cruciate ligament. Excision of the hemangioma was performed arthroscopically and the mass was sent for histopathological examination. Histopathology report revealed vascular proliferation with irregularly dilated and congested blood vessels with blood within stroma in fibrofatty tissue, consistent with cavernous hemangioma (Figure 2)



**Figure 1** MRI images delineating the lesion in the Hoffa's fat pad. 1A- T2 Sagittal, 1B- T1 Sagittal, 1C- T2 Coronal, 1D- T2 Axial

\*Corresponding author: **Gotecha, D S**

Department of Orthopedics, PDVPF's Medical College, Ahmednagar, Maharashtra, India



**Figure 2** Histopathological section, stained with hematoxylin and eosin, showing blood vessels within stroma in fibrofatty tissue, suggestive of cavernous hemangioma.

## DISCUSSION

Synovial hemangiomas were first described by Bouchut in 1856 (Bouchut *et al*, 1856). They are defined as a benign vascular lesion arising from any structure lined by synovium including the intra-articular region, bursal spaces and tendon sheaths. They are usually diagnosed in the first to third decade of life with a slight predilection to females as compared to males (Enzinger *et al*, 1988).

Based on the anatomic location, synovial hemangiomas can be divided into intra-articular, which are situated inside the joint capsule; juxta-articular, which are situated outside the joint capsule; and intermediate, which are intra-articular as well as extra-articular (DePalma *et al*, 1964). In 1939, Bennett and Cobey classified synovial hemangiomas morphologically into diffuse and circumscribed types; the diffuse type usually consisted of a cavernous hemangioma with typical intermittent pain and swelling of the joint, whereas circumscribed hemangiomas were a pedunculated synovial tumor of the capillary type (Bennett *et al*, 1939). Histologically, Stout classified synovial hemangiomas into four main categories: cavernous, capillary, mixed cavernous-capillary and venous. Out of all, cavernous hemangioma was most common, followed by capillary, mixed and venous (Stout *et al*, 1943).

Synovial hemangiomas usually present with nontraumatic joint swelling combined with pain and restriction of movements. Symptoms usually persist for a long duration before accurate diagnosis is achieved. The arthropathy is hypothesized to be caused by repeated bleeding episodes similar to joint disease in hemophilia (Devaney *et al*, 1993). The origin of such hemangiomas is still unknown. Holzapfel *et al* suggested that synovial hemangiomas are a reaction to trauma (Holzapfel *et al*, 2009). Moon supported this hypothesis and reported 35% of patients had history of trauma prior to development of the hemangiomas (Moon *et al*, 1973).

The tumor can be precisely located and morphologically characterized on MRI. In 1993, Shapiro and Fanton stated the

significance of adopting MRI in diagnosing the hemangioma in the joint. According to them, on T1-weighted images, the boundary of the hemangioma is not clear, showing the same intensity in the muscle and high signal in the area with low blood flow; on T2-weighted images, the boundary is clearer, with medium to high signal (Shapiro *et al*, 1993). Sasho reported the typical imaging features of hemangioma: an iso- or hypointense homogenous signal on T1-weighted images, a hyperintense signal on T2-weighted images and heterogenous enhancement after gadolinium enhancement (Sasho *et al*, 2011).

Different treatment modalities have been reported in literature for the treatment of synovial hemangiomas. Meislin, in 1990, was the first to perform arthroscopic exploration and excision of the hemangioma (Meislin *et al*, 1990). Arthroscopy, as a treatment method for excision of synovial hemangiomas has been performed by very few authors, and there is no ideal consensus over treatment of intra-articular hemangiomas. Akgun I *et al* reported a case series of 4 patients with arthroscopic management of 4 intra-articular hemangiomas (Barakat *et al*, 2007). Dunet *et al* reported the arthroscopic excision of a hemangioma located in the posterior compartment of the knee (Dunet *et al*, 2014). However, numerous authors have reported that excision by arthrotomy is preferable and provides more complete excision compared to arthroscopy.

## CONCLUSION

In conclusion, because of advances in arthroscopic instrumentation, we believe that arthroscopic excision is more justified to define and excise local intra-articular tumoral lesions. Also being minimally invasive, arthroscopy is more advantageous compared to an open approach. However, diffuse lesions may be difficult to define arthroscopically and may need open excision. Hence, decision regarding excision should be approached on a case-to-case basis.

### Conflict of interest

No potential conflict of interest relevant to this article was reported.

## References

- Ramsier LE, Exner GU. Arthropathy of the knee joint caused by synovial hemangioma. *J Pediatr Orthop* 2004; 24: 83-86
- Petersen W, Rafii M, Ellwanger S, Laprell H. Synovial hemangioma within Hoffa's fat pad as the cause of anterior knee pain. 2 cases within a family and review of literature. *Z Orthop Ihre Grenzgeb*. 1999; 137: 76-78
- Bouchut ME. Tumeur erectile de l'articulation du genou. *Gaz Hop Paris* 1856; 29: 379.
- Enzinger FM, Weiss SW. Benign tumors and tumor like lesions of blood vessels. In: *Soft tissue tumors*. 2nd edition. St. Louis: C. V. Mosby, 1988: 102-35.
- DePalma AF, Mauler GC. Hemangioma of synovial membrane. *Clin Orthop* 1964; 32: 93-99
- Bennet GE, Cobey MC. Hemangioma of joints: report of five cases. *Arch Surg* 1939; 38: 487-500
- Stout AP. Hemangioma-endothelioma: a tumor of blood vessels. *Ann Surg* 1943; 118: 445

- Devaney K, Vinh TN, Sweet DE. Synovial hemangioma: a report of 20 cases with differential diagnostic considerations. *Hum Pathol* 1993; 24: 737-745
- Holzappel BM, Geitner U, Diebold J, Glaser C, Jansson V, Durr HR. Synovial hemangioma of the knee joint with cystic invasion of the femur: a case report and review of literature. *Acta Orthop Trauma Surg* 2009; 129: 143-148
- Moon NF. Synovial hemangioma of the knee joint. Review of previously reported cases and inclusion of two new cases. *Clin Orthop Relat Res* 1973; 90: 183-190
- Shapiro GS, Fanton GS. Intra-articular hemangioma of the knee. *Arthroscopy*, 9; 464-466: 1993.
- Sasho T, Nakagawa K, Matsuki K, *et al.* Two cases of synovial haemangioma of the knee joint: Gd-enhanced image features on MRI and arthroscopic excision. *Knee* 2011; 18: 509-11.
- Meislin RJ, Parisien JS. Arthroscopic excision of synovial hemangioma of the knee. *Arthroscopy* 1990; 6: 64-7.
- Barakat MJ, Hirehal K, Hopkins JR, Gosal HS. Synovial hemangioma of the knee case report. *J Knee Surg* 2007; 127: 845-8.
- Dunet B, C. Tournier, J. Pallaro, F. Boulet, T. Fabre. Arthroscopic treatment of an intra-articular hemangioma in the posterior compartment of the knee. *Orthopedics & Traumatology: Surgery and Research* 2014; 100 (3): 337-339

\*\*\*\*\*

**How to cite this article:**

Gotecha D S, Bhalerao N A, Arora K S. 2017, Synovial hemangioma of the Hoffa's Fat Pad: A Case Report. *Int J Recent Sci Res.* 8(1), pp.15148-15150.