



ISSN: 0976-3031

Available Online at <http://www.recentscientific.com>

International Journal of Recent Scientific Research
Vol. 8, Issue, 2, pp. 15579-15582, February, 2017

**International Journal of
Recent Scientific
Research**

Research Article

DIAGNOSTIC EFFICACY OF PUFFED CHEEK CT COMPARED TO CONVENTIONAL CECT IN THE IMAGING OF LESIONS OF ORAL CAVITY

Virupaxappa, T.K., DheerajShyam, V.N., SubairNangarathMundachi
and Sowrabha, M.C

ARTICLE INFO

Article History:

Received 15th November, 2016
Received in revised form 25th
December, 2016
Accepted 28th January, 2017
Published online 28th February, 2017

Key Words:

Puffed cheek, Oral Cancer, Dynamic
Maneuvers

ABSTRACT

Various lesions of the oral cavity have always been a challenge to Radiologists., delineating the extent of a mass in the oral cavity can prove to be difficult owing to the close relation of adjacent mucosa. Very Small tumours of the oral cavity are not always visible on conventional CT studies. Even though Large tumours can be well made out on CT, it may not be always possible to determine the surface of origin of the tumour. Dynamic manoeuvres tend to distend the oral cavity and widen the window available for the radiologists.

Aims & Objectives: Determining the diagnostic efficacy of Dynamic Maneuvers in Computed Tomography in better delineation of Oral Cavity lesions as compared to conventional CT

Materials & Methods: 40 patients referred to Department of Radio-diagnosis, J.J.M Medical College Hospital; Davangere were selected for the study. These patients were mostly referred by the department of dental sciences for CT evaluation. The study was a hospital based prospective cross sectional study conducted over a period of of one year from june 2015-june 2016 Initially conventional CECT were performed which was later followed up with a dynamic manoeuvre .later the images obtained by both were compared and the results computed.

Results: Puffed cheek manoeuvre was highly useful in 73.3% of cases and was not much helpful in 26.7% in evaluation of oral lesions. Puffed Cheek CT has a sensitivity of 80% and a specificity of 28 % in accurately staging oral malignancies. Puffed cheek CT had a positive predictive value of 33.3% and a negative predictive value of 75% and an Accuracy rate of 51% compared to conventional CT in staging oral malignancies. The size of the lesion measured using puffed cheek CT technique correlates well with the actual size of the lesion seen during surgery. Thus Puffed Cheek CT scan is better than conventional CT scan for delineating the extend of the tumour and for accurate assessment of lesion size. Almost 77% of the cases included in the study were able to perform the puffed cheek maneuver with ease.

Conclusion: We were able to conclude from our study that Puffed-cheek CT scans provide a clearer and more detailed evaluation of mucosal surfaces of the oral cavity than do conventional images. While standard CT can be insufficient for tumour localisation, imaging during distension may contribute to a more exact localisation. In selected patients, like those with lesions of retromolar trigone, the puffed-cheek technique may serve as a worthy supplement to conventional CT in evaluation of bony invasion and proper delineation of tumour extend. Radiological staging using cross sectional imaging is far superior to clinical staging and in assessment of metastatic neck nodes.

Copyright © Virupaxappa, T.K *et al*, 2017, this is an open-access article distributed under the terms of the Creative Commons Attribution License, which permits unrestricted use, distribution and reproduction in any medium, provided the original work is properly cited.

INTRODUCTION

Need for study

Evaluation of oralcaity lesions is a challenging task for the radiologist. The apposition of the soft tissue structures in the oral cavity makes it difficult for the radiologist to delineate the extent of the tumour, the surface of origin and its relations.

Even though large bulky tumors can be appreciated easily, various extensions of the lesion through the soft tissue structures might be more difficult to evaluate. The difficulty increases with that of small oral cavity lesions which can be missed easily and requires a vigilant approach.

Clinical examination often understages the deep spread of oral cavity tumors. Computed tomography provides additional staging information that helps determine more precisely the exact local extension of a tumour.

*Corresponding author: *Virupaxappa, T.K*

Our study was to evaluate use of a simple technique which would add significant value to the conventional CT .It involves the use of dynamic maneuver where in patient is asked to hold a puffed cheek during the CECT procedure. This procedure provided a good air- soft tissue interface and helped in better evaluation of the lesions. Air acts as an excellent contrast medium and delineates the buccal mucosa from other soft tissue structures

The use of this simple procedure significantly changed the rate of detection of the lesion and also helped in better staging of the lesion. Another advantage of cheek distension is that the degree of expansion capacity in the presence of a lesion provides additional information about the cheek's rigidity secondary to infiltration.

Computed Tomography also complements Clinical examination by delineating deep extension of tumours and identifying metastatic cervical lymphadenopathy Bredesen et al reported that 53 of 54 patients in their series were able to perform cheek distension in accordance with a recorded voice instruction Before the start of the procedure due consent of the patient was taken and the procedure was explained to the the patients. before the procedure due practice was given to the patients. Patients were asked to suspend respiration for the duration of the maneuver, and all were able to comply. Bredesen et al reported that 53 of 54 patients in their series were able to perform cheek distension in accordance with a recorded voice instruction

Thus imaging plays a vital role in accurate pretreatment staging, formulating appropriate treatment strategies, post treatment surveillance and prognostication of oral cavity and oropharyngeal cancers. Inaccurate assessment of the extent or stage of disease may lead to unnecessary or incomplete surgical or radiation therapy, with a negative outcome

MATERIALS AND METHODS

Source of the Data

40 patients of the age group 25 to 85 years was included in the study. Subjects will be selected from patients coming to the following places for treatment.

- Department of ENT and General Surgery
- Patients referred by Department of Oral medicine and Radiology and maxillofacial surgery

Informed consent will be obtained from the subjects after explaining the risks and benefits of the procedure.

Methods of collection of data

Study Subjects

Patients with histologically proven diagnosis of various oral cavity lesions referred to Department of Radiology for Contrast Computer Tomography for staging of the disease process.

Inclusion Criteria

1. Patients must belong to the age group of 25 to 85.
2. Patients with clinical and histologically proven diagnosis of oral cavity lesions.

Exclusion Criteria

1. Patients who does not provide a valid consent for the procedure.
2. Pregnant woman are excluded from the study due to the risk of radiation hazard to the growing fetus.
3. Growing children with oral cavity lesions are excluded from the study.
4. Patients with prior neurological diseases like seventh nerve palsy and mentally retarded patients who are unable to perform the Valsalva's maneuver properly are excluded from the study.
5. Patients with chronic debilitating diseases or terminal cancer who are unable to perform the maneuver are exempted from the study.
6. Patients who have undergone previous extensive endodontic reconstructive procedures with dental amalgam are excluded from the study as the cause streak artifacts in CT images.
7. Patients with altered renal parameters are excluded from the study as intravenous contrast agent cannot me administered in such patients.

Study area: The study was conducted in the Radiology Department of a tertiary care medical college and hospital

Study period: The study period will be a period of two years from June 2015- June 2016.

Study design: Hospital based prospective cross sectional study.

Sample size: 40

Sampling procedure: All patients referred to Radiology department with histologically proven oral cavity lesions for Computed Tomographic evaluation will be enrolled in the study following the inclusion and exclusion criteria after obtaining an informed written valid consent.

Equipment Used

Toshiba Activion 16 slice Multidetector Helical CT scanner.

METHODOLOGY

The consented test subjects are subjected to a preliminary conventional Plain and Contrast enhanced axial CT scans of the oral cavity and neck. Then the test subjects were asked to inflate their cheeks, purse their lips and hold their breath as described by Weissman and Carrau., While 3 or 5mm thick Helical cuts of the oral cavity are taken with no interspace gap. The scanning range is kept from the supraorbital margin to the arch of aorta at the level of T2 vertebrae. The puffed cheek maneuver scan is carried out before and after administration of non ionic intravenous contrast agent. For continuous imaging, the scanning equipment was set at 120kV, 90-110 mA, 5mm thickness and 5mm table movement.

Scan parameters were set as follows: 64 0.75-mm scan collimation, recon increment 0.70 mm, pitch 0.75, mAs 90, potential (kV) 120, CDTIvol (mGy) 6.24, isotropic voxel, field of view 200 mm, rotation time 0.50 seconds, matrix of acquisition 512 _ 512, and matrix of reconstruction 512 _512. Images were reconstructed by using both a soft tissue (kernel h31) and a high-resolution bone algorithm (kernel h60) with 1-mm thickness. No gantry tilt was given in any of the cases. To assess contrast enhancement of the mass about 50-60ml of non-ionic intravenous iodinated contrast agent (350mg/ml) was

administered at a rate of 2.5- 3 mL/s using a pressure injector. Images in the arterial phase of enhancement was obtained at 20-25secs after complete injection of contrast material. Multiplanar reconstruction into coronal and sagittal sections were achieved using computed algorithm for complete evaluation of oral cavity.

Interpretation

Reconstructed 1mm volumetric data were networked to an Apple workstation equipped with commercially available software (OsiriX 64bit Imaging software), which allows multiplanar reformation. A single experienced Radiologist interpreted every case by simultaneously comparing the puffed cheek and closed mouth images and assessing the extend and infiltration of the lesion. The images were evaluated both in bony window (WL500; WW2500) and soft tissue window (WW80; WL260). Enhancement pattern was considered characterised as homogeneous or heterogeneous and considered significant if precontrast and post contrast values were more than 20HU. The lesions were staged according to TNM Staging. The largest dimensions of the mass lesion was taken both in Antro-posterior, Breath and Height in all three planes using Alpha Angle ROI callipers in OsiriX 6.5

Dicom software in Apple Mac-pro work station.

Tumour mass – Largest dimensions of the mass was taken in height, width and length in coronal, axial and sagittal planes using ROI calliper using OsiriX

6.5 Dicom software in both puffed cheek and closed mouth images. The attenuation and enhancement characteristics were studies. The extend of the lesion along with infiltration of adjacent organs were compared on both the sets of images.

Bony assessment – Bony infiltration was assessed in bone window setting in axial coronal and sagittal planes. Three dimestional bony reconstruction was done in suspected cases of bony involment.

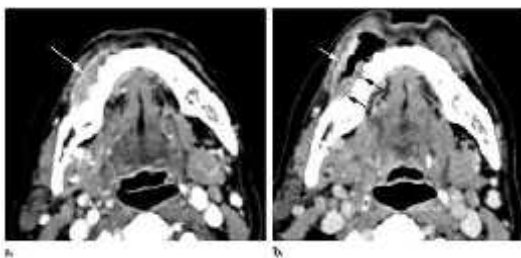
Lymph nodes – Lymph nodes were staged according to the anatomic location. Nonspecific lymph nodes were homogeneously enhancing with size less than

1.5cms in short axis. Lymph nodes of more than 1.5cms in size on short axis were considered significant. Nodes with central hypoattenuating area of necrosis with peripheral rim enhancement were considered as definite evidence of

RESULTS AND DISCUSSION

Sex Distribution

The total number of patients selected were 40. Among them 25 were males and 15 were females. The lesion was most commonly found to be on the right side.



Squamous cell carcinoma of the right buccal vestibule. (a) Axial CT scan shows a tumor (arrow) but does not clearly demonstrate which wall is involved. (b) Axial CT scan obtained with the puffed cheek technique shows involvement of both the buccal mucosa (white arrow) and the gingival mucosa (black arrows).

Comparison of conventional CT study and of PUFFED cheek CT with histopathological co relation

During the duration of the study the subjects were followed up to the process of biopsy where in histopathological data was collected. The total number of HPE positive cases were found to be 30. As HPE is considered as the best predictor of disease they were compared with the findings of conventional and puffed CT. Conventional CT was able to pick up 10 out of the 30 HPE positive cases and showed a high number of false negatives .contrary to conventional ct, puffed CT was able to pick about 22 out of the HPE positive cases.

The sensitivity with conventional CT was found to be around 33 % and that of puffed cheek CT was found to be about about 73.3 % for the detection and staging of malignancy of oral cavity lesions

	positive	sensitivity
HPE	30	
Conventional ct	10	33.3%
Puffed cheek CT	22	73.3%

Later puffed cheek CT and conventional CT were individually compared with the HPE positive cases and the statistics were computed as follows Puffed cheek CT had a sensitivity of 80%, specificity of 28 %.it also had a positive predictive value of 33.3 % and negative predictive value of 75%.in prediction of oral malignancies.

Methods ofCT	Conventional CTN=30	
	Positive N=10	Negative N=20
PuffedCheek CT N=30	8	14
	2	6

Size of the lesion

In this study, the maximum size of the lesion measured in puffed cheek and conventional CT were compared with the maximum size of the gross pathologically resected specimen at the time of surgery. The largest size of lesion was taken in the plane in which it was well seen and measured using digital calipers in Osirix software in Mac-pro work station for all 40 cases included in the study and compared with the resected tumour size which was measured using vernier callipers. The mean lesion sizes were calculated for all the 40 cases and the mean and standard deviation computed for the gross specimen size, Conventional CT size and Puffed cheek CT size. The student paired t test was used to establish a significant statistical difference between the lesion size among all three modalities where p value of $\lt; 0.01$ was considered

statistically significant. The gross specimen size was taken as standard and compared to lesion size in Puffed cheek CT and Conventional CT. The mean in gross specimen was 3.47 where as the mean for conventional and puffed ct was found to be 3.10 and 3.37 respectively

DISCUSSION

About 80% of the cases included in the study were able to perform the puffed cheek maneuver with ease. The subjects were able to distend the oral cavity well and maintain the same throughout the entire length of scanning time without much discomfort. The maneuver was considerably simple to explain to the patient and could be executed with ease.

Puffed cheek manoeuvre was highly useful in 73.3% of cases and was not much helpful in 24.7.8%. It can thus be concluded that Puffed Cheek CT images are superior to conventional CT scan for visual identification and evaluation of oral lesions. Our study showed that puffed cheek CT technique was quintessential for identification of lesions of retromolar trigone region and was not much value if the tumour was T4 stage.

Puffed Cheek CT has a sensitivity of 73.3% compared to 33.3% for conventional closed mouth CT in evaluation of malignant lesions of oral cavity. Puffed cheek

CT was accurately able to stage malignancies in 22 cases compared to 10 cases in conventional CT where the staging matched the standard histopathological stage. Puffed cheek CT had a positive predictive value of 33.3% and a negative predictive value of 75% compared to conventional CT in staging oral malignancies.

The size of the lesion measured using puffed cheek CT technique correlates well with the actual size of the lesion after surgical resection. Thus Puffed Cheek CT scan is better than conventional CT scan for delineating the extend of the tumour and for accurate assessment of lesion size.

Puffed cheek CT was proved to be more accurate than conventional CT for evaluation of maximal tumour sizes especially in Retromolar Trigone lesions. The size of the lesion measured and the extend of lesion seen using puffed cheek CT technique correlates well with the actual size of the lesion and extent seen during surgery

CONCLUSION

Thus we were able to conclude from our study that Puffed-cheek CT scans provide a clearer and more detailed evaluation of mucosal surfaces of the oral cavity than do conventional images. Standard CT alone can be insufficient for tumour localization, imaging during distension may contribute to a more exact localization and helps in better management of the patient.

With such small and practical interventions better image quality was achieved and results showed puffed cheek CT can be reliably advocated in all of oral cavity CT investigations

References

- Weissman JL, Carru RL, Puffed cheek CT improves evaluation of the oral cavity. *AJNR AmJ Neuroradiol* 2001; 22(4): 741-4.
- Gale DR CT and MRI of the Oral Cavity and Oropharynx In: Valvasori GE, Mafee MF, Carter BL eds, *Imaging of the Head and Neck* New York; Thieme
- Mukherji SK, Phillipsbury HR, Castillo M. Imaging Squamous cell carcinoma of the upper aerodigestive tract: What Clinicians need to know: *Radiology* 1997; 205(3): 629-46
- Brederen K, Aalokken TM, Kolkenstvedt A. CT of the Oral Vestibule with distended cheeks: *Acta Radiol* 2001; 42 (1): 84-87 .31
- Simon LL, Rubinstein D. Imaging of oral cancer. *Otolaryngol Clin N Am* 2006; 39:307-17.
- Muir C, Weiland L; Upper aerodigestive tract cancers. *Cancer*. 1995 Jan 1; 75(1 Suppl):147-53

How to cite this article:

Virupaxappa, T.K et al.2017, Diagnostic Efficacy of Puffed Cheek Ct Compared To Conventional Cect In The Imaging of Lesions of Oral Cavity. *Int J Recent Sci Res*. 8(2), pp. 15579-15582.