



ISSN: 0976-3031

Available Online at <http://www.recentscientific.com>

CODEN: IJRSFP (USA)

International Journal of Recent Scientific Research
Vol. 8, Issue, 7, pp. 19094-19097, August, 2017

**International Journal of
Recent Scientific
Research**

DOI: 10.24327/IJRSR

Research Article

A CLINICAL STUDY TO EVALUATE THE CORRELATION BETWEEN MAXILLARY RIGHT CENTRAL INCISOR FORM AND FACE FORM IN INDIAN POPULATION

Divyesh Modi S¹, Rupal J Shah² and Dharmendra V. Sindha*³

¹Dental Surgeon, CHC, Prantij

²Department of Prosthodontics, Govt. Dental College and Hospital, Ahmedabad

DOI: <http://dx.doi.org/10.24327/ijrsr.2017.0807.0629>

ARTICLE INFO

Article History:

Received 15th May, 2017

Received in revised form 25th June, 2017

Accepted 23rd July, 2017

Published online 28th August, 2017

Key Words:

Correlations, tooth form, face form.

ABSTRACT

Context: The spatial relationship of maxillary right central incisor form and face form varies among individuals. Such variability could be correlated to each other.

Aims: To determine the correlation between maxillary central incisor tooth form and face form in males and females of Indian population.

Method: In the present study, a total of 100 dentulous dental student subjects (50 males and 50 females) of Indian origin were randomly selected. Images of the face and the maxillary right central incisors were captured and then they were transferred to a computer having image editing software. The facial outline form was determined. The maxillary right central incisor tooth form was determined. Correlation was made between tooth form and face form.

Statistical Analysis Used: The data were analyzed using chi-square test for association and Z- test for quality of proportion.

Results: Mean correlation between maxillary central incisor tooth form and face form in Indian population exhibited greater correlation which was highly significant.

Conclusion: Highly defined correlation exists between maxillary central incisor form and face form in males and females of Indian population.

Copyright © Divyesh Modi S et al, 2017, this is an open-access article distributed under the terms of the Creative Commons Attribution License, which permits unrestricted use, distribution and reproduction in any medium, provided the original work is properly cited.

INTRODUCTION

Esthetics is defined as being a derivative of the Greek word *aisthetikos*, meaning perceptive¹. Facial beauty can be defined as a state of balance and harmony among facial features and it is influenced by several factors.²

Facial appearance has important social and psychological effect on the human personality; the features most commonly associated with facial attraction are the eyes and mouth.^{3,4}

The selection of appropriate size of maxillary anterior teeth is one of the most confusing and difficult aspect of complete denture construction.⁵ Since the prosthesis replacing anterior teeth frequently look artificial because the teeth which have been selected are smaller than the natural teeth which they are replacing, and this is considered a problem in fabricating dentures.⁶

The correct choice of artificial tooth size begins by selecting the size and width of the six anterior maxillary teeth, although there is no consensus among authors regarding the existence of methods for such selection.⁷ In clinical settings for all dental

specialties, it is essential to use the correct proportion between teeth and face, in order to make forms more balanced and harmonious.⁷

The prosthodontic literature seems to pertain only to foreign population and it is apparent that there is a lack of information in Indian population regarding selection of maxillary central incisors forms.¹

Hence, an attempt is made in the present study to clinically evaluate the correlation between maxillary central incisor form and face form in Indian population and the correlation thus obtained could be used in selection of artificial maxillary central incisors for edentulous patients in Indian population. The aim of the presents study was to clinically evaluation between maxillary central incisor form and face form in an Indian population so as to guide the selection of artificial maxillary central incisors in edentulous patients.

Aims and Objectives

1. To determine the correlation between maxillary central incisor tooth form and face form in males and females of an Indian population.

*Corresponding author: Dharmendra V. Sindha
Govt. Dental College and Hospital

2. To determine the predominant maxillary central incisor tooth form in males and females of an Indian population.
3. To determine the predominant face form in males and females of an Indian population.

METHOD

Prior to the initiation of the study, approval was granted by Ethical Committee of the Institute. In the present study, a total of 100 dentulous dental student subjects (50 males and 50 females) of Indian origin with age ranging from 18 to 28 years studying at Govt. Dental college and hospital, Ahmedabad were randomly selected.

The subjects ranging from 18-28 years of age, completely dentate arch with presence of natural maxillary anterior teeth in good alignment were selected. The subjects undergone any restoration, with anterior teeth fractures, maxillary anterior teeth with extensive carious lesions, undergone orthognathic surgery, or orthodontic treatment and tooth shape anomaly were excluded from the study.

A standardized photographic procedure was developed to obtain images of the face and the maxillary right central incisors. Two standardized photographs were taken for each subject: portrait (closed lips) and the maxillary incisors (without closing lips). For each photograph, standardized distances were used.

The standardized photographic procedure was followed for intraoral photographs of maxillary central incisors were obtained until the lens was parallel to the labial surface of the teeth. Cheek retractors were used to obtain full exposure of the maxillary central incisors.

The images of the teeth and the face were then transferred to a computer (windows PC, Microsoft) having image editing software (Photoshop CS5 Adobe). The facial outline form was determined by the outline of the temporal bone at the height of the hairline thus including forehead. The line then curved downward to the temporal process of the zygomatic arch and lateral most point of zygomas and each line continued following outline of cheek and chin until meeting in the region of symphysis menti.

The maxillary right central incisor tooth form was determined by an outline tracing made around the buccal surface of the tooth, which corresponded to the mesial and distal contours, the incisal edge and the cervical margin. The outline tracing of the maxillary central incisor tooth form was inverted and positioned over the outline tracing of the face form, so that the pairs of the outline tracings (face and the tooth) were enlarged until they were about the same size and saved as separate image files. The photographic print outs were taken.

The photographic evaluation in classifying the outline tracing prints of the face form and the maxillary central incisor tooth form by visual method was performed by 5 postgraduate students studying prosthodontics and having 2 years of experience. The outline tracing prints of the face form and the maxillary right central incisor tooth form were classified first into square, tapering, ovoid forms by visual method. The means were taken and respective percentages were calculated to determine the correlation between maxillary central incisor

tooth form and face form by visual method using chi-square test for association and Z- test for quality of proportion.

RESULT

By present study following results were concluded.

1. Mean correlation between maxillary central incisor tooth form and face form of the entire sample (males and females) of Indian population by visual method exhibited greater correlation which was highly significant.

Mean correlation between maxillary central incisor tooth form and face form in males of Indian population by visual method exhibited greater correlation , which was highly significant.

Table 1 Descriptive Statistics for Comparison Between Maxillary Central Incisor Tooth Form And Face Form

Face form	Tooth form				Total
	Square	Ovoid	Tapering	Combination	
Square	19	7	4	11	41
Ovoid	6	17	7	7	37
Tapering	4	5	10	3	22
Total	29	29	21	21	100

Pearson Chi-Square Value: 23.315
DF:6
P Value: 0.001

Mean correlation between maxillary central incisor tooth form and face form in females of Indian population by visual method exhibited greater correlation, which was highly significant.

2. The predominant maxillary central incisor tooth form in males was square tooth and in females was ovoid tooth by visual method. which was not significant.

Table 2 Descriptive statistics for comparison of predominant maxillary central incisor tooth form in males and females.

Face form	Males	Females
Square	16	13
Ovoid	13	16
Tapering	11	10
Combination	10	11
Total	50	50

Pearson Chi-Square Value: 0.716
DF: 3
P Value: 0.869

3. The predominant face form in males and females of Indian population was square face in males and ovoid face in females by visual method, which were not highly significant.

Table 3 Descriptive statistics for comparison of predominant face form in males and females of Indian population

Face form	Males	Females
Square	25	16
Ovoid	16	21
Tapering	9	13
Total	50	50

Pearson Chi-Square Value: 3.379
DF: 2
P Value: 0.185



Figure 1 Outline tracing of face form

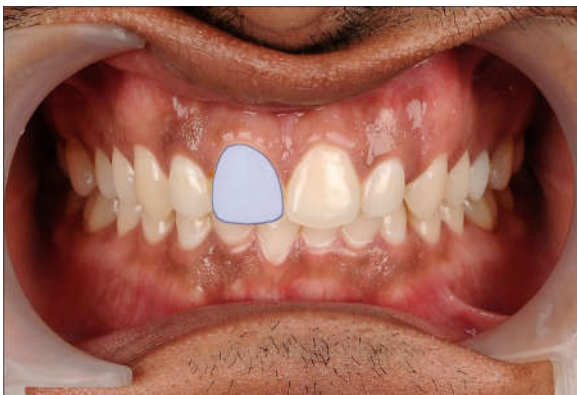

Figure 2 Outline tracing of tooth form

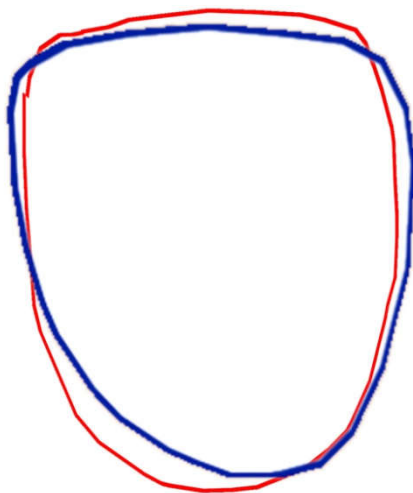


Figure 3 Superimposition of face form and tooth form

DISCUSSION

Patient oral rehabilitation must take into consideration factors such as shape, placement and color of the maxillary central incisors; these are key characteristics to obtain an aesthetically harmonious smile, contributing to improve the facial balance. Nevertheless, sex, age, ethnicity and even the personality and aesthetic wishes of each patient must be considered.¹ The correlation between tooth form and face form by Visual method for the entire sample in the present study was 46%

correlated. The result is less than the previous study 56 % and 51% respective studies^{8,9}. But more than previous study 39 % and 30% respective studies^{10,11}.

The correlation between tooth form and face form in males by Visual method for the entire sample in the present study was 40%. This is more than previous studies 1, 12 as 37% and 20% respectively. The correlation between tooth form and face form in females by Visual method for the entire sample in the present study were 52%. This is more than previous studies 1, 12 as 28 % and 30% respectively. The predominant face form in males and females by visual method for the entire sample in the present study as shows square face 50%. followed by tapering 32% and ovoid 18% faces for males and was ovoid face 42% followed by square 32% and tapering 26% faces for females.

The predominant tooth form in males and females by visual method for the entire sample in the present study as shows that out of total 100% square tooth forms 32% predominate in males followed by tapering 26 % and ovoid 22% tooth forms and 20% combination tooth form out of 100% In females, the predominant tooth form was ovoid tooth form 58% followed by square tooth forms 26% and tapering 20% and 22% combination tooth form out of 50 (100%).

CONCLUSION

It was concluded from the present study that there was highly defined correlation between maxillary central incisor form and face form in males and females of Indian population. Till date, very few studies have been done to evaluate the correlation between tooth form and face form in Indian population. Hence, further research regarding the correlation between maxillary central incisor form and face form in males and females of Indian population is needed to validate the outcome of this investigation.

References

1. Pavankumar R. Koralakunte; A clinical study to evaluate the correlation between maxillary central incisor tooth form and face form in an Indian population; *Journal of Oral Science*, Vol. 54, No. 3, 273-278, 2012
2. Luiz Renato PARANHOS1, Correlation between Maxillary Central Incisor Crown Morphology and Mandibular Dental Arch Form in Normal Occlusion Subjects ; *Braz Dent J* (2012) 23(2): 149-153
3. L. Ibrahimagi, Relationship between the Face and the Tooth Form; *Coll. Antropol.* 25 (2001) 2: 619-626
4. Vallittu, p. k., a. s. vallittu, v. p. lassila, *J. Dent.*, 24 (1996) 335.
5. Nagham H Kassab; The selection of maxillary anterior teeth width in relation to facial measurements at different types of face form: *Al-Rafidain Dent J* Vol. 5, No. 1, 2005
6. Petricević N, Katunarić M, Mehulić K, Simeon P, Rener-Sitar K, Celebić A. Selection of appropriate artificial frontal teeth size using dimensions of hard palate. *Coll Antropol* 2006; 30:573-577.
7. Engelmeier RL. Complete-denture esthetics. *Dent Clin North Am* 1996; 1:71-84.

8. Sellen PN, Jagger DC, Harrison A (1998) Computer generated study of the correlation between tooth, face, arch forms, and palatal contour. *J Prosthet Dent* 80, 163-168.
9. Berksun S, Hasanreisoglu U, Gökdeniz B (2002) Computer-based evaluation of gender identification and morphologic classification of tooth face and arch forms. *J Prosthet Dent* 88, 578-584.
10. Wright WH (1942) Correlation between face form and tooth form in young adults. *J Am Dent Assoc* 29, 1388-1392.
11. Varjão FM, Nogueira SS, Russi S, Arioli Filho JN (2006) Correlation between maxillary central incisor form and face form in 4 racial groups. *Quintessence Int* 37, 767-771.
12. Smily PK, Nair KNV, Kumar CP, Nagaraj KR, Kumar MV (2002) Gender difference in harmony between tooth, face and arch form. *J Indian Prosthodont Soc* 2, 24-25

How to cite this article:

Divyesh Modi S et al.2017, A Clinical Study To Evaluate The Correlation Between Maxillary Right Central Incisor Form And Face Form In Indian Population. *Int J Recent Sci Res.* 8(8), pp. 19094-19097.

DOI: <http://dx.doi.org/10.24327/ijrsr.2017.0808.0629>
