



ISSN: 0976-3031

Available Online at <http://www.recentscientific.com>

CODEN: IJRSFP (USA)

International Journal of Recent Scientific Research
Vol. 8, Issue, 8, pp. 19338-19340, August, 2017

**International Journal of
Recent Scientific
Research**

DOI: 10.24327/IJRSR

Research Article

MULTIPLE HYPERDONTIA: CASE REPORT WITH MULTIPLE SUPERNUMERARY PREMOLARS

Aditya Mohan¹, Sudheer MVS², Srikanth Damera³ and Ramya B⁴

¹Department of Oral and Maxillofacial Surgery, MNR Dental College & Hospital, Sangareddy

²Oral & Maxillofacial Surgeon, Hyderabad

³Department of Oral and Maxillofacial Surgery, GSL Dental College, Rajamundry

⁴IIT Hyderabad

DOI: <http://dx.doi.org/10.24327/ijrsr.2017.0808.0673>

ARTICLE INFO

Article History:

Received 16th May, 2017

Received in revised form 25th

June, 2017

Accepted 23rd July, 2017

Published online 28th August, 2017

ABSTRACT

Hyperdontia or presence of multiple Supernumerary teeth is a rare condition. This condition leads to many problems in the function of the jaw and in maintenance of hygiene of oral cavity. The etiology of hyperdontia is poorly understood. The authors present a case of multiple supernumerary premolars in three quadrants of the dentition. The review of literature of multiple hyperdontia and the classification is described in the article.

Key Words:

Hyperdontia, supernumerary teeth, CB CT,
3 Dimensional CT Scan

Copyright © Aditya Mohan et al, 2017, this is an open-access article distributed under the terms of the Creative Commons Attribution License, which permits unrestricted use, distribution and reproduction in any medium, provided the original work is properly cited.

INTRODUCTION

Hyperdontia is a rare alteration of odontogenesis defined as the presence of any tooth or tooth substance in excess of the normal dental formula. The prevalence rates of supernumerary teeth in the permanent dentition, reported in the literature, vary between 0.1 and 6.9% [1]. Maxillary anterior region is the most commonly predisposed of supernumerary teeth. The most often supernumerary teeth are observed in the central incisors region (so-called mesiodens) [2]. Next in relation to the occurrence frequency are supernumerary premolars (0.034-0.84% of the population) [3]. Supernumerary teeth in the molar region are usually rudimentary paramolars or distomolars [4]. Fourth molars are very rare disorder relating to the teeth number and usually their presence is noticed not until on the radiographs [5].

The causes of supernumerary teeth are poorly understood, although many theories have been proposed, such as phylogenetic process of atavism and the dichotomy of the tooth bud. The most accepted theory suggests that these teeth results from localized and independent hyperactivity of the dental lamina, which presumably leads to the formation of additional tooth germs. [6]

In this case report, we present a case of non syndromic six supernumerary teeth involving three quadrants which are premolar and a supernumerary tooth in the first quadrant, a canine and two premolars in the second quadrant and a premolar on the third quadrant.

Case Report

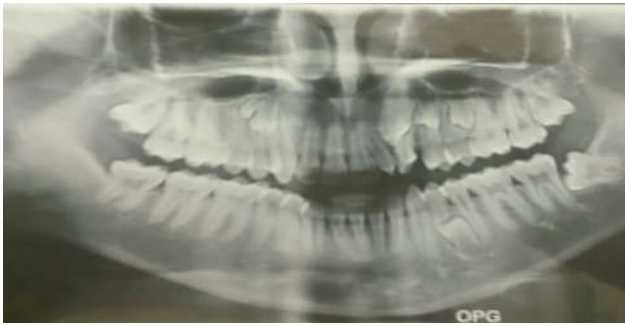A 13 year old male patient was reported with pain in the upper jaw in the middle region since one month. The pain was dull aching pain which was relieved on medication (analgesics). On clinical examination, there was no pulpal and periapical pathology noted. Electric pulp testing was done and the pulp was vital. An orthopantomograph was advised for radiological evaluation. The orthopantomograph revealed multiple supernumerary teeth. [Picture 1]

There are a total of seven supernumerary teeth in three quadrants. In the first quadrant, there are two supernumerary teeth one is a premolar and another is morphologically altered tooth. In the second quadrant, there are three supernumerary teeth, one canine and two premolars. In the third quadrant, there is one supernumerary premolar.

*Corresponding author: **Aditya Mohan**

Department of Oral and Maxillofacial Surgery, MNR Dental College & Hospital, Sangareddy

As the apices of the supernumerary teeth are not formed yet and there is resorption of the erupted teeth which has supernumerary teeth to follow, the patient is under follow up.



Picture 1

DISCUSSION

Presence of multiple supernumerary teeth is a rare condition and mesiodens being most commonly seen among the supernumerary teeth. Most of the supernumerary teeth are associated with syndromes such as Gardner's syndrome, cleidocranial dysostosis and cleft lip and palate. It has been reported that the prevalence for non syndromic multiple supernumerary teeth is less than 1%. This condition shows a male predilection of 9:2. [7].

The etiology of hyperdontia is not completely understood. Various theories exist. One theory suggests that the supernumerary tooth is created as a result of a dichotomy of the tooth bud. Another theory, suggests that supernumeraries are formed as a result of local, independent, conditioned hyperactivity of the dental lamina. Heredity may also play a role, because supernumeraries are more common in the relatives of affected children than in the general population [8, 9]. The case described above represent a sample of the possible presentations for cases involving supernumerary teeth. Most cases of supernumerary teeth does not give clinical symptoms, they are detected during radiographic examination, incidentally [10]

Supernumerary teeth may erupt regularly in the oral cavity or be retained in the jaw. Eruption frequency is reported to vary between 1.5 and 34% in the permanent dentition [11], while in the milk dentition about two-thirds of the supernumeraries erupt [12]. In case of our patient none supernumerary teeth were erupted and do not appear to erupt radiographically.

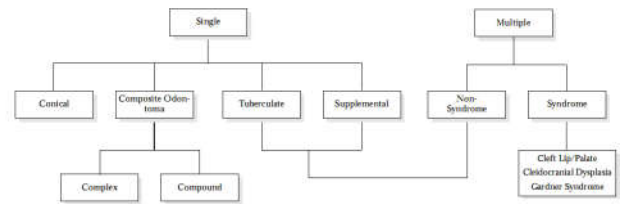
Supernumerary teeth are classified according to morphology and location. In the permanent dentition, there are four different varieties based on the morphology:[13]

- Conical
- Tuberculate
- Supplemental
- odontome

The supernumerary teeth are also classified in a comprehensive way. [14] Table 1

There are various problems associated with supernumerary teeth such as, failure of eruption of the adjacent teeth, Displacement and delayed eruption [15] of the adjacent teeth which may lead to crowding.

Table 1 Classification of Supernumeraries



some of the un erupted teeth may remain asymptomatic without causing any complications, while some supernumerary teeth may be associated with pathology [16] or may cause resorption of the roots of the adjacent teeth [17].

Radiographic Examination of supernumerary teeth

A radiographic examination is indicated if abnormal clinical signs such as abnormal crowding or drifting of the teeth are noticed. Plain radiographs serve the purpose in most of the cases. Two radiographs in perpendicular direction aid in exact orientation of the supernumeraries. An intra oral periapical radiograph and an occlusal view are of good use for the supernumeraries in the anterior region of the jaw. Extraoral views such as orthopantomographs and lateral cephalograms may be used for the localization of the supernumeraries. Recently developed three-dimensional imaging system, cone beam computed tomography may be used in the detailed evaluation of supernumerary teeth. The cBct system provides considerably more information for oral diagnostic purposes. But before carrying out investigation, the necessity of cBct and risk and advantage analysis needs to be determined. [18]

Management of Supernumeraries

Treatment depends on the type and position of the supernumerary tooth and on its effect or potential effect on adjacent teeth. The management of a supernumerary tooth should be taken whether to extract or retain by careful clinical and radiographic observation.

Timing of surgical removal of supernumerary teeth has also been controversial. Hogstrum and Andersson [17] suggested two alternatives exist. The first option involves removal of the supernumerary as soon as it has been diagnosed. This could create devitalization or deformation of adjacent teeth in a young child when adjacent teeth are not completely formed. Secondly, the supernumerary could be left until root development of the adjacent teeth is complete. The potential disadvantages associated with this deferred surgical plan include; loss of eruptive force of adjacent teeth, loss of space and crowding of the affected arch, and possible midline shifts. Obviously the position, size and nature of the supernumerary and the level of co-operation of the patient will influence the surgical difficulty and each case should be individually assessed. From the evidence available it would seem prudent to treat by removal of the supernumerary only in cases where adequate space is available for the adjacent permanent tooth to erupt. The space should be monitored to ensure that it does not close, and the delayed tooth should be given approximately 18 months to spontaneously erupt. G. Siva Prasad Reddy *et al*, [19] opined that the clinical management of multiple supernumerary teeth poses a great challenge to clinicians. Therefore, it is important to initiate appropriate consultation and an interdisciplinary approach for the treatment.

The case described above represents a possible presentation of cases involving multiple supernumerary teeth. It is essential to identify teeth clinically and radiographically before a definitive diagnosis is made.

CONCLUSION

It is essential not only to enumerate but also to identify the supernumerary teeth (ST) present clinically and radiographically before a definitive diagnosis and treatment plan can be formulated. Early diagnosis and extraction of Supernumerary teeth may prevent malocclusion and dental abnormalities such as delayed eruption of permanent incisors, rotation of the permanent incisors and diastema.

Wait and watch policy is followed in this case because there is resorption of the erupted permanent teeth is seen hence the permanent teeth cannot be saved, so the supernumerary teeth cannot be extracted. But the apices of supernumerary teeth are not completely formed yet. So the permanent teeth are not extracted. So we are waiting for the apical closure of the supernumerary teeth to proceed with the treatment.

References

1. Davis PJ. Hypodontia and hyperdontia of permanent teeth in Hong Kong school children. *Community Dent Oral Epidemiol* 1987; 15(4): 218-220.
2. Yusof WZ. Non-syndrome multiple supernumerary teeth: literature review. *J Can Dent Assoc* 1990; 56(2): 147-149.
3. Rubenstein L., Lindauer S., Isaacson R., Germane N. Development of supernumerary premolars in an orthodontic population. *Oral Surg* 1991; 71 (3): 392-395.
4. Zhu JF, Marcushamer M, King DL, Henry RJ. Supernumerary and congenitally absent teeth: a literature review. *J Clin Pediatr Dent* 1996; 20(2): 87-95.
5. Nagaveni NB, Umashankara KV, Radhika NB, Praveen Reddy B, Manjunath S. Maxillary paramolar: report of a case and literature review. *Arch Orofac Sci* 2010; 5(1): 24-28.
6. Ana P. P. dos Santos, Michelle M. Ammari, Luiz F.M. Moliterno and Jonal CarPELLI Junior; First report of bilateral teeth associated with both primary and permanent maxillary canines; *Journal of Oral Science*, Vol 51, No. 1, 145-500, 2009
7. A Acikgoz, G Acikgoz, U Tunga and F Otan; Characteristics and prevalence of non-syndrome multiple supernumerary teeth: a retrospective study; *Dentomaxillofacial Radiology* (2006) 35, 185-190
8. Liu JF. Characteristics of premaxillary supernumerary teeth: a survey of 112 cases. *ASDC J Dent Child* 1995; 62: 262-265.
9. Levine N. The clinical management of supernumerary teeth. *J Can Dent Assoc* 1961; 28: 297-303
10. Bayrak S, Dalci K, Sari S. Case report: Evaluation of supernumerary teeth with computerized tomography *Oral Surg Oral Med Oral Pathol Oral Radiol Endod* 2005; 100(4): e65-69.
11. Rajab LD, Hamdan MA. Supernumerary teeth: review of the literature and a survey of 152 cases. *Int J Paediatr Dent* 2002; 12(4): 244-254.
12. Humerfel t D, Hurlen B, Humerfel t S. Hyperdontia in children below four years of age: a radiographic study. *ASDC J Dent Child* 1985; 52(2): 121-124.
13. Mitchell L. An Introduction to Orthodontics. 1st ed. Oxford University Press; 1996. p. 23-25
14. M. Therese Garvey, Hugh J. Barry, Murielle Blake: Supernumerary Teeth-An Overview of Classification, Diagnosis and Management: *J Can Dent Assoc* 1999; 65:612-6
15. Howard RD. The unerupted incisor. A study of the postoperative eruptive history of incisors delayed in their eruption by supernumerary teeth. *Dent Pract Dent Red* 1967; 17:332-41.
16. Primosch RE. Anterior supernumerary teeth-assessment and surgical intervention in children. *Pediatr Dent* 1981; 3:204-15.
17. Hogstrom A, Andersson L. Complications related to surgical removal of anterior supernumerary teeth in children. *ASDC J Dent Child* 1987; 54:341-3
18. E.C. tumen, Yavuz, D.S. Tumen, N. hamamci, G. Berber, F. Atakul, Uysal: The detailed evaluation of supernumerary teeth with the aid of cone beam computed tomography: *Biotechnology & Biotechnological Equipment: Volume 24, Number 2/ May 2010*
19. G. Siva Prasad Reddy, G. V. Reddy, I. Venkata Krishna, and ShraVan Kumar Regonda; Nonsyndromic Bilateral Multiple Impacted Supernumerary Mandibular Third Molars: A Rare and Unusual Case Report; *Case Reports in Dentistry Volume 2013, Article ID 857147*

How to cite this article:

Aditya Mohan *et al.* 2017, Multiple Hyperdontia: Case Report With Multiple Supernumerary Premolars. *Int J Recent Sci Res.* 8(8), pp. 19338-19340. DOI: <http://dx.doi.org/10.24327/ijrsr.2017.0808.0673>
