



ISSN: 0976-3031

Available Online at <http://www.recentscientific.com>

CODEN: IJRSFP (USA)

International Journal of Recent Scientific Research
Vol. 8, Issue, 9, pp. 20098-20101, September, 2017

**International Journal of
Recent Scientific
Research**

DOI: 10.24327/IJRSR

Research Article

COMPARITIVE STUDY OF IMMEDIATE VS DELAYED PLACEMENT OF IMPLANT A RADIOGRAPHIC EVALUTION OF 80 CASES

Vijay Ebenezer* and Saravanan D

Department of Oral and Maxillofacial Surgery, Sree Balaji Dental College & Hospital, Bharath
Unniversity, Pallikaranai, Chennai, 600100

DOI: <http://dx.doi.org/10.24327/ijrsr.2017.0809.0826>

ARTICLE INFO

Article History:

Received 05th June, 2017
Received in revised form 08th
July, 2017
Accepted 10th August, 2017
Published online 28st September, 2017

Key Words:

Autogenous bone grafts, atraumatic
extraction, peri implantitis, bone resorption,
ridged fixation.

ABSTRACT

Previously in the field of dental implantology, each and every patient had to wait for at least 8 to 12 months for the extracted site to heal and remodel with the formation of secondary new bone formation for the placement of the implant and for the further fixed prosthesis and it is called as delayed implant placement and now a new trends and advanced treatment materials available currently such as autogenous and allogeneous Bone grafts makes the implant placement too easy and the second surgery is avoided and it is called as immediate placement of implant. This article aims to evaluate the clinical stability, efficacy and duration taken for immediate and delayed placement of implant in the extraction sockets.

Copyright © Vijay Ebenezer and Saravanan D, 2017, this is an open-access article distributed under the terms of the Creative Commons Attribution License, which permits unrestricted use, distribution and reproduction in any medium, provided the original work is properly cited.

INTRODUCTION

The earliest possible restoration to achieve proper form and function is a hallmark of all the surgical specialities, with the discovery of the concept of osteo integration in titanium by professor Branemark in 1952 and his suggestion of its use in dentistry, the dental implant science has seen an ascending phase in its developmental 1960, he demonstrated the ability of natural bone to accept implanted titanium during its remodeling stages leading to accept of osteointegration, patient with loss of teeth can be replaced with dental implants and this provides a great comfort aesthetically and functionally⁽¹⁾, easy maintenance, osseous bone preservation, hygiene around the implant and reduced future maintenance all these appears that dental implant placement in the edentulous region may be a more viable option for today's patient. Regular placement of implant after the bone and the soft tissue is healed without any clinical signs and symptoms after minimal time period of 3 months is known as delayed implant placement. After extraction during the healing period teeth alveolar bone height reduction takes place in the first 6 months 2 years, to avoid this implant treatment protocol have been changed, which aimed at shortening the treatment period and by reducing the number of surgical procedure⁽²⁾. Advanced protocol have been formed in the placement of the implant at the time of extraction

procedure, known as immediate placement of implant⁽³⁾. Placing the implant freshly extracted socket has various advantages such as procedure time is reduced, reduction in second time of surgery, prevention of bone resorption and preservation of bone height and width

MATERIALS AND METHODS

Totally 30 patients those who reported to the department of oral and maxilla facial surgery with a age group ranging between 25 to 50 years who required extraction of teeth for the reasons such as root stumps, carious tooth without any peri apical pathology and sinus tract formation, trauma not involving the alveolar bone and roots absence of acute signs of infection. Bony defects more than 2mm, chronic smokers, tooth close proximity to anatomical structures were taken for the study respectively, and they were divided as group A (Delayed implant) and group B (immediate implant) six months regular follow up and reviews were taken post operatively through clinical inspections and radiographic evaluation. In each patients pre operative photographs and radiographs that includes peri apical and ortho pantamographs were taken, pre operative diagnostic casts were made and inter arch relationship was measured with diagnostic cast. Intraoral periapical radiographs were taken at baseline, 6 and 9 months.

*Corresponding author: **Vijay Ebenezer**

Department of Oral and Maxillofacial Surgery, Sree Balaji Dental College & Hospital, Bharath Unniversity, Pallikaranai, Chennai, 600100

The level of crestal bone height was measured from standardized radiographs as the distance from the cemento-enamel junction of the adjacent tooth to the most apical extent of the crestal bone, using vernier calipers⁽⁴⁾, and presence or absence of peri-implant radiolucency. All the implants were checked for mobility with the two blunt ends of the instrument to see for any perceivable mobility.

Study models were prepared for each patient and occlusal analysis was performed. Complete hemogram was done to evaluate the fitness of the patient for implant placement. Before surgery, the patients were advised to rinse for 1 minute with 0.2% chlorhexidine mouthwash. After local anesthesia, teeth were gently extracted using Periostomes and extreme care was exercised to avoid fracture of the socket walls. After extraction, the site was thoroughly degranulated using curettes, the socket irrigated thoroughly with Povidine- Iodine and carefully examined to be certain that the socket walls were intact. The length and width of the extracted root was measured with UNC-15 probe to determine the length and diameter of implant placed. The osteotomy sites were prepared with standard drills using the socket walls as guides, with maximum use of bone apical to the extraction sockets. After the pilot drill, parallelism was checked using paralleling pin and a radiograph. A sequential drilling was carried out with drill sequences of 2.2, 2.8, 3.2, 3.65, 4.3 and 5 with a speed ranging from 500 to 1200 rpm under copious irrigation.

The drill was extended 3 to 4 mm beyond the apex of the socket to ensure primary stability after placement, taking care of the anatomical boundaries. Once the osteotomy site was prepared, the longest and widest possible implants were placed. All the implants placed had shown good primary stability. Prior to suturing, the surgical area was thoroughly irrigated and debrided. The buccal and lingual soft tissue edges were sutured using 3-0 (Ethicon Limited, Edinburgh, UK) silk sutures to enable maximum approximation and to ensure soft tissue coverage to protect the implant sites followed by placement of periodontal dressing. Antibiotics and analgesics were prescribed for all patients for 5 days along with chlorhexidine mouth wash for 15 days.

Sutures were removed after 7 days. The supra structures were seated 6 months post- surgically. All the clinical and radiological parameters were recorded at 6 months. Recall appointments were made every 3 months post insertion and the necessary clinical and radiological measurements were made.

RESULT

A total of 33 implants are placed in 30 patients which includes 18 male patients and 15 female patients with age group range from 22 to 37 years. Out of total 33 implants placed, 28 implants are successful, and 5 implants were failure in 4 patients, 1 in immediate implant and 4 implants in delayed placement two implants were removed after 3 months and three implants after 6 months, the reason for failure of these implants cases are due to lack of osteointegration, poor intra oral maintenance, all the 5 cases showed periapical radiolucency and marginal crestal bone loss. Over all the success rate of implant in this study is 70%, the clinical and radiological follow ups were made till the 6 months for the study.

Radiographs

Delayed

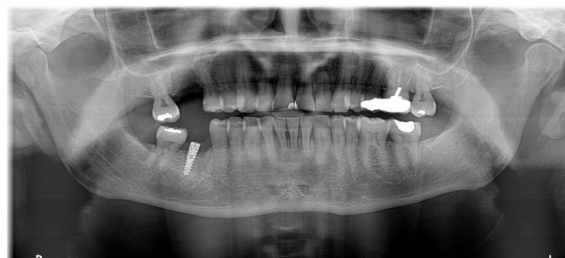


Fig 1 Pre Operative Radiograph

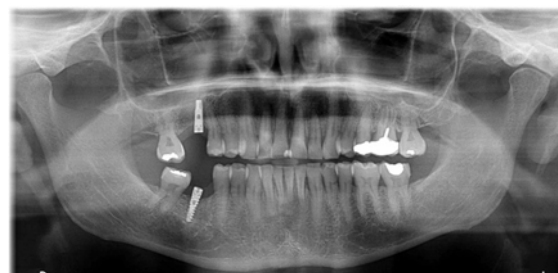

Fig 2 Post Operative Radiograph

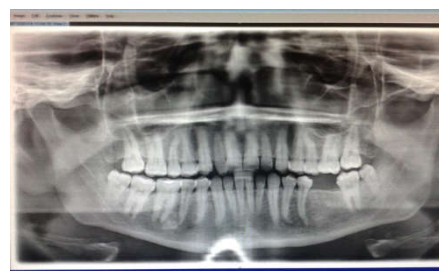

Fig 3 Pre Operative

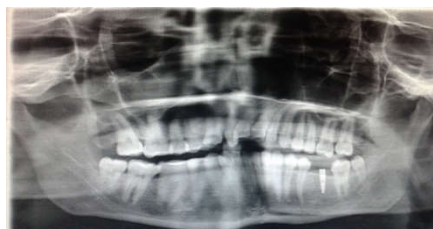

Fig 4 Post Operative

Immediate Implant Radiographs

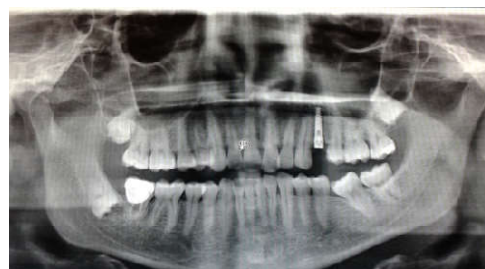

Fig 5 Pre Operative

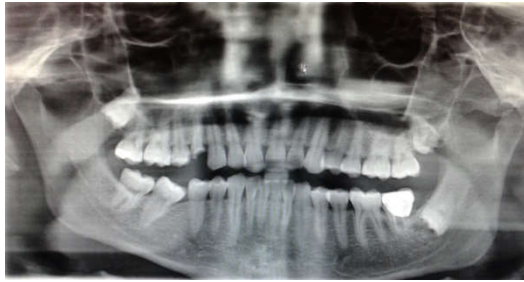

Fig 6 Post Operative

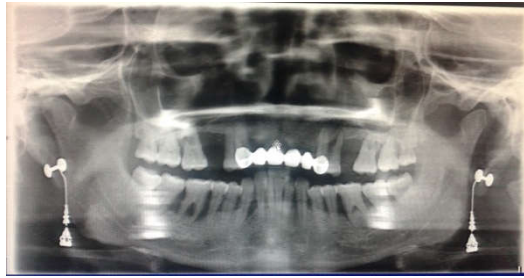

Fig 7 Pre Operative

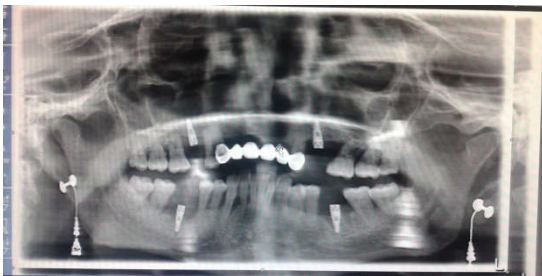

Fig 8 Post Operative

DISCUSSION

Placing Dental implant is the most oldest treatment for replacing the missing teeth than the various conventional prosthesis. patients are much comfortable and satisfied with the implant that are kept endosteally into the bone, out of 33 implants 28 implants showed successful osteointegration because these patients showed good gingival status and no signs of the gingival inflammation, In case of delayed implant placements Misch and Judy, 2000 found out that buccal or facial cortical plate lost during extraction it leads to reduced bone height and thickness for implant placement after the socket heals thereby bone height and width are reduced forcing the operator to compromise with the size and width of the delayed implant. In a similar prospective study, Covani and coworkers reported a mean loss in facial crestal bone height of 0.8 mm after 6 months of submerged healing following immediate implant placement in 20 patients. 38 implant sites included maxillary and mandibular anterior and premolar sites. 38% of the sites showed no change, 47% had between 0 mm and 1 mm of loss, and 15% had between 1 and 2 mm of loss but this amount of bone loss can be considered insignificant when compared to the bone loss after extraction of teeth without any immediate implant placement.^(5,6,7) In Immediate implant placement site of implant to be placed should be minimally prepared and the original anatomy of the extracted socket should not be disturbed since the extracted socket preserves the anatomy of the tooth root which replicates the root form implants. The initial primary stability can be obtained but placing the implant apically 3 mm below the root

socket and 3mm below the crestal bone level^(8,9,10,11), the initial primary stability can be evaluated and checked using resonance frequency analysis.⁽¹²⁾ Various authors and publications have been published regarding the grafts and barrier membrane in the extraction sockets during the placement of the immediate implant.^(13,14,15,16,17,18)

Crestal bone loss is very commonly seen in both immediate and delayed placement of implants, but it is more in the delayed placement of implant. The immediate placement of implant with suitable bone grafts placed into the gap between the socket wall showed a minimal crestal bone loss and better sound bone in immediate implant. Autogenous bone grafts are widely used in these procedures, that are obtained readily available obtained from same patients inter septal bone, interdental bone, buccal cortices and the tuberosity. Implant surgeons usually prefers the autogenous grafts because they have both osteogenic and osteoconductive properties and it is reliable and economic easily taken from the adjacent site respectively. The results are good and unique with huge amount of crestal bone around the implant.

CONCLUSION

Hence The study can be concluded that the placement of the implant immediately or delayed can be evaluated radiographically and clinically, clinically gingival recession, gingival inflammation peri coronal plaque accumulation and food impactions can be assessed where as radiographically crestal bone loss buccolingual height and width along with peri apical radiolucency and marginal bone loss should be suspected, in immediate placement of implants crestal bone loss, bucco lingual bone height and marginal bone deficiency are minimal when compares to the delayed placement of the implant radiographically. So immediate implant is successful minimal time consuming procedure atraumatically and need not to wait for the bone to heal for second stage of surgery. According to our study research samples of 30 all patients showed that immediate placement of implant are promising than the delayed implant placement.

Reference

1. Limor AA George AZ clinical effectiveness of implant supported single tooth replacement, the tornoto study. *int. j oral Maxillofac implants* 1936:11:311-21.
2. Carlsson RA, Person AL. morphologic changes of the mandible. After extraction and wearing of the dentures A longitudinal, clinical and x-ray cephalometric study covering 5 years, *odontologic Review* 1967; 18:27-54
3. Arujo M G Sukekava F. wennstrom J L. Lindhe j. ridge alteration following implant placement in fresh extraction sockets: an experimental study in the dog. *Journal of clinical periodontology* 2005:32:645 -52.
4. FarahM Angelopoulos c.A Comparrison between twotypes of radiographic films for accuracy of measurements of approximal osseous defects. 1 july 2006
5. Becker W, Becker BE, Polizzi G, Bergstrom C. Autogenous bone grafting of bone defects adjacent to implants placed into immediate extraction sockets in patient: a prospective study. *Int J Oral Maxillofac Implants* 1994: 9: 389-396.

6. Becker W, Dahlin C, Becker BE, Lekholm U, van Steenberghe D, Higuchi K, Kultje C. The use of e-PTFE barrier membranes for bone promotion around titanium implants placed into extraction sockets: a prospective multicenter study. *Int J Oral Maxillofac Implants* 1994; 9: 31-40.
7. Becker W, Sennerby L. A new era. *Clin Implant Dent Relat Res* 1999; 1: 1.
8. Langer B, Sullivan DY. Osseointegration: its impact on the interrelationship of periodontics and restorative dentistry. Part 3. Periodontal prosthesis redefined. *Int J Periodontics Restorative Dent* 1989; 9: 240-261.
9. Schwartz-Arad D, Chaushu G. The ways and wherefores of immediate placement of implants into fresh extraction sites: a literature review. *J Periodontol.* 1997; 68: 915-923.
10. Werbit MJ, Goldberg PV. The immediate implant: bone preservation and bone regeneration. *Int J Periodontics Restorative Dent.* 1992; 12: 207- 217.
11. Cochran DL, Schenk RK, Lussi A, et al. Bone response to unloaded titanium implants with sand blasted and acid etched surface: a histometric study in the canine mandible. *J Biomed Mater Res.* 1998; 40:1-11.
12. Becker W, Sennerby L, Bedrossian E, Becker BE, Lucchini JP. Implant stability measurements for implants placed at the time of extraction: a cohort, prospective clinical trial. *J Periodontol* 2005; 76: 391-397 12.
13. Becker W, Sennerby L, Bedrossian E, Becker BE, Lucchini JP. Implant stability measurements for implants placed at the time of extraction: a cohort, prospective clinical trial. *J Periodontol* 2005; 76: 391-397.
14. Berlung TM & Lindhe J., Healing around implants placed in bone defects treated with Bio-Oss: an experimental study in the dog. *Clin Oral Implants Res* 1997; 8: 117-124.
15. Cornelini R, Cangini F, Martuscelli G, Wennström J., Deproteinized bovine bone and biodegradable barrier membranes to support healing following immediate placement of transmucosal implants: a short-term controlled clinical trial. *Int J Periodontics Restorative Dent* 2004; 24(6):555-63
16. Dealemans P, Hermanns M, & Godet F., Autologous bone graft to augment the maxillary sinus in conjunction with immediate endosseous implants: a retrospective study up to 5 years. *Int J Periodontics Restorative Dent* 1997; 17: 27-39
17. Hassan K S, Kassim A, & Al Ogaly A., A comparative evaluation of immediate dental implant with autogenous versus synthetic guided bone regeneration. *Oral Surg Oral Med Oral Pathol Oral Radiol Endod* 2008; 106:e8-e15
18. Hassan KS., Autogenous bone graft combined with poly(lactic polyglycolic acid) polymer for treatment of dehiscence around immediate dental implants. *Oral Surg Oral Med Oral Pathol Oral Radiol Endod* 2009; 108: e19-e25.

How to cite this article:

Vijay Ebenezer and Saravanan D. 2017, Comparative Study of Immediate Vs Delayed Placement of Implant A radiographic evaluation of 80 Cases. *Int J Recent Sci Res.* 8(9), pp. 20098-20101. DOI: <http://dx.doi.org/10.24327/ijrsr.2017.0809.0826>
