



ISSN: 0976-3031

Available Online at <http://www.recentscientific.com>

CODEN: IJRSFP (USA)

International Journal of Recent Scientific Research
Vol. 8, Issue, 10, pp. 20498-20504, October, 2017

**International Journal of
Recent Scientific
Research**

DOI: 10.24327/IJRSR

Research Article

HEMIFACIAL ATROPY CORRECTION WITH AUTOLOGOUS FREE FAT TRANSFER- CASE REPORT AND REVIEW OF LITERATURE

Seema Alice Mathew¹, Ravisankar Nutalapati*² and Veerabahu M³

¹Oral and Maxillofacial Surgery, Chennai, Tamil Nadu, India

²Oral and Maxillo Facial Suregry, Andhra Pradesh, India

³Oral and Maxillofacial Surgery Ragas Dental College & Hospital Chennai Tamil Nadu, India

DOI: <http://dx.doi.org/10.24327/ijrsr.2017.0810.0904>

ARTICLE INFO

Article History:

Received 17th July, 2017

Received in revised form 21st

August, 2017

Accepted 05th September, 2017

Published online 28th October, 2017

Key Words:

Hemifacial Atrophy, Lipofilling,
Cosmetic Reconstruction

ABSTRACT

Minimally invasive cosmetic reconstruction of facial deformities has always been a challenge in maxillofacial surgery. Hemifacial atrophy is an autoimmune disorder characterized by progressive degeneration and shrinkage of connective tissues, muscles beneath the skin usually on one side of the face. Autogenous fat transfer to restore the normal facial contour is a minimally invasive technique in comparison to other microvascular reconstructive options. The authors present a case of a 25 year old female patient with Hemifacial atrophy who presented with atrophy of the skin and underlying tissues over the right side upper and lower lip, cheek, angle of mouth and chin with skin hypopigmentation, eyebrow and temporal alopecia. A minimally invasive treatment was planned where abdominal liposuction and lipofilling of the facial defect was undertaken. Overfilling of the defect was done calculating the post operative resorption that can occur. The results were immediate and satisfactory thereby making fat grafting a more promising and minimally invasive cosmetic reconstructive option in hemifacial atrophy cases.

Copyright © Seema Alice Mathew et al, 2017, this is an open-access article distributed under the terms of the Creative Commons Attribution License, which permits unrestricted use, distribution and reproduction in any medium, provided the original work is properly cited.

INTRODUCTION

Progressive facial hemiatrophy is also known as Parry-Romberg syndrome (PRS) is a rare, acquired, neurocutaneous syndrome of unknown etiology which is characterized by a progressive yet self-limited atrophy of fat, skin, connective tissue, muscle, and sometimes bone on one side of the face^{1,2,3,4,5}. The condition was first reported by Parry in 1825 and was later on described as a syndrome by Romberg in 1846^{6,7}. The exact etiology of this disease is unclear, but various theories have been postulated to explain it as autoimmunity, trigeminal theory and so on⁴. It may overlap with a condition called as linear scleroderma- "en coup de sabre" which is characterized by a pathological vertical or diagonal line of cutaneous sclerosis on the forehead⁸. Atrophy is mainly confined to one side of the face and cranium with changes in the eyes (enophthalmos) and hair, but can occasionally involve the neck, limbs on the same side, with various ophthalmological and neurological complications^{9,10,11}. Neurological complications like trigeminal neuralgia, migraine, seizures, epilepsy have also been found to be associated with this condition⁸. Radiographically the teeth on the involved side can appear smaller with short root forms¹².

PRS onset is insidious and usually manifest in the first or second decade of life with skin changes initially resembling scleroderma^{13,14}. The disease process is rapid from two to ten years and then it stabilizes with minimal atrophy in the later years⁴. PRS occurs sporadically with some familial distribution. Female predilection is more commonly seen (3:2)^{2,15,16,17}.

Published trials on the treatment of facial hemiatrophy are limited, however reconstructive options includes autogenous fat transfer, silicon implants, dermis fat graft, pedicle or microvascular flaps, and bone implants. Autogenous free fat transfer is a widely accepted technique for reconstruction of soft tissue defects because of it is biocompatible, natural-looking, versatile, non-immunogenic, inexpensive and easily obtainable with low donor site morbidity¹⁸. The limitations of free fat grafting can be because adipocytes are extremely sensitive to mechanical damage during harvesting and require an excellent vascular bed with even distribution pattern in the recipient site for excellent uptake and adipocyte survival. Fat graft can undergo resorption, replacement with fibrous tissue; oil cyst formation which can be overcome by the use of adipose-

*Corresponding author: **Ravisankar Nutalapati**
Oral and Maxillofacial Surgery, Chennai, Tamil Nadu, India

derived regenerative cell (ADRC) enriched fat grafting techniques.

The authors present a case of a patient with facial hemiatrophy who was successfully treated for correction of the cosmetic deformity with a minimally invasive, satisfactory, simple, safe and easy technique using abdominal liposuction and lipofilling of the facial defect with excellent and immediate cosmetic results.

Case report

A 25-year old female patient reported to the Department of Oral and Maxillofacial Surgery, Ragas Dental College and Hospital, Chennai, India with facial asymmetry clinically presenting with atrophy of the skin and underlying tissues over the upper and lower lip, cheek, angle of mouth and chin with skin hypo-pigmentation, eyebrow and temporal alopecia on the right side of her face (Figure 1a,1b). The asymmetry progressed until the age of 10 years, after which time no changes were seen. Clinical assessment revealed severe loss of subcutaneous fat tissue with moderate skin hypo-pigmentation and minimal bone involvement over the right zygomatic region, cheek, maxilla, mandible and chin region. The etiology of the disease was unknown. The patient's medical and family history was non contributory. The patient visited a local dermatologist and was on long term steroid therapy and methotrexate for the same. Based on the clinical features, a diagnosis of Grade III Parry- Romberg syndrome according to the classification given by Guerrerosantos *et al* (Table 1)¹⁹ with Morphea and Vitiligo vulgaris was made. Radiographically very minimal deficiency or hypoplasia of the zygomatic, maxillary and mandibular bones was inferred (Figure 2). Definitive data on treatment options in Parry- Romberg syndrome are limited, but an attempt to inject autologous fat from the abdomen via the needle liposuction technique was advocated to cosmetically reconstruct the facial defect. The patient was reviewed for a period of six months and no progressive changes were noted and the results were clinically satisfactory.

Surgical method

The procedure was undertaken under general anesthesia, and standard surgical preparation was done with meticulous sterile technique. Markings of the defect site were made to demonstrate areas of defect in the recipient site (Figure 3A). Abdomen was prepared as the donor site for the liposuction technique (Coleman's technique)²⁰. The recipient site is not infiltrated to avoid deformity of the recipient area. The donor site was infiltrated with tumescent injection (mixture of 20ml of lignocain with adrenalin 2%, 0.5cc adrenalin, 0.5cc hylase, 7.5ml sodium bicarbonate in 500ml ringer lactate solution) using a blunt Laminar infiltrator needle attached to the 10-ml syringe. The Coleman microcannula technique was used where a light negative pressure was created by withdrawing the plunger of a 10-ml Luer-Lok syringe which was connected to a 3-mm cannula and was introduced through a small incision in the abdominal site. The cannula was moved mechanically with slight negative pressure and curetting action through the adipose tissue compartment to loosen the fat tissue and collect it into the syringe with minimal mechanical damage (Figure 3B). When filled, the syringe was disconnected from the cannula and the next syringe was connected. This process was

continued till the required quantity of the fat was liposuctioned. The syringes with the collected fat was gently centrifuged manually and were inverted to allow settling of the contents into three layers- upper oil layer, viable adipose fat cells in the middle and lower mixed layer of blood, water and lignocain (Figure 3C). The unwanted first and third layers were removed and syringes with only the fat tissues were readied for lipofilling the recipient defect site (Figure 3D,E).

Stab incisions were placed close to the recipient site below the ear lobule, lip commissure and angle of the mandible depending on the areas to be lipofilled. The fat transfer was done using a blunt end cannula that was used to create a tunnel during its insertion and fat was deposited in evenly spaced small aliquots as it was being withdrawn through the multiple access sites through which the fat cells were allowed to fan out into various tissue depths (Figure 3F). Overcorrection of the defect site was done anticipating the percentage of fat resorption that may take place in the grafted site.

The patient was discharged from the hospital within 24 hours with antibiotics and analgesics for seven days and ice pack application for 2-3 days (Figure 4). Patient was advised to avoid rubbing the face and stay in an air-conditioned environment to maintain fat cell viability and uptake. Review was done after 6 months and results were satisfactory (Figure 5). Re-injection of fat cells would be planned later on after 12 month follow up if required.

DISCUSSION

Correction of severe facial contour abnormalities to restore a harmonious and symmetrical appearance still poses a challenge to maxillofacial and reconstructive surgeons. Autologous fat grafting technique is shown to be beneficial as a cosmetic and reconstructive procedure for volume loss due to disease, trauma, congenital defects, or natural process of aging^{18,21}.

Various free fat grafting procedures are practiced, and it was first introduced in 1893 by Neuber using an open incision technique and was then modified by Bruning in 1911 as an injectable technique^{22,23}. Lexer in 1910 performed fat grafting as an aesthetic surgery and subsequently used it for facial contour reconstruction in Parry-Romberg syndrome²⁴. Eugene Hollander in 1912 achieved natural appearing results for correction of lipoatrophic defects of the face²⁵. Peer (1950, 1956) reported loss of fat tissue due to absorption of fat to as much as 50%^{26,27}, where as Illouz demonstrated 80% resorption of injected fat²⁸. Coleman(1995,1997,2002) started the "atraumatic purified" technique for harvesting more viable adipose tissue with long lasting results, avoiding chopping, washing, manipulation, freezing, high negative pressure during fat extraction and high positive pressure during implantation of fat tissues which was used by the authors in this particular case to achieve increased quantity of viable fat cells for transplantation^{29,20,30}.

Histological studies conducted on transplanted autologous fat transfer suggested that the clinical longevity of fat graft is determined on the degree of augmentation, resulting from the number of viable fat cells and the resulting amount of fibrosis. Anatomic site, mobility, vascularity of the recipient bed, underlying disease and cause, harvesting and reinjection

technique also plays an important role in fat graft survival^{31,32}. Vascularization of fat cells occurs after four days, before which the transplanted fat cells survive by diffusion. Several studies have published reports of permanent fat graft survival, whereas others have shown traumatic fat graft handling to result in partial or complete fat resorption^{31,32}.

Fat grafting is a novel technique for soft tissue enhancement procedures for mild to moderate defects. It can be used instead of other alternative soft tissue reconstruction procedures like dermal fat grafts, local flaps, free tissue transfer, alloplastic implants and injectable fillers. Fat grafting was preferred because it is autologous, minimally invasive with low donor site morbidity, non-carcinogenic, no immune response, readily available donor source, minimal scarring at the recipient, with excellent immediate results^{33,34}.

Alloplastic filler materials like polytetrafluoroethylene (PTFE) of polymethylmethacrylate (PMMA) can be used to reconstruct soft tissue defects but it is impossible to extract out these alloplastic materials in spherical form in case if an undesirable immune response reaction or infection occurs³⁵. Human face consistently undergoes changes due to the aging process, and these implants are more likely to be detected through the thin skin. Long term effects of injectable bovine collagen depend on the underlying cause, location of injection of the implant and results last for 6 to 24 months^{36,37}. Shortcomings of alloplastic implants are that they have suboptimal texture, are expensive, scarce and can be poorly tolerated by the host. Autologous fat even though is considered as a non-permanent reconstructive option, with all most similar longevity as other filler materials, but fat grafts still are advantageous because of its autologous, non-immunogenic properties and the incidence of infection is very minimal in fat grafting cases^{38,39,40}.

Free dermal fat graft (FDFG) for reconstruction of facial contour defects was first reported in 1914 by Lexer to repair the nasal tip, alar and auricular defects; and later in 1920 Eitner used it for reconstruction of post-surgical malar depression^{41,42}. The use of free dermal graft is indicated in Grade III Parry Romberg cases according to Albadawy *et al*, where large volume loss defects have to be replaced providing a smooth facial contour, but the limitation of using free dermal graft is the additional scar in the donor site and the unpredictable volume loss after implantation due to fat resorption which accounts to 70-100%⁴³. FDFG of more than 1-1.5cm thickness undergoes drastic resorption due to its failure to adequately revascularize to the subdermal plexus of the underlying recipient site, thereby limiting the use of large bulky free dermal fat tissue^{44,45,46,47,48}.

Free flaps have been considered as the gold standard for reconstruction of large facial defects due to Parry Romberg's syndrome^{49,50}. Commonly used free flaps include- pedicled submental flap, omental flap, scapular or parascapular flap, groin flap, and anterolateral thigh flap^{51,52,53,54,55,56,57}. Long term follow up demonstrated that free flaps were unpredictable than fat graft due to the gravitational force, which required flap resuspension later on as an additional surgical procedure. Free flaps also demonstrated colour mismatch and disproportional volume increase in relation to the body's fat, as the grafted fat has a tendency to increase as the body's weight increases, for which patients may require flap recontouring and resuspension.

Results after fat grafting are assessed by observation, examination with palpation and photographs. More precise objective methods includes- laser scanners, three dimensional photography, and magnetic resonance imaging^{58,59,60}. Long term outcomes of fat grafting showed that 45% of the transplanted was retained after 1year⁶¹. Studies have reported 30-70% resorption^{58,62}, and this necessitates the need for overcorrection of the volume deficiency by 20-30 %⁵⁸. Fat grafting using the injection technique can be done as a minimally invasive day care procedure to produce immediate results; and overcorrection of the defect is also advisable considering the 30-40% resorption rate after fat uptake. Re-injection after 6 months can be done to correct minor defects as a result of fat resorption, which is easily accepted by the patient due to the less invasive, cost-effective and safety of the procedure.

Fat grafting can be associated with some amount of swelling, redness, minimal fat resorption and moderate bruising. Some of the less common complications include hematoma, fibrosis, oil cysts, cellulitis responsive to antibiotics, and calcifications. Rarely complications like fat embolism in the retinal or cerebral arteries, aphasia, hemiparesis and loss of vision is encountered. Hypertrophy of the grafted fat may be seen when abdominal fat is grafted to the face⁶³.

Albadawy *et al* proposed a treatment protocol as per the Guerrerosantos *et al* classification (Table 1) for Parry Romberg syndrome depending on the amount of facial depression concluding autologous fat transplantation for Grade I and II atrophy cases, dermal fat grafting for Grade III cases. Grade IV facial atrophy cases may need dermal fat grafting, galeal flap, free flaps or cartilage and bone grafts in addition to fat grafting^{19,64}. It is upto the maxillofacial and reconstructive surgeon's discretion to choose the most appropriate surgical management for correction of facial deformities as a result of facial hemiatrophy.

Despite the shortcoming and lack of sufficient literature on fat grafting techniques, research findings suggest that adipocyte derived stem cell therapy will be the promising clinical tool in the future. Well controlled and evidence based clinical trials will draw the distinguishing line between fact and fiction regarding stem cell therapies and fat grafting.

In conclusion, the authors advocate panfacial volumisation using autogenous fat injections as a novel technique for reconstruction of minor defects in Parry-Romberg syndrome as a safe, minimally invasive and easy technique that can produce immediate results with minimal or no morbidity, with excellent patient compliance and satisfaction for replacing and restoring volume and contour defects due facial hemiatrophy.

Table 1 Guerrerosantos *et al* classification for Parry –Romberg syndrome¹⁹.

Grade I	Very mild depression in the face, occurring in acute Parry- Romberg cases
Grade II	Reduced thickness of soft tissues of the face with no cartilage or bone involvement
Grade III	Soft tissue of the face is thinner than grade II with initial bone and cartilage involvement.
Grade IV	Severe type of facial depression and the skin is very close to the bone, with bone involvement.

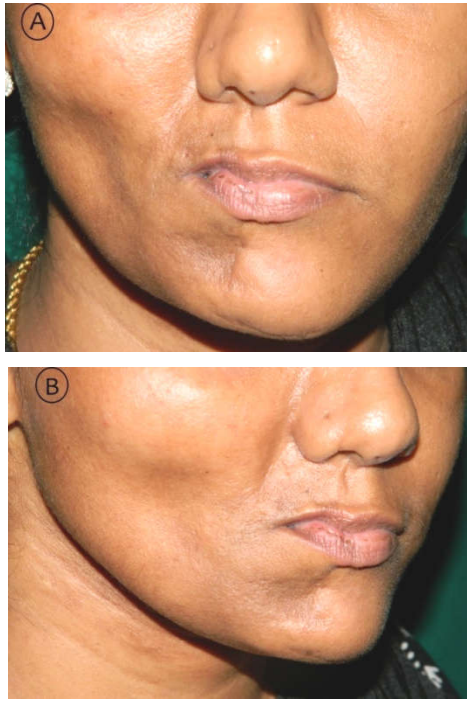

Figure 1 A, B Frontal and lateral view of the patient with Parry-Romberg syndrome

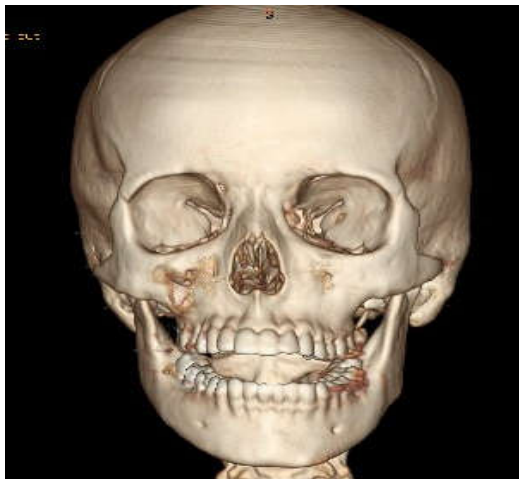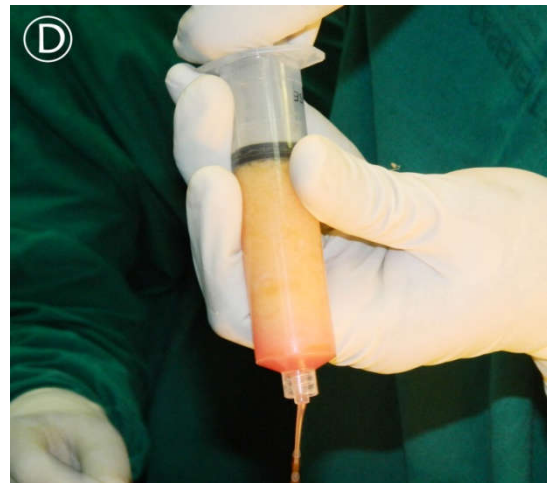
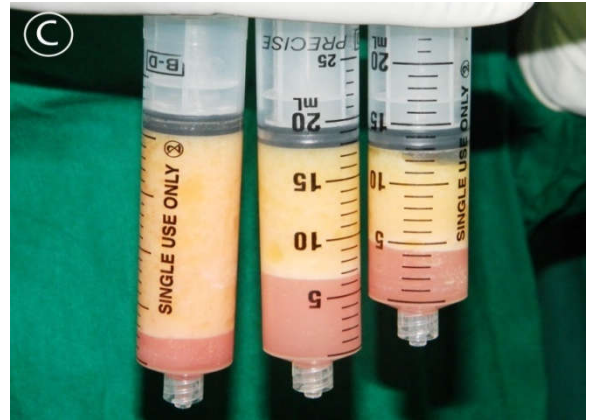

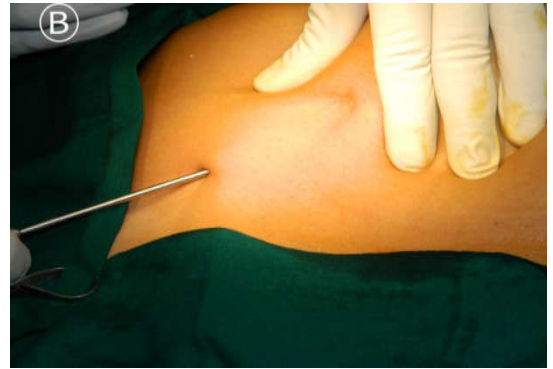
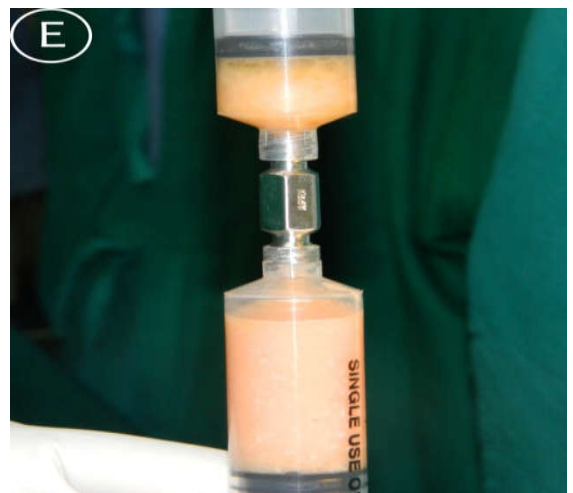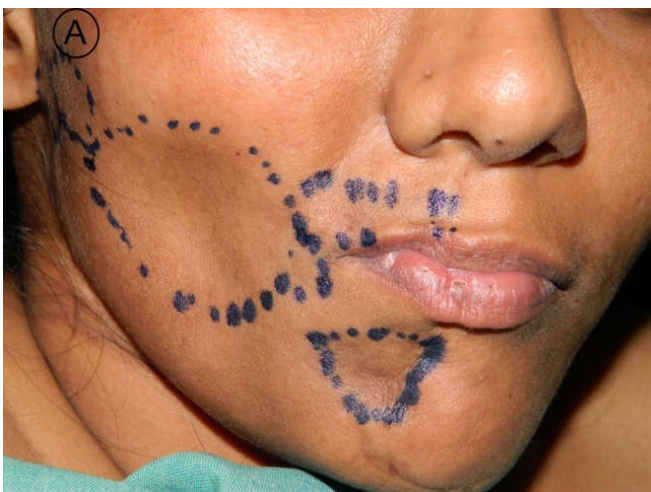Figure 2 3D reconstruction image showing minimal bony involvement



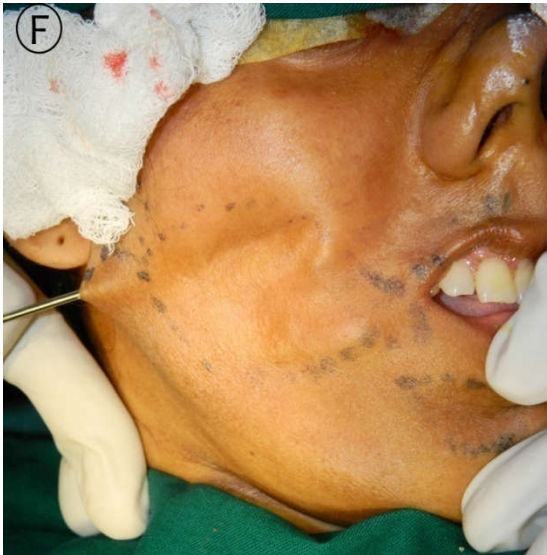

Figure 3 A Demonstrates the markings before fat transplantation. B, Fat graft harvesting from the abdomen. C, Sedimentation of fat into layers (oil, viable fat cells, and RBC's with water and lignocain). D, Removal of the lower layer of RBC's, water and lignocain layer. E, Separation and collection of viable fat cells into the syringe for fat delivery. F, Injection into the recipient site.

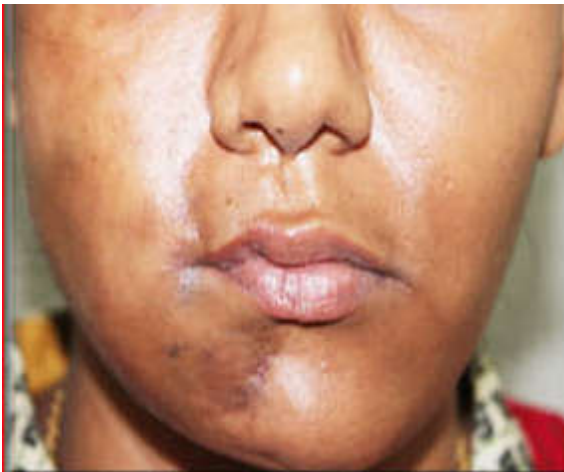

Figure 4 Immediate post-operative results

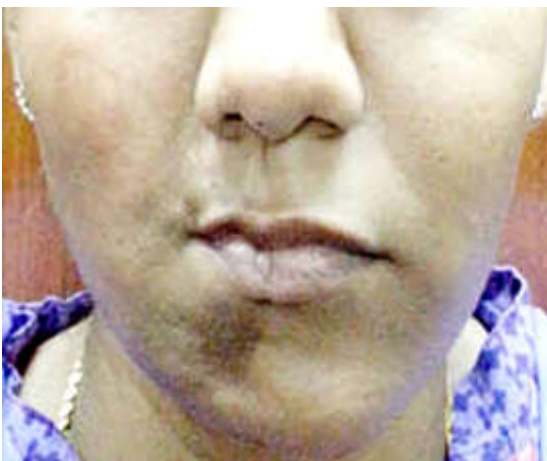

Figure 5 Post-operative photograph after 6 months

Declarations

Ethics approval and consent to participate: Ethical approval for the publication of a case report is not a requirement of affiliated institutions of any authors unless the patients' identity

had been exposed in the report. Therefore the ethical approval has not been obtained for this presentation. But informed consent of patient for participation, photographs without exposing identity and all necessary details and was obtained.

Consent for publication: Written informed consent was obtained from the patient for publication of this case report and any accompanying images. A copy of the written consent is available for review by the Editor-in-Chief of this journal.

Availability of data and material: The datasets generated during the current case report [Including clinical records, Surgical records, Pictures, and investigations] are available in the repository of Ragas dental college and hospital Chennai, Tamil Nadu, India.

Competing interests: The authors certify that patients consent for participation and publication was obtained prior reporting and they have NO affiliations with or involvement in any organization or entity with any financial interest [such as honoraria; educational grants; participation in speakers' bureaus; membership, employment, consultancies, stock ownership, or other equity interest; and expert testimony or patent-licensing arrangements], or non-financial interest [such as personal or professional relationships, affiliations, knowledge or beliefs] in the subject matter or materials discussed in this manuscript. The authors declare that there is no conflict of interest regarding the publication of this paper.

Funding: Not applicable

Acknowledgment

Authors would like to acknowledge the guardians of patient and staff of Oral and maxillofacial surgery unit and Department of oral and maxillofacial surgery, Ragas Dental College and hospital, and Dr.Damodar Raj MS, MCh, for their assistance in managing the patient and for comments that greatly improved the manuscript.

Authors Contributions

Each author of this article contributed in different ways. The idea of this case report was Seema's and Ravisankar. Further he has done the restructuring and final editing. Surgical management of this case was done by Dr. M.Veerabahu and Seema. Further they have contributed in compiling the sections related to surgical aspects in this article. Seema and Ravisankar were the major contributors in thorough literature review and writing the manuscript. All authors read and approved the final manuscript.

References

1. Terenzi V, Leonardi A, Covelli E, *et al.* Parry-Romberg syndrome. *Plast Reconstr Surg* 116:97, 2005.
2. Rogers BO. Progressive facial hemiatrophy: Romberg's disease: a review of 772 cases. *Proc 3d Int Cong Plast Surg. Excerpta Medica ICS* 66:681, 1964.
3. Padmini P, Singhi PD. Facial hemiatrophy. *Indian Pediatr* 29:505, 1992.
4. Gulati S, Jain V, Garg G. Parry Romberg syndrome. *Indian J Pediatr* 73:448, 2006.
5. Rangare AL, Babu SG, Thomas PS, Shetty SR. Parry Romberg syndrome: a rare case report. *J Oral Maxillofac Res* 2:5, 2011.

6. Parry CH. Collection from the Unpublished Medical Writings of Late Calet Hillier Parry. London, England: Underwoods. 1825: pp 478.
7. Romberg MH. Trophoneurosen Kliniske Ergenbrisse. Berlin, Germanys: Forster. 1846: pp 75.
8. Stone J. Parry Romberg syndrome. *Practical Neurology*. 6:185, 2006.
9. Sagild JC, Alving J. Hemiplegic migraine and progressive hemifacial atrophy. *Ann Neurol*. 17:620, 1985.
10. Chbicheb M, Gelot A, Rivier F, Roubertie A, Humbert claud V, Coubes P, Echenne B. Parry Romberg's syndrome and epilepsy. *Rev Neurol (Paris)*. 161:92, 2005.
11. Haldar A, Mukherjee A. Parry Romberg's disease with intractable partial epilepsy. *Neurol India* 55:160, 2007.
12. Pinheiro TP, Silva CC, Silveira CS, Botelho PC, Pinheiro MG, Pinheiro Jde J. Progressive Hemifacial Atrophy- case report. *Med Oral Patol Oral Cir Bucal*. 11:112,2006.
13. Miller MT, Spencer MA. Progressive facial Hemiatrophy. Anatural history study. *Trans Am Ophthalmol Soc*. 93:203, 1995.
14. Mendonca J, Viana SL, Freitas F, Lima G. Late- onset progressive facial hemiatrophy (Parry- Romberg syndrome). *J Postgrad Med* 51:135, 2005.
15. Rogers BO: Embryology of the face and introduction to craniofacial anomalies. In: Converse JM editor. *Reconstructive Plastic Surgery*, 2nd ed. WB Saunders, Philadelphia. 1977: pp 2296.
16. Hickman JW, Sheils WS. Progressive facial hemiatrophy. Report of a case with marked homolateral involvement. *Arch Intern Med*. 113:716, 1964.
17. Witkop CJ. Genetic disease of the oral cavity: In Teiecke RW editor. New York, Mcgrant Hill 1965.
18. Tabit CJ, Slack GC, Fan K, Wan DC, Bradley JP. Fat grafting versus Adipose- derived Stem Cell Therapy: Distinguishing Indications, Techniques, and Outcomes. *Aesth Plast Surg* 36:704, 2012.
19. Guerrerrosantos J, guerrerrosantos F, and Orozco J: Classification and treatment of facial tissue atrophy in Parry-Romberg Disease. *Aesth Plast Surg* 31:424, 2007.
20. Coleman SR. Structural fat grafts: the ideal filler? *Clin Plast Surg* 28:111, 2001.
21. Gutierrez C, Hayakawa V, Franco A, Reyes L. Lipoinyeccion para reconstruccion del contornofacial en S.de Parry Romberg, esclerodermia y secuelas de trauma. Una alternative practica utilizando canulas para bloquo peridural. *Rev Cir Plast* 17:168, 2007.
22. Neuber F. Fettrasplantation. Bericht uber die Verhandlungen der DtGesf Chir Zbl Chir 22:66, 1893.
23. Bruning P. Cited by Broeckaert TJ. Contribution a l'etude des greffes greffes adipeuses. *Bull Acad R Med Belgique* 28:440, 1919.
24. Lexer E. Freie Fettgewebstrasplantation. Dtsch Med Wochenschr 36:46, 1910.
25. Brucker M, Sati S, Spangenberg A, Weinzweig J. Long- term fate of transplanted autologous fat in a novel rabbit facial model. *Plast Reconstr Surg* 122:749, 2008.
26. Peer, LA. Cell survival theory versus replacement theory. *Plast Reconstr Surg* 16:161, 1955.
27. Peer, LA. The neglected free fat graft its behavior and clinical use. *Am J Surg* 92:40, 1956.
28. Illouz, YG. Fat Injection: A four year clinical trial in lipoplasty, In: the theory and practice of blunt suction lipectomy, Brown. 1990: pp 148.
29. Coleman, SR. Long-term survival of fat transplants: controlled demonstrations. *Aesthetic Plast Surg* 19:421, 1995.
30. Coleman, SR. Hand rejuvenation with structural fat grafting. *Plast Reconstr Surg* 110:1731, 2002.
31. Sommer. B, Sattler.G. Current concepts of fat graft survival: Histology of aspirated adipose tissue and review of the literature. *Dermatol Surg* 26:1159, 2000.
32. Smith .J, Al-AMRI. M, Dorairaj. P, Sniderman.A. The adipocyte life cycle hypothesis. *Clinical science* 110:1, 2006.
33. Sterodimas A, Huanquipaco JC, de Souza Filhos et al. Autologous fat transplantation for the treatment of Parry-Romberg syndrome. *J Plast Reconstr Aesthet Surg* 62:424, 2009.
34. Koh KS, Oh TS, Kim H, et al. clinical application of human adipose tissue- derived mesenchymal stem cells in progressive hemifacial atrophy (Parry- Romberg disease) with microfat grafting techniques using 3- dimensional computed tomography and 3- dimensional camera. *Ann Plast Surg* 69:331, 2012.
35. Sommer B, Sattler G. Lipogranulom nach implantierten Acryl- Perlen (PMMA). In: Konz B, Worle B, Sander CA, eds. *Asthetische und Korrektive Dermatologie*. Berlin; Blackwell 1999: pp 203.
36. Drake LA, Dinehart SM, Farmer ER, et al. Guidelines of care for soft tissue augmentation: collagen implants. *J AM Acad Dermatol* 34: 698, 1996.
37. Dzubow LM, Goldman G. Introduction to soft tissue augmentation: a historical perspective In: Klein AW, ed. *Tissue Augmentation in Clinical Practice*. New Yprk: Marcel Dekker, 1998: pp 1
38. Hanke CW, Coleman WP III. Dermal filler substances. In: Coleman WP III, Alt TH, Asken S, eds. *Cosmetic Surgery of the skin*, 2nd ed. St. Louis: Mosby. 1997: pp 217.
39. Klein AW. Injectable bovine collagen. In: Klein ALO ed. *Tissue Augmentation in Clinical Practice*. New York: Marcel Dekker, 1998: pp 125.
40. Jackson IT, Grothaus P, Ryan JM, Fisher J. Treatment options in Hemifacial Atrophy. *Eur J Plast Surg* 9:22, 1986.
41. Lexer. E. Free transplantation. *Ann Surg* 60:166, 1914.
42. Eitner E. Cited by: Thomson N. The Subcutaneous Dermis Graft: a clinical and historic study in man. *Plast Reconstr Surg* 26:1, 1960.
43. Conley JJ, Clairmont AA. Dermal- fat-fascia grafts. *Otolaryngol Head Neck Surg* 86:641, 1978.
44. Nosan DK, Ochi JW, Davidson TM. Preservation of facial contour during parotidectomy. *Otolaryngol Head Neck Surg* 104:293, 1991.
45. Leaf N, Zarem HA. Correction of contour defects of the face with dermal dermal-fat grafts. *Arch Surg* 105:715, 1972.

46. Hurwitz PJ, Sarel R. Facial reconstruction in partial lipodystrophy. *Ann Plast Surg* 8:253, 1982.
47. Davis R.E, Guida RA, Cook TA. Autologous Free Dermal Fat Graft. *Arch Otolaryngol Head Neck Surg* 121:95, 1995.
48. Stark RB. Free transplants. Plastic Surgery. New York, NY: Harper and Row publishers Inc; Chap 5:1962.
49. Inigo F, Rojo P, Ysunza A. aesthetic treatment of Romberg's disease: experience with 35 cases. *Br J Plast Surg* 46:194, 1993.
50. Agostini T, Agostini V. Adipofascialanterolateral thigh free flap for hemifacial atrophy. *Acta Otorhinolaryngol Ital* 29:103, 2009.
51. Wang X, Qiao Q, Liu Z, Zhao R, Zhang H, Yang Y, et al. free anterolateral thigh adipofascial flap for hemifascial atrophy. *Ann Plast Surg* 55:617, 2005.
52. Asai S, Kamei Y, Nishibori K, Kotoh T, Torii S. Reconstruction of Romberg disease defects by omental flap. *Ann Plast Surg* 57:154, 2006.
53. Vaienti L, Soresina M, Menozzi A. parascapular free flap and fat grafts: combined surgical methods in morphological restoration of hemifacial progressive atrophy. *Plast Reconstr Surg* 116:699, 2005.
54. Ugurlu K, Ozcelik D, Hacikerim S, Karasoy A, Bas L. the combined use of flaps based on subscapularvascular system for unilateral facial deformities. *Plast Reconstr Surg* 106:1079, 2000.
55. Upton J, Albin RE, Mulliken JB, Murray JE. The use of scapular and parascapular flaps for cheek reconstruction. *Plast Reconstr Surg* 90:959, 1992.
56. Cooper TM, Lewis N, Baldwin MA. Free groin flap revisited. *Plast Reconstr Surg* 103:918, 1999.
57. Spyriounis PK. The extended approach to the vascular pedicle of the anterolateral thigh perforator flap: anatomical and clinical study. *Plast Reconstr Surg* 117:997, 2006.
58. Kaufman MR, Miller TA, Huang C, Roostaecian J, Wasson KL, Ashley RK et al. Autologous fat transfer for fascial recontouring: is there science behind the art? *Plast Reconstr Surg* 119:2287, 2007.
59. Hoehnke C, Eder M, Papadopulos NA, Zimmermann A, Brockmann G, Biemer E, Kovacs L. *JPRASurg* 60:1138, 2007.
60. Kim SS, Kawamoto HK, Kohan E, Bradley JP. Reconstruction of irradiated orbit with autogenous fat grafting for improved ocular implant. *Plast Reconstr Surg* 126:213, 2010.
61. Peer L, loss of weight and volume in human fat grafts. *Plast Reconstr Surg* 5:217, 1950.
62. Kurita M, Malsumoto D, Shigeura T, Sato K, Gonda K, Harii K et al. Influences of centrifugation for lipotransfer and cell isolation. *Plast Reconstr Surg* 121:1033, 2008.
63. Zhu M, Zhou Z, Chen Y, Schreiber R, Ransom JT, Fraser JK et al. supplementation of fat grafts with adipose-derived regenerative cells improves long-term graft retention. *Ann Plast Surg* 64:222, 2010.
64. Albadawy MA, Mohamed AE, El-Menawi HM. Fat and Dermo-fat grafting as a safe and simple solution for management of facial atrophy. *Egypt J Plast Reconstr Surg* 35:121, 2011.

How to cite this article:

Seema Alice Mathew et al.2017, Hemifacial Atropy Correction With Autologous Free Fat Transfer- Case Report And Review of Literature. *Int J Recent Sci Res.* 8(10), pp. 20498-20504. DOI: <http://dx.doi.org/10.24327/ijrsr.2017.0810.0904>
