



ISSN: 0976-3031

Available Online at <http://www.recentscientific.com>

CODEN: IJRSFP (USA)

International Journal of Recent Scientific Research
Vol. 8, Issue, 11, pp. 21443-21448, November, 2017

**International Journal of
Recent Scientific
Research**

DOI: 10.24327/IJRSR

Research Article

EVALUATION OF HEALING ACTIVITY OF CHITOSAN GEL ASSOCIATED WITH THE LIGHT EMISSION DIODE

Renata Oliveira Moura*¹., Rafael Marques Silva²., Maria Ester Ibiapina Mendes de Carvalho³., Carlos José de Lima⁴., Sarah Nilkece Mesquita Araújo¹ and Lívio César Cunha Nunes¹

¹Federal University of Piauí-UFPI

²Universidade de Brasília-UnB

³Universidade Estadual do Piauí-UESPI

⁴University of Paraíba Valley-UNIVAP

DOI: <http://dx.doi.org/10.24327/ijrsr.2017.0811.1075>

ARTICLE INFO

Article History:

Received 17th August, 2017

Received in revised form 21st

September, 2017

Accepted 05th October, 2017

Published online 28th November, 2017

Key Words:

Descriptors: Biopolymer; Phototherapy;
Wound Healing.

ABSTRACT

Objective: To evaluate the healing activity of the chitosan gel associated with light emitting diode in induced skin lesions in albino rats. **Methods:** Experimental study was carried out on the induction of cutaneous wounds in 60 Wistar albino rats (300g) distributed randomly in six groups of 10 animals, according to the type of treatment proposed, namely: control group, positive group, light emitting diode, chitosan, light emission by diode / chitosan and chitosan / light emission by diode. Wound healing was evaluated by histological, by caliper measurement, photography and analysis of inflammatory parameters of the lesions. **Results:** The combined action of light emission by diode and chitosan, regardless of the order of application, did not show any increase in the tissue healing process when compared to the other treatment groups, surpassing only the control group. **Conclusions:** Further studies of this nature are necessary to evaluate the interaction between these two treatment methods in order to contribute to the evolution of current healing methods.

Copyright © Renata Oliveira Moura *et al*, 2017, this is an open-access article distributed under the terms of the Creative Commons Attribution License, which permits unrestricted use, distribution and reproduction in any medium, provided the original work is properly cited.

INTRODUCTION

The healing process of the injured skin is a natural phenomenon of angiogenesis and reorganization of connective tissue that involves physiological and biochemical factors that act harmoniously to promote the tissue restoration, involving phases that overlap in time and include inflammation, proliferation and tissue remodeling⁽¹⁻³⁾.

The pharmaceutical industry is interested in improving the healing time with the development of new treatments, substances or protocols, which can provide an acceleration of the tissue repair, preventing complications. In this field the studies advance in the research of natural resources, because they present economic advantages and few side effects, such as chitosan, and non-drug therapies, which exert their action through physical properties, such as phototherapy.^(1,4-5)

Chitosan, a natural polysaccharide derived from chitin, obtained through the carapace of crustaceans, has received much attention as a biomaterial because of its excellent biocompatibility and healing action⁽⁶⁾. Research on animals have shown the efficacy of that substance in accelerating tissue

repair, showing its antibacterial and fungicidal characteristics, adding to it the advantage of low cost, natural origin and be simple to obtain. There are reports on the effects of chitosan in the injured tissue mentioning their macrophage activation capacity, stimulation of fibroblast proliferation and collagen and granulation tissue⁽⁷⁻⁸⁾. It is also observed that stimulation occurs for neutrophil migration and reduction of inflammation time⁽⁹⁻¹⁰⁾ providing a more uniform scar formation, with a lower degree of fibroplasty⁽¹¹⁾.

Phototherapy, in turn, is a treatment modality that encompasses a series of resources based on the effects that the incidence of light causes on biological tissues. One such feature is the LED (Light Emitting Diode or LED), which has effects on healing as deposition of collagen fibers, reducing the number of inflammatory cells in the early phase of wound healing,⁽¹²⁻¹³⁾ acceleration of tissue repair and obtaining scar aesthetically satisfactory⁽¹⁴⁻¹⁵⁾. Studies in rats obtained results that allowed to conclude the light action in the stimulation of the transition from the inflammatory phase of cicatrization to the proliferative and remodeling phase, modifying the leukocyte

*Corresponding author: Renata Oliveira Moura
Federal University of Piauí-UFPI

activity in a dose-dependent manner, detecting the significant increase of the natural process of wound healing⁽¹⁶⁻¹⁷⁾.

This work is justified by the possibility of investigating the action of these two therapies together in the repair of tissue damage, considering the relevance of the issue and the scarcity of studies that address this association. For this, the following guiding question was raised: Are the healing effects of chitosan gel and LED enhanced when these modalities are associated in the treatment of cutaneous lesions? The objective of this study was to evaluate the cicatrizing activity of the chitosan gel associated with LED in cutaneous lesions induced in albino rats.

METHODS

An experimental study was carried out on 60 male Wistar rats (*Rattus norvegicus*), male adults aged 2-4 months, with body mass around 300g. The animals were kept in the animal house of the Center for Agricultural Sciences (CCA) of the Federal University of Piauí (UFPI) in large cages (five animals per cage), fed standard chow with free access to water. Each cage was identified with tags and animals with markings on the tail. The animals were randomly divided into six distinct groups of 10 specimens, according to specific treatment, namely: Control group (did not receive treatment); Chitosan group (administration of the chitosan gel covering the wound completely); LED group (red LED application, $\lambda = 640$ nm, for 22 seconds at a distance of 0.5cm from the wound. Calculation of the application time was done using the formula: $t = E / P$; namely $E =$ energy in Joule, $P =$ power in mW and $t =$ time in seconds per cm^2 . With the power of the device 90 mw and the energy 4J, then the application time is 22 seconds); Chitosan and LED group (administration of the chitosan gel covering the wound totally followed by LED application for 20 seconds at a distance of 0.5cm from the wound); LED and chitosan group (application of LED for 20 seconds at a distance of 0.5cm from the wound followed by administration of the chitosan gel covering the wound totally); Positive Group (application of gel commercialized in the market, *pielsana*, covering the whole bed of the wound).

The animals were known to be anesthetized using dissociative anesthesia with ketamine (Ketalar) and xylazine (Rompun) (50mg / kg and 8mg / kg, respectively), associated in the same syringe and applied intraperitoneally, producing, then cutaneous wounds in the dorsal region by the surgical method. The demarcation area of skin by tape adhesion in the size of 1.0 cm^2 was performed, followed by excision of the skin flap⁽¹⁸⁾. Once every 24 hours the animals received the treatment according to the group to which they belonged.

Before the daily application of the treatment, the wounds of each animal were evaluated with three instruments in different periodicities: photograph of the lesion (every 48 hours); caliper (measurement of wound size every 72 hours) and table with macroscopic parameters of inflammation, with the following variables: presence of crust, exudate, hyperemia and pus (every 24 hours). Two animals from each group were euthanized on days 2, 5, 12 and 17, with thiopental sodium overdose (50 mg / kg) and epithelial tissue sample collection for histological analysis, closing the study with 21 days of treatment.

The data were organized into Microsoft Office Excel 2007 spreadsheets for the construction of tables and then transferred to the statistical program Graph Pad Prism 5.1, in which the Two-way ANOVA test was applied to evaluate the interaction of the different treatments applied in the moments of measurements, 95% CI and significance $p < 0.05$. The Statistical Package for Social Science for Windows (SPSS) 17.0 was used to evaluate the correlation with the qualitative percentage of the evaluations, applying the Spearman nonparametric correlation test, also with significance at $p < 0.05$.

The study was approved by the Committee of Ethics in Experimentation with Animals (CEEA) under the number 0106/12. All procedures were carried out in accordance with the "Ethical Principles of Animal Experimentation", as provided by the National Council for the Control of Animal Experimentation (CONCEA).

RESULTS

In the macroscopic evaluation of cutaneous lesion size, there was no statistical difference between the treatments ($p = 0.3416$), but there was a difference ($p < 0.05$) between the negative control group and the others, showing the effectiveness of the treatments in the acceleration healing (Figure 1).

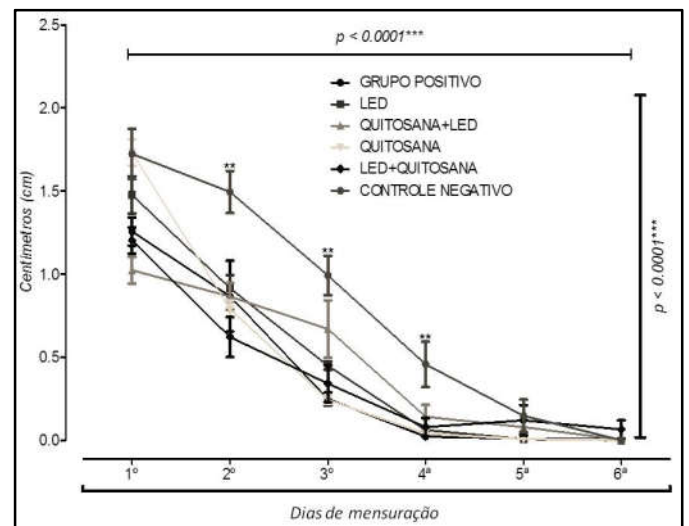


Figure 1 Relation between the size of cutaneous lesions induced in rats, according to treatment with chitosan gel and isolated and / or associated LEDs. Teresina, 2014.

Regarding the daily evaluations of the healing parameters, there were only statistical differences in the variables exudate ($p = 0.003$) and crust ($p < 0.001$). The groups with better evaluation were the LED group and chitosan group, that is, the non-associated groups.

The histological slides were analyzed and the most relevant data for this process were classified according to the days of collecting material: second, fifth, twelfth and seventeenth day of the experiment.

On the second day of the experiment (Figure 02) only the LED group showed moderate proliferation of fibroblasts, absent in the other groups. The absence of edema was observed only in the negative and chitosan groups. All groups revealed presence

of neutrophils, macrophages and inflammatory exudate with predominance of polymorphonuclear (PMN).

In the collection performed on the fifth day of the experiment, it was observed that the groups began to show proliferation of fibroblasts, an activity that was already intensified in the LED group from the second day of treatment.

On the 12th day of treatment of the wounds, the third collection was made. The negative group revealed a discrete lymphocytic infiltrate and well preserved keratinized squamous epithelium. In chitosan group observed intense angiogenesis and proliferation of fibroblasts, the presence of moderate inflammatory focus with a predominance of lymphocytes and mild edema. The LED group demonstrated significant proliferation of fibroblasts and angiogenesis without congestion or edema.

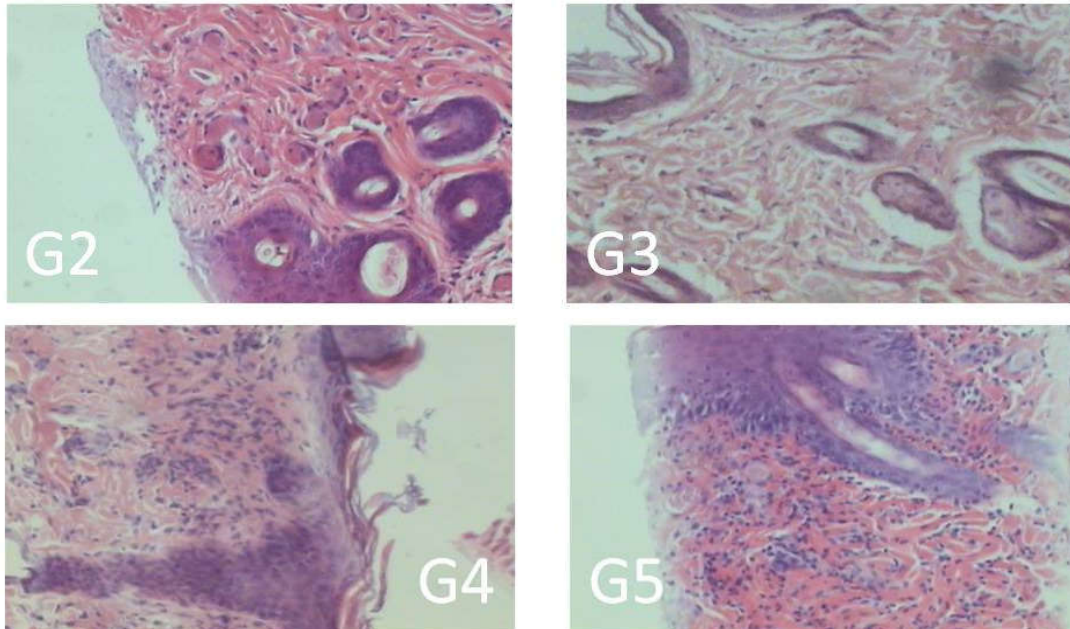


Figure 2 Histological photomicrographs of the cutaneous lesions induced in rats on the second postoperative day according to the types of treatment implemented: G2- chitosan group, G3- LED group, G4- chitosan / LED group, G5- LED group / chitosan and G6- positive group. Teresina-PI, Brazil 2014.

With the exception of the negative group, it was possible to analyze the presence of discrete angiogenesis, more evident in the LED and chitosan / LED group. Inflammatory infiltrates were still present in all groups, but less intensely in the LED group and chitosan group.

The chitosan / LED group presented a discrete inflammatory infiltrate with the presence of lymphocytes, edema and an intense proliferation of fibroblasts in the subepithelial region. In the LED / chitosan group can be seen histological specimens with structural features similar to that previously mentioned but with foci of lymphocytic infiltration of subepithelial moderate

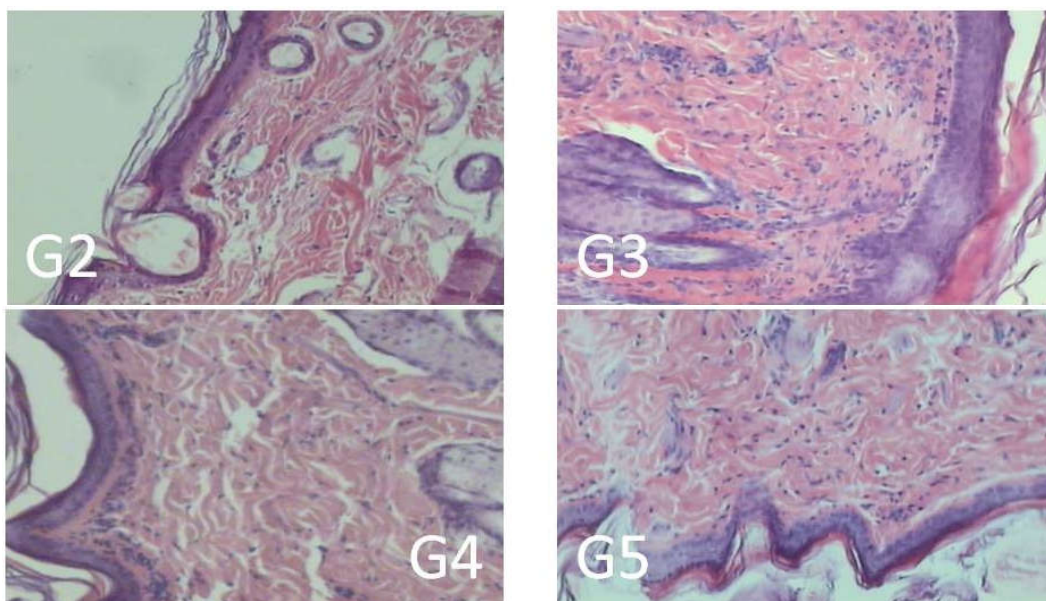


Figure 3 Histological photomicrographs of the cutaneous lesions induced in rats on the seventeenth postoperative day, according to the types of treatments implemented: G2- chitosan group, G3- LED group, G4- chitosan / LED group, G5- LED group / chitosan and G6- positive group. Teresina-PI, Brazil 2014.

in nature. The positive group showed intact epithelium with moderate inflammatory infiltrate with predominance of lymphocytes, absence of congestion and edema with great proliferation of fibroblasts and angiogenesis.

The last collection of histological material was performed on the 17th day of treatment (Figure 3). In this collection, the negative group presented ulcerated area reepithelialization with intense proliferation of fibroblasts, angiogenesis and a discrete focus of lymphocytic infiltrate. The chitosan group had unchanged epithelium (keratinized stratified squamous epithelium), congestion or edema, but with an intense proliferation of fibroblasts and lymphocytic infiltrate. In the LED group was observed intense proliferation of fibroblasts, mild lymphocytic infiltration, and dense connective non-patterned uniform without congestion or edema. Clear angiogenesis was observed in the subepidermal region. In the chitosan / LED group we observed intense proliferation of fibroblasts, moderate subepidermal lymphocytic infiltrate and moderate angiogenesis. The LED / chitosan group showed very characteristic keratinized stratified epithelium (without structural alterations); unmodulated dense connective tissue with moderate fibroblast presence and intense angiogenesis. Positive group revealed skin without structural alterations and stratified keratinized squamous epithelium without histopathological changes.

Macroscopically analyzing the final scar of the lesions at the end of the experiment, we can observe the formation of an aesthetically scarier and uniform scar in the chitosan / LED group and with higher hair growth, as shown in Figure 4.

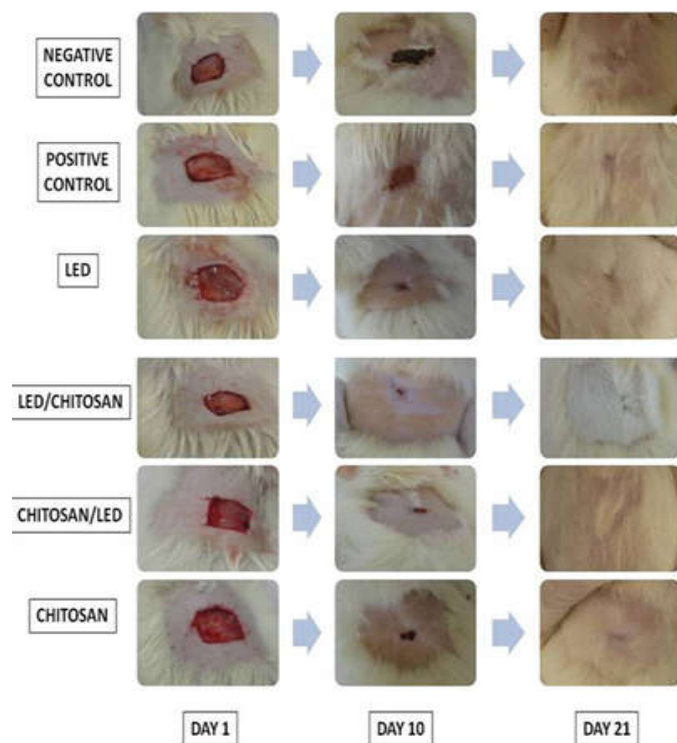


Figure 4 Photographs of cutaneous lesions induced in rats on the first, tenth and twenty-first postoperative days, according to the types of treatment implemented, respectively: G1-negative groups, G6- positive group, G3- LED group, G5- LED group / chitosan, G4- chitosan group / LED and G2- chitosan group. Teresina-PI, Brazil 2014.

DISCUSSION

The use of LED and chitosan for wound healing has been reported and scientifically proven in isolation, but no study has used these two methods in an associated way. The actions of chitosan in tissue repair are reported in all stages of healing, with antimicrobial, hemostatic and cellular activation actions (macrophages and fibroblasts, for example) (19). LED also has its proven efficacy in all phases of tissue repair, stimulating the proliferation of fibroblasts, collagen fibers and reducing the number of inflammatory cells, as well as increased angiogenesis (12).

Macroscopically, the healing process was monitored daily at the time of treatment application, based on researched authors⁽²⁰⁻²¹⁾ documenting the staging of wounds through photography, measurement of wound size and assessment of healing aspects. The results did not show superiority of the combined treatment, highlighting only the healing effect of LED and chitosan in isolation, as evidenced by other studies⁽²²⁾ that confirmed the healing action of chitosan by its application in cutaneous wounds of rats and preserving the closure of wound in 9 days. Researches involving tissue repair^(12,23-24) studied the application of LED in healing, observing a total reepithelialization and evidencing the satisfactory action of LED in the tissue repair in their studies.

The evolution of cicatrization through histological analysis showed that from the second day of treatment the LED group (G3) had already demonstrated the presence of fibroblasts, whereas the other groups presented with cellular infiltrates, neutrophils and lymphocytes with discrete edema characteristic of the first stage of healing, the inflammatory phase. Fibroblasts appeared in the other groups only after the fifth day of treatment, with the intense angiogenesis of the LED (G3) and chitosan and LED (G4) groups, characterizing the second stage of cicatrization, proliferative. On the 12th day of treatment, the intense angiogenesis and proliferation of fibroblasts, not observed only in the chitosan and LED (G5) and negative (G1) groups, were highlighted. On the last day of collection, after 17 days of treatment, it was possible to observe re-treatment in the negative control (G1), chitosan (G2), chitosan and LED (G4) and positive (G6) groups. The presence of unformed dense connective tissue was evident in the LED (G3) and LED and chitosan (G5) groups, characterizing the tissue remodeling, beginning the third healing phase, the repair phase.

The major highlight of the histological analysis was the rapid proliferation of fibroblasts influenced by the LED treatment, confirming the results found by other authors⁽¹²⁻¹³⁾, who cited the great contribution of the LED for the deposition of collagen fibers, fibroblast proliferation and reduction of the number of inflammatory cells, minimizing the initial stage of healing, the inflammatory phase. Other investigators⁽²⁴⁾ observed that the LED treated wounds achieved a better aesthetic quality, attributing to this the rapid proliferation of fibroblasts and collagen fibers. The LED⁽¹⁵⁾ was attributed to the stimulation of the rapid transition between the inflammatory and proliferative phase, accelerating the tissue repair in order to obtain a more uniform scar.

Chitosan also exerts a strong influence in all phases of healing, as seen with the stimulus for cell migration, proliferation of

fibroblasts and neoangiogenesis. These findings confirm reports from the literature⁽²⁵⁾, which showed that the action of chitosan stimulates the activation of macrophages, neutrophils, fibroblasts and collagen.

The combined action of LED and chitosan, regardless of the order of application, did not show any superiority in relation to the other treatment groups, surpassing only the control group. It is assumed that these treatments used together do not interfere in each other's actions, neither canceling nor increasing the cicatrizant action, determining results similar to those found in the groups using LED and chitosan alone.

CONCLUSION

All treatments were efficient in potentiating the healing effect and the action of the LED associated with chitosan independent of the moment of its application, seeming to have a synergic effect of the potentiation of the healing effect.

It emphasizes the need for further studies that include the evaluation of biochemical and histological parameters of the healing process in the association of these two treatment modalities in order to determine a form of positive interaction between them.

References

1. Oliveira AF, Batista JS, Paiva ES, Silva AE, Farias YJMD, Damasceno CAR, *et al.* Avaliação da atividade cicatrizante do jucá (*Caesalpinia ferrea* Mart. ex Tul. var. *ferrea*) em lesões cutâneas de caprinos. *Rev. bras. plantas med.* 2010;12(3): 302-10.
2. Deka G, Wu WW, Kaoa FJ. *In vivo* wound healing diagnosis with second harmonic and fluorescence lifetime imaging. *Journal of Biomedical Optics.* 2013; 18(6): 0612221-8
3. Ladeira PSR, Isaac C, Paggiaro AO, Hosaka EM, Ferreira MC. Úlceras nos membros inferiores de pacientes diabéticos: mecanismos moleculares e celulares. *Rev Med (São Paulo).* 2011;90(3):122-7.
4. Haddad MCL, Bruschi LC, Martins EAP. The effect of sugar on the processo f cicatrization of infected surgical incisions. *Rev. Latino-Am. Enfermagem.* 2000; 8(1): 57-65.
5. Ferreira CLR, Nicolau RA, Oliveira MA, Ribeiro D. Efeito da terapia LED ($\lambda = 945 \pm 20$ nm) de baixa intensidade sobre tecido epitelial de ratos diabéticos em processo de reparo. *Braz. J. Biom. Eng.* 2013;29(4), 404-13.
6. Fan L, Tan C, Wang L, Pan X, Cao M, Wen F, *et al.* Preparation, Characterization and the Effect of Carboxymethylated Chitosan-Cellulose Derivatives Hydrogels on Wound Healing. *J. Appl. Polym. SCI.* 2013; 128 (5): 2789-2796
7. Martins EAN, Ivernizzi MS, Campos MGN, Teodoro PA, Contieri MB, Silva LCLC. Emprego de membrana de quitosana em feridas cutâneas induzidas experimentalmente em equinos. *Ciência Rural, Santa Maria.* 2013; 43 (10): 1824-1830
8. Jin Y, Ling PX, He YL, Zhang TM. Effects of chitosan and heparin on early extension of burns. *Burns.* 2007;33(8): 1027-31.
9. Park CJ, Clark SG, Lichtensteiger CA, Jamison RD, Johnson AJ. Accelerated wound closure of pressure ulcers in aged mice by chitosan scaffolds with and without bFGF. *Acta Biomater.* 2009; 5(6): 1926-36.
10. Azad AK, Sermsintham N, Chandkrachang S, Stevens WF. Chitosan membrane as a wound-healing dressing: characterization and clinical application. *J Biomed Mater Res B Appl Biomater.* 2004; 69(2): 216-22.
11. Ueno H, Yamada H, Tanaka I, Kaba N, Matsuura M, Okumura M, *et al.* Accelerating effects of chitosan for healing at early phase of experimental open wound in dogs. *Biomaterials.* 1999; 20(15): 1407-14.
12. Agnol MAD, Nicolau RA, Lima CJ, Munin E. Comparative analysis of coherent light action (laser) versus non-coherent light (light-emitting diode) for tissue repair in diabetic rats. *Lasers Med Sci.* 2009;24: 909-16.
13. Lubart R, Landau Z, Lipovsky A, Nitzan Y. A new light device for wound healing. *Recent Patents on Biomedical Engineering.* 2008;1:13-7.
14. Fiorio FB, Silveira L, Munin E, de Lima CJ, Fernandes KP, Mesquita-Ferrari RA, *et al.* Effect of incoherent LED radiation on third-degree burning wounds in rats. *J Cosmet Laser Ther* 2011; 13(6): 315-22
15. Klebanov GI, Shuraeva NIu, Chichuk TV, Osipov AN, Rudenko TG, Shekhter AB, *et al.* A comparative study of the effects of laser and light-emitting diode irradiation on the wound healing and functional activity of wound exudate leukocytes. *Biofizika.* 2011; 50(6): 1137-44.
16. Whelan HT, Buchmann EV, Dhokalia A, Kane MP, Whelan NT, Wong-Riley MT, *et al.* Effect of NASA light-emitting diode irradiation on molecular changes for wound healing in diabetic mice. *J Clin Laser Med Surg.* 2003; 21(2): 67-74.
17. Ablon G. Combination 830-nm and 633-nm light-emitting diode phototherapy shows promise in the treatment of recalcitrant psoriasis: preliminary findings. *Photomed Laser Surg.* 2010; 28(1): 141-6.
18. Barreto, F.M. Uso do gel mucilaginoso das folhas de *Aloe vera* L. na terapêutica de feridas cutâneas aspectos clínicos e histológicos.[tese de doutorado].Teresina (PI): Programa de Pós-Graduação em Ciência Animal, Universidade Federal do Piauí; 2011 - 115p.
19. Garcia RB, Silva DLP, Costa M, Raffin FM, Ruiz NMS. Avaliação de géis obtidos a partir da acetilação da quitosana em meio heterogêneo. *Química Nova.* 2008;31(3):486-92.
20. Neto MLC, Filho JMR, Malafaia O, Filho MAO, Czeezko NG, Aoki S, *et al.* Avaliação do extrato hidroalcoólico de Aroeira (*Schinus terebinthifolius* Raddi) no processo de cicatrização d eferidas em pele de ratos. *Acta Cirurgica Brasileira.* 2006;21(2):17-22.
21. Vieira AP, Santos NR, Borges JHS, Vicenzi MP, Schmitz WO. Ação dos flavonoides na cicatrização por segunda intenção em fendas limpas induzidas cirurgicamente em ratos Wistar. *Semina: Ciências Biológicas e Saúde.* 2008;29(1):65-74.
22. Ribeiro MP, Espiga A, Silva D, Baptista P, Henriques J, Ferreira C, *et al.* Development of a new chitosan hydrogel for wound dressing. *Wound Repair Regen.* 2009; 17(6): 817-24

23. Fushimi T, Inui S, Nakajima T, Ogasawara M, Hosokawa K, Itami S. Green Light emitting diodes accelerate wound healing: characterization of the effect and its molecular basis in vitro and in vivo. *Wound Rep Reg.* 2012; 20, 226-235.
24. Meyer PF, Araújo HG, Carvalho MGF, Tatum BIS, Fernandes ICAG, Ronzio AO, et al. Avaliação dos efeitos do LED na cicatrização de feridas cutâneas em ratos Wistar. *Fisioterapia Brasil.* 2010; 11(8):428-32.
25. Muzzarelli RAA, Muzzarelli C. Chitosan in pharmacy and chemistry, Atec: Grottammare, 2002.

How to cite this article:

Renata Oliveira Moura et al. 2017, Evaluation of Healing Activity of Chitosan Gel Associated With The Light Emission Diode. *Int J Recent Sci Res.* 8(11), pp. 21443-21448. DOI: <http://dx.doi.org/10.24327/ijrsr.2017.0811.1075>
