



ISSN: 0976-3031

Available Online at <http://www.recentscientific.com>

CODEN: IJRSFP (USA)

International Journal of Recent Scientific Research
Vol. 8, Issue, 11, pp. 22026-22028, November, 2017

**International Journal of
Recent Scientific
Research**

DOI: 10.24327/IJRSR

Research Article

IS CROSS BAR ELEVATOR REALLY A CURSE IN MANDIBULAR THIRD MOLAR IMPACTIONS; A STUDY ON FIFTY PATIENTS

Shajah Hussain Sheikh., Shaista Rehman and Kamal Nabhi

Indira Gandhi Government Dental College Jammu

DOI: <http://dx.doi.org/10.24327/ijrsr.2017.0811.1184>

ARTICLE INFO

Article History:

Received 17th August, 2017
Received in revised form 21st
September, 2017
Accepted 05th October, 2017
Published online 28th November, 2017

ABSTRACT

Third molar surgery is routinely done by oral and maxillofacial surgeons. There are many confusions starting from classifications, nerve injuries (ROOD AND SHEHAB) and to the elevator principles. The present study aims to evaluate the mechanical advantage of cross bar in terms of vector of force rather than magnitude.

Key Words:

Vector of Force, Purchase Point,
Mechanical Advantage, Path of Withdrawal,
Mandibular Fracture, Cross Bar Elevator

Copyright © Shajah Hussain Sheikh., Shaista Rehman and Kamal Nabhi, 2017, this is an open-access article distributed under the terms of the Creative Commons Attribution License, which permits unrestricted use, distribution and reproduction in any medium, provided the original work is properly cited.

INTRODUCTION

Fracture of mandible during routine extraction is fortunately, a rare complication. The reasons for this are multifactorial, faulty surgical technique is one among them.^{4,5,6} Elevators, also known as exolevers are instruments which makeup the basic armamentarium for the procedure of exodontia,⁷ hence the operator must be well versed with the rules governing their use. The Winter's crossbar or T bar handle elevators (figure2) are designed for the removal of fractured mandibular molar roots. They are never used elsewhere other than for elevating of mandibular and maxillary 3rd molar impactions. This instrument can develop tremendous force which can lead to fracture of mandible. Third molar surgery corresponds to a significant portion of the surgical procedures carried out by oral and maxillofacial surgeons around the world and is an important activity at dental surgery training centers^{1,2}.

MATERIAL AND METHODS

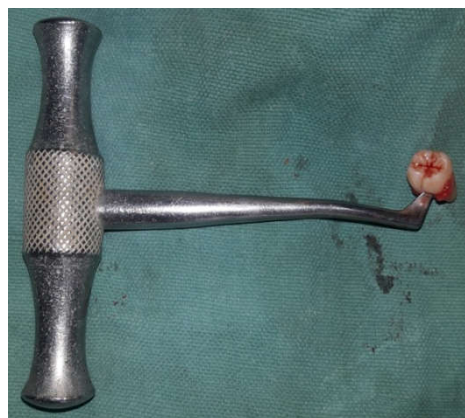
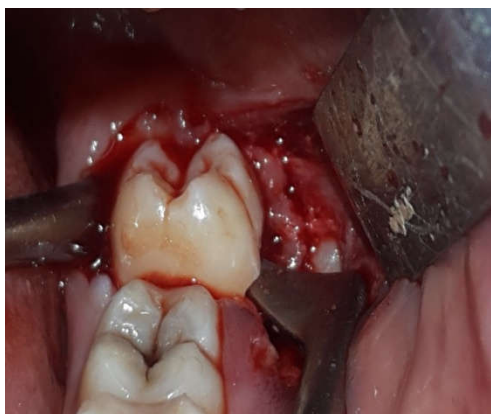A prospective cohort study was carried out involving patients submitted to at least 1 surgical intervention for the removal of a vertically impacted lower third molar between January 2016 to September 2017. Fifty patients who voluntarily sought treatment for the removal of impacted lower third molars were preselected. All patients were examined by a single

practitioner. All fifty fulfilled the eligibility criteria (indication for the surgery under local anesthesia and categories I and II of the American Society of Anesthesiology, i.e ASA I and II), and some patients were excluded based on the exclusion criteria (, systemic and/or behavior disorder that rendered local anesthesia unviable, pregnant or lactating women, recent irradiation, cognitive impairment that rendered the comprehension of the study objectives impossible, and non acceptance of the methodology). All patients signed terms of informed consent.

Fifty patients with vertically impacted mandibular third molars were operated so far in the department of oral and maxillofacial surgery government dental college Jammu with this technique. Thirty patients were female and twenty were male patients. Triangular incision was given. Then buccal guttering up to cemento enamel junction was done both buccally as well as distally with sparing of disto lingual plate. Then purchase point was made using straight round bur on the buccal aspect of third molars. The purchase point was made such that it is at equal level or very slightly below the fulcrum. In case of position b or position c the buccal bone was reduced deep up to the purchase as shown in figure 1, so that their position is at the equal level. Then cross bar was engaged into the purchase point such that while rotating the vector of force is along the path of withdrawal. By this way there is compressive force at the

*Corresponding author: **Shajah Hussain Sheikh**
Indira Gandhi Government Dental College Jammu

fulcrum rather than tensile so there is least chance of fracture of mandible.



DISCUSSION

Direction of vector is the most important criteria while extracting any tooth particularly third molars; the reason being inaccessible location of third molars. There is commonly fracture of tuberosity and resultant oroantral communication. To my experience most surgeons flaunt their extraction using just straight or coupland elevators and most of the times they are lucky and getting the tooth out in seconds. If the upper third molars are distoangular and single rooted this practice is magical but once the tooth is mesio or vertical or have multiple roots or is ankylosed this practice is equally dangerous. Whenever I had tuberosity fracture in the past it was always due to using straight elevator or coupland. Here again comes the concept of vector of force is it really in the direction of path of withdrawal if so then u will be respected if not u may land in fracture of tuberosity and resultant communication. We are not restlers had it been so restler would extract the tooth in seconds and the physically weak or female surgeons would take enough time or would have been unable. Same is the case with mandibular third molars. Though mandible is strong to resist fracture but as explained above in case of impacted thirs molars after guttering it becomes equally weak. And the vector of force if not in the direction of path of withdrawal may lead to fracture. Feared of fracture mandible due to excessive force generation, many authors have abandoned the practice of using cross bar elevator. Undoubtly there is excess force generation by cross bar but it is not the only variable. Vector of force matters more than magnitude in case of mandibular fracture. As experimented by scamphy⁸ it is the tensile force than

compressive which is more dangerous. Severe type of nerve injury is mostly due to using bur either during sectioning of root or doing guttering deep. Or it can happen due to roots while luxating them not along their path of exit. If one wants to prevent these complications; cross bar elevator is an ideal choice. It gives the ideal vector of force that is along the path of withdrawal. By putting the cross bar or any elevator in the buccal gutter; mandible potentially splits sagittally that is buccal plate splaysbucally and lingual plate lingually by tensile force. We can change this tensile force into compressive force by changing the location of purchase point and fulcrum. If fulcrum is at the level or below the purchase point there is least chance of fracture of mandible. By using cross bar elevator we can use more force to extract it without sectioning or without excessive bone cutting. By this practice there is less post-operative morbidity in terms of nerve injury, post-operative edema and trismus. Before sectioning the first choice should be to to elevate the tooth in toto by doing buccal and distal guttering upto cementonamel junction and then make purchase point on the buccal aspect of the tooth either at or just little below the fulcrum. Then carefully elevate it using cross bar elevator. By using cross bar surgeon should be familiar with the vector of force that means the force should be such that its vector should be more towards occlusal and little lingual which is possible if purchase and lever location is placed as stated above else force will split more of buccolingually which will cause sagittal split as happens commonly in case of mandibular fracture. Vertically impacted third molars have been considered most difficult tooth after distoangular the order being distoangular followed by vertical followed by horizontal and the last being mesioangular. If my above principle is followed then vertical will be most easy among all. Here again it is due to incompatibility between vector of force and path of withdrawal. As mentioned above use cross bar in vertical impacted and purchase and lever should be either at he same level or purchase little below the fulcrum or reverse. If the thirh molar is single rooted just after guttering or if multirooted use the same method as described above if multirooted tooth is showing resistant section it and get the tooth seperately using the same above method.

Extraction of teeth other than third molars

CONCLUSION

In our study there was not a single case of iatrogenic fracture mandible even though excess force was used. In mechanical advantage, magnitude is not the only variable; it includes vector of force also which we as surgeons unfortunately least consider. As already said above vector of force is more important than magnitude in case of disimpaction or even extraction of any tooth.

References

1. Lipa Bodner; Peter A Brennan; Niall M. M c leod. Characteristics of iatrogenic mandibular fractures associated with tooth removal; review & analysis of 189 cases. *Br. J Oral Maxillofac Surg* 2011;49: 567-572.
2. Niedzielska I; Kowol I; Sroczynska - Grula A Iatrogenic injury during extraction of lower molar teeth. *Dent Med Probl.* 2009, 46:501-505.

3. Neelima A. Malik, Text book of Oral & MFS. 2005 Jaypee Bros. page 107.
4. Ekholm A; Mandibular fracture in tooth extraction suom hammaslaak toim 1953; 49:11-14.
5. Harnisch H. Iatrogenic fracture of the jaw. Quintessence Int (Berl) 1971; 2: 11-13.
6. Berlin J G., Mandibular fracture caused by tooth extraction. 2WR 1977, 86: 8-11
7. G.O. Kruger, Text book of Oral & MFS. 6th edn 1984, CV Mosby company page 76
8. Champy M, Lodde JP, Schmidt R. Mandibular osteosynthesis by miniature screwed plates via a buccal approach. *J Maxillofac Surg*1978; 6: 14. 16-24

How to cite this article:

Shajah Hussain Sheikh., Shaista Rehman and Kamal Nabhi.2017, Is Cross Bar Elevator Really A Curse In Mandibular Third Molar Impactions; A Study on Fifty Patients. *Int J Recent Sci Res.* 8(11), pp. 22026-22028.
DOI: <http://dx.doi.org/10.24327/ijrsr.2017.0811.1184>
