



RESEARCH ARTICLE

EFFECTS OF PESTICIDE MONOCROTOPHOS (ORGANOPHOSPHATE), ON THE GONADAL DEVELOPMENT OF FEMALE FRESHWATER MURREL, *CHANNA PUNCTATUS* (BLOCH)

Amir Maqbool and Imtiaz Ahmed\*

Department of Zoology, University of Kashmir, Hazratbal, Srinagar, India

ARTICLE INFO

Article History:

Received 15<sup>th</sup>, September, 2013

Received in revised form 25<sup>th</sup>, September, 2013

Accepted 11<sup>th</sup>, October, 2013

Published online 28<sup>th</sup> October, 2013

Key words:

Pesticide monocrotophos *Channa punctatus*  
gonadal development

ABSTRACT

The effects of pesticide monocrotophos (organophosphate), on the ovaries of freshwater murrel, *Channa punctatus* were studied. Exposures for 15 and 45 days with histological preparations at 1 ml L<sup>-1</sup>, and 2 ml L<sup>-1</sup> sublethal concentrations along with control were examined. Pre spawned 10 fish (47.85±0.75gm; 17.80 ± 0.50cm) were randomly stocked in 50 L aquarium in triplicate groups for each treatment levels. The effects of monocrotophos were analysed after 15 and 45 days of exposure, respectively. The control contained an abundance of the different stages of oocytes (Oocytes I, II, III, and IV) and had an intact ovigerous lamellae and follicular lining. The control also contained a thick and complete ovarian wall with evident previtellic and vitellic nucleoli. After 15 days of exposure the gonado somatic index (GSI) significantly (P<0.05) decreased in the two exposure concentration, where the maximum decrease in both GSI and ovary was observed at higher concentration i.e. 2 ml L<sup>-1</sup> compared with control. Decreased vitellogenesis and oocyte atresia was also observed at higher concentration. While after 45 days of exposure a significant (P<0.05) increase in oocyte atresia and decreased vitellogenesis was recorded with clear indication of vacuolization and tissue necrosis. On the basis of the above finding it is concluded that widely used organophosphate monocrotophos in agriculture has produced significant toxic effects on gonadal development of *Channa punctatus*.

© Copy Right, IJRSR, 2013, Academic Journals. All rights reserved.

INTRODUCTION

The biological and environment persistence of organochlorine pesticides have led to the extensive use of less persistent, easily biodegradable organophosphates (Ahmad *et al.*, 1987; Siddiqui *et al.*, 1991). Although organophosphate insecticides tend to undergo fairly rapid degradation in the environment, however organisms may be exposed to sub-lethal concentrations of the pesticide for an extended period (Agrahari & Gopal, 2008). This poses a great danger to freshwater organisms including fishes. There are many pathways by which insecticides leave their sites of application and distribute throughout the environment and enter the aquatic ecosystem. Most insecticides ultimately find their way into rivers, lakes and ponds (Tarahi Tabrizi, 2001; Honarpajouh, 2003; Bagheri, 2007; Shayeghi *et al.*, 2007; Vryzas *et al.*, 2009; Werimo *et al.*, 2009; Arjmandi *et al.*, 2010) and have been found to be highly toxic to non-target organisms that inhabit natural environments close to agricultural fields. During the past few decades, the extensive use of pesticides has increased manifolds worldwide in order to protect crops, stored grains and human beings from pests and also to prevent certain diseases such as malaria, plague, sleeping sickness, etc spread due to insect vectors. Among pesticides, monocrotophos [dimethyl (E)-1-methyl-2-(methyl carbamoyl) vinyl phosphate, MCP], commonly known as Azodrin, is an important broad spectrum systemic organophosphate pesticide, extensively used in agriculture for protection of variety of crops, such as cotton, rice, and sugarcane. It is used to control a wide spectrum of chewing, sucking and

boring insects (aphids, caterpillars, Helicoverpa spp, mites, moths, jassids, budworm, scale, stem borer as well as locusts, and it is usually sprayed aerially. During the spray operations, this pesticide may drift near rivers and ponds creating the potential for exposure on the aquatic organisms to monocrotophos (Rao, 2004 and Ferrando *et al.*, 1992). Monocrotophos is classified as a highly hazardous pesticide (WHO, 2004), and also including in Rotterdam convention on the prior informed consent procedure for certain hazardous chemicals and pesticides in international trade. The importance of pesticides in India can be understood from the fact that agriculture is a major component of the Indian economy: it contributes 22% of the nation's GDP and is the livelihood of nearly 70% the country's workforce (WHO, 2009). Monocrotophos use is currently banned or severely restricted in many countries, including all EU members. However, it is still extensively used in agriculture in developing countries such as China, Pakistan and Kuwait. In India, monocrotophos while mainly applied against cotton pests, it is also used on rice, castor, citrus, olives, rice, maize, sorghum, sugar cane, sugar beet, peanuts, potatoes, soybeans, cabbage, onion and pepper ornamentals and tobacco. Generally most aquatic animals including fishes respire through their gills and sometimes with the help of skin. These respiratory organs frequently encounter hazardous pollutants which are present in water in different forms and these pollutants may lead to the alteration in the normal area which causes the reduction in oxygen consumption and physiological imbalance in the organism. Although, many workers in the past have reported the effects of pesticides on

\* Corresponding author: **Imtiaz Ahmed**, DST, Sponsored Fish Nutrition Research Laboratory  
Department of Zoology, University of Kashmir, Hazratbal, Srinagar 190006, India

endocrine regulation of reproduction of Indian fishes and convincingly demonstrated that these pesticides cause reproductive failure primarily by disrupting secretory activities of the hypothalamo-hypophyseal-gonadal axis. Aquatic organisms, particularly fish, are highly sensitive to monocrotophos and its toxicity to fish has been reported (Rao, 2004 and Ferrando *et al.*, 1992). Sublethal effects of monocrotophos in fish were directly related to the inhibition of various metabolic processes (Ferrando *et al.*, 1991). Monocrotophos has been found to cause reproductive toxicity in fishes (Ru *et al.*, 2010). Today the role of histopathology has received a significant interest as an endpoint in endocrine disrupting chemicals (EDC) research in aquatic organisms, because histopathological changes are often the result of the integration of a large number of interactive physiological processes (Malambo *et al.*, 2006). On the other hand, sublethal exposure to persistent organic compounds may alter key enzymatic activities and potentially cause reproductive effects by reducing fecundity and population recumbent (Patyna *et al.*, 1999). Therefore, the present investigation was carried out to find out how significantly the monocrotophos can damage the ovarian tissues of the freshwater fish *Channa punctatus* upon exposure to its different levels of concentration.

## MATERIALS AND METHODS

### Experimental Fish and Chemical

The healthy adult females (17.80 ± 0.50cm length and 47.85± 0.75gm weight) of *Channa punctatus* were obtained from the local market Ginnori Bhopal (Madhya Pradesh) India. The fish were transported in plastic containers to the fisheries laboratory and washed with 0.1% KMnO<sub>4</sub> solution. Prior to the start of the experiment the fish were acclimatized to the laboratory conditions for 15 days in dechlorinated tap water. They were maintained in glass aquaria containing dechlorinated tap water. The experiment was conducted under natural light and ambient temperature. Commercial grade monocrotophos (36% soluble liquid (SL) (Nadia Biotech Pvt. Ltd., Indore, Madhya Pradesh, India) was used in this study. Monocrotophos experiment was carried out in semi-static renewal system based on APHA (2005). LC<sub>50</sub> of monocrotophos for 96 hour was determined by following the Trimmed Spearman Karber method (Hamilton *et al.*, 1977). LC<sub>50</sub> of monocrotophos for 96 hr was found to be 20.24 ml L<sup>-1</sup>. The physicochemical properties of water were determined by using the standard protocol of APHA (2005). These parameters are water temperature 26.50 ± 2.5 °C, pH 7.1 ± 0.3, dissolved oxygen 6.8 ± 1.8 and total alkalinity 290.30 ± 3.1 mg L<sup>-1</sup>, respectively.

### Experimental Design

Acclimatized fishes were divided into three replicate groups, ten fishes in each group. Group one was kept in pesticide free freshwater and treated as the control. Fish in group two and three were exposed to two sub-lethal concentrations of monocrotophos viz. 1 ml L<sup>-1</sup> (~5% of 96 h LC<sub>50</sub>) and 2 ml L<sup>-1</sup> (~10% of 96 h LC<sub>50</sub>) for a period of 15 and 45 days.

Feeding was stopped 24 hr before the exposure. Water was changed daily to remove the fish metabolites and to maintain the pesticide concentration. During the exposure period, the fish were fed dry fries of prawn twice a day. Half of the fishes were taken out at the end of 15 days for histopathological analysis and remaining were taken out at the end of 45 days. Fish were killed by decapitation and ovaries were dissected out, weighed and fixed in Bouin's fluid. After dehydrating through graded alcohol, tissues were cleared in xylene and embedded in paraffin. Tissue sections of 6 µm thickness were cut, passed through descending and ascending series of graded alcohol and stained with haematoxylin and eosin. The changes in exposed sections of gonads were compared with those of the control sections. The histopathological changes were photographed using olympus photomicroscope. The gonadosomatic index (GSI = Ovarian weight/ body weight x 100) was calculated for each group for comparison. Follicular kinetics were studied in histological sections of the ovaries. The follicles were classified as previtellogenic, vitellogenic or atretic based on their histomorphology. For the counting of the follicles, 100 follicles were randomly selected from anterior, middle and posterior segments of the ovary.

## RESULTS

### GSI

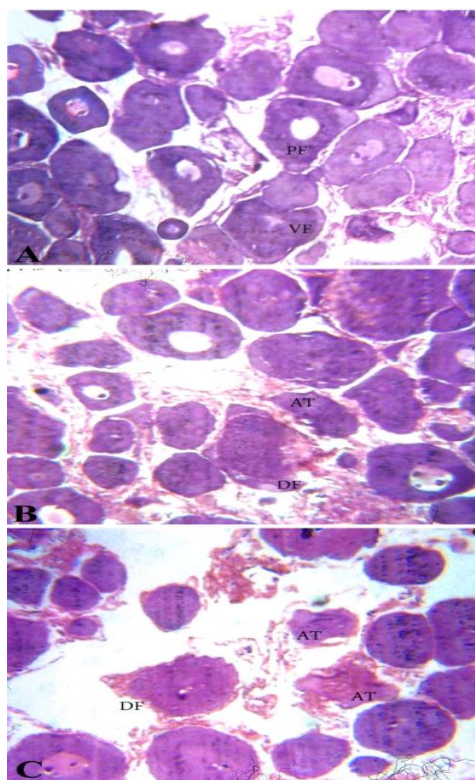
A dose and duration dependent decrease of gonadosomatic index occurred in monocrotophos-exposed fish as compared to their respective controls (Table 1). Over the 15 days exposure significant changes were observed only in 2 ml L<sup>-1</sup> treated group, while significant results were produced in both 2 ml L<sup>-1</sup> as well as 1 ml L<sup>-1</sup> groups when the exposure period extended to 45 days. The GSI didn't show any significant change in 1ml L<sup>-1</sup> exposed fish group with respect to control after 15 days of exposure. However, it was reduced approximately by 25% in 2 ml L<sup>-1</sup> exposed group, respectively, compare to the control value on 1-month exposure, which further increased to 20 and 35% for 1ml L<sup>-1</sup> and 2 ml L<sup>-1</sup> on 2-months exposure, respectively.

### Ovarian Histopathology

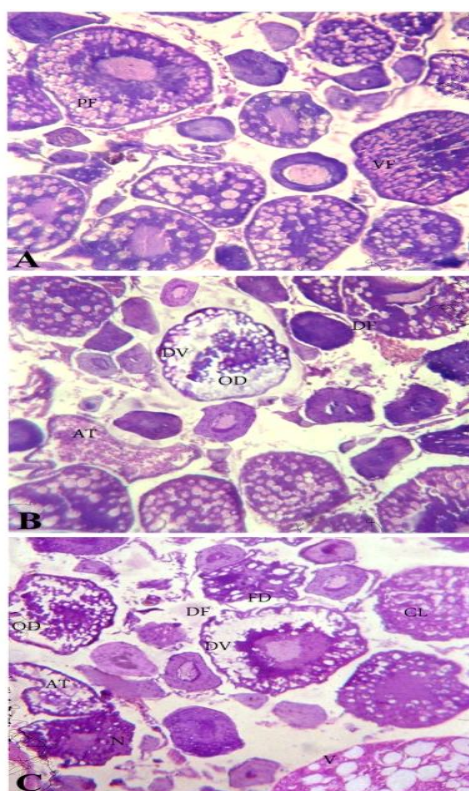
Fish exposed to sub-lethal concentration of monocrotophos for different exposure periods showed dose and duration dependent histopathological alterations. Retarded ovarian growth and development was observed in the monocrotophos treated fish as compared to the control fish (Fig. 1A and 2A). Follicular kinetics revealed a general decrease in the percentage of vitellogenic follicles in all the treated groups. The ovary of fish exposed to 1ml L<sup>-1</sup> monocrotophos for 15 days, showed a small degree of oocyte degeneration and a few atretic follicles (Fig 1B) which increased in 2 ml L<sup>-1</sup> exposed fish, where oocytes with deshaped and disrupted follicular epithelium were seen. (Fig.1C). Profound follicular damage was observed in 45 days exposed fish (Fig. 2B and 2C). In 1ml L<sup>-1</sup> exposed fish, empty spaces were observed between ovigerous lamellae with mature oocytes showing decreased vitellogenesis (Fig. 2B).

**Table 1** Changes in GSI and the percentage of various oocytes of *C. punctatus* exposed to sub-lethal concentrations (1.0 and 2.0 mg L<sup>-1</sup>) of monocrotophos for 15 and 45 days (n=3)

Parameters	15 Days			45 Days		
	Control	1 ml L <sup>-1</sup>	2 ml L <sup>-1</sup>	Control	1 ml L <sup>-1</sup>	2 ml L <sup>-1</sup>
GSI (%)	2.168± 0.24	1.915±0.08	1.610±0.07	4.20±0.16	3.33±0.18	2.73±0.10
PVF	41.25±1.29	49.25±1.28	60.75±1.59	26.50±1.20	38.50±1.79	49.75±1.44
VF	56.25±0.73	49.00±0.82	36.25±1.58	68.75±1.28	52.25±1.59	38.0±1.05
AF	1.25±0.29	1.50±0.33	2.25±0.55	4.75±0.55	9.50±1.20	11.75±0.87



**Fig. 1** Transverse sections of ovary stained with haematoxylin and eosin showing histopathological alterations on 15 days monocrotophos exposures. (A) control, (B) 1ml L-1 exposed and (C) 2ml L-1 exposed. PV, Previtellogenic follicle; VF, Vitellogenic follicle; At, atresia; DF, Follicular wall disruption.



**Fig. 2** Transverse sections of ovary stained with haematoxylin and eosin showing histopathological alterations on 45-days monocrotophos exposures. (A) control, (B) 1ml L-1 exposed and (C) 2ml L-1 exposed. PV, Previtellogenic follicle; VF, Vitellogenic follicle; At, atresia; DF, Follicular wall disruption; DV, decreased vitellogenesis; FD, Disrupted follicle; CL, clumping of yolk globules; OD, ooplasm degeneration; N, necrosis; V, vacuolization.

The degeneration of ooplasm and follicular wall in previtellogenic follicles was observed in 2 ml L<sup>-1</sup> exposed fish ovary. Vacuolization, necrosis and clumping of yolk globules were observed in vitellogenic follicles. Maximum number of Atretic follicles were observed in this group.

## DISCUSSION

The data from the present experiment indicates that long term exposure to both low and high dose of monocrotophos caused ovarian toxicity in *Channa punctatus*. The retardation of ovarian growth was reflected in the reduced GSI, which became more prominent over 45 days of exposure. Increased deterioration and damage was observed at higher concentration and longer duration of exposure. Ovarian follicular kinetics showed lesser percentage of vitellogenic oocytes than pre-vitellogenic oocytes in monocrotophos treated groups, indicating disruption of oocyte maturation. This reproductive impairment could have occurred due to the direct toxic impact of monocrotophos at various tissues and interrupted specific levels of vitellogenesis regulation. Toxic impact of monocrotophos on oocyte growth, hepatic synthesis of vitellogenin and follicular intake of vitellogenin might be another reason behind retardation of ovarian development. Similar effects were also reported by Kumar & Panth (1988) when guppies (*Puntius conchonius*) were exposed to sublethal dose of monocrotophos for 2-4 months. Monocrotophos was also found to decrease ovarian weight, as well as reduced the numbers of various follicle types in the mouse ovary (Rao & Kaliwal, 2002). They also reported an increase in the number of atretic follicles at the selected doses. Chronic exposure to low environmental concentration of organophosphates may lead to a variety of reproductive and developmental defects in fish (Timothy *et al.*, 2001). Extensive atresia has been reported in the ovaries of *Tilapia leucosticte* after exposure to the organophosphate, lebaycid, making the fish unable to spawn for upto 9 weeks (Kling, 1981). Ram & Sathyanesan (1987) exposed murrel (*Channa punctatus*) to 20 mg/ml cythion (50% malathion, 50% organic solvents) for 6 months and observed an increase in oocyte degeneration, which resulted in retarded ovarian growth and lower GSI. Exposure to 0.1 mg L<sup>-1</sup> methyl parathion for 75 days resulted in substantial oocyte damage in carp minnow (*Rasbora daniconius*) (Rastogi & Kulshrestha, 1990). Haider & Upadhyaya (1986) found reduced gonad weights and vitellogenesis in female striped catfish (*Mystus vittatus*) after 12 weeks of exposure to four different organophosphate pesticides (malathion, birlane, gardona, and phosdrin).

In the present study, it was observed that the number of vitellogenic oocytes decreased in the ovaries of monocrotophos treated fish. This might be due to the inactivation or blocking of some maturation inducing factors in the ovary of *Channa punctatus*. The increased ratio of previtellogenic oocytes in the monocrotophos treated groups supports this hypothesis. Monocrotophos might also target the hypothalamic-pituitary-ovarian axis, whereby disrupting the normal gonadotropin levels, which would harm the ovary indirectly by causing atresia and reduced fertility. Organophosphates appear to interact with the hypothalamic-pituitary-ovarian axis to reduce gonadotropin levels (Singh & Singh, 1981; Rattner *et al.*, 1982). Any imbalance in the gonadotropin levels can have a negative impact on the oocyte maturation. Singh & Singh (1981) suggested that exposure to the organophosphate, aldrin and parathion may reduce the serum and pituitary levels of both FSH and LH in freshwater catfish, *Heteropneustes fossilis* (Bloch). Further many workers have

reported endocrine disruption by organophosphate pesticides in fish leading to reproductive and developmental effects (Kapur *et al.*, 1978; Singh & Singh, 1982; Singh & Singh, 1987; Ghosh *et al.*, 1989; Singh, 1989; Bagchi *et al.*, 1990; Sinha *et al.*, 1991 Dutta *et al.*, 1994 and Moore and Waring, 1996). In conclusion, the present findings indicate that sublethal doses of monocrotophos show inhibitory effects on ovarian development and oocyte maturation in *Channa punctatus* which can lead to reduced fecundity and abnormal offspring.

## Acknowledgements

The authors are grateful to the Head, Department of Zoology, University of Kashmir, Hazratbal, Srinagar, India for providing necessary facilities for communication and preparation of the manuscript. The second author is also grateful to the Head, Department of Zoology, Barkatullah University Bhopal for providing necessary laboratory facilities during the project work.

## References

- Agrahari, S. and Gopal, K. 2008. Inhibition of Na<sup>+</sup>-K<sup>+</sup>-ATPase in different tissues of freshwater fish *Channa punctatus* (Bloch) exposed to monocrotophos, *Pest. Biochem. Physiol.*, 92: 57-60.
- Ahmad, I., Siddiqui, M.K.S. and Ray, P.K. 1987. Pesticide burden on some insects of economic importance in Lucknow (India). *Environ. Monit. Assess.*, 9:25-28.
- APHA, 2005. Standard methods for the examination of water and wastewater. 21<sup>st</sup> ed., APHA, Washington, DC.
- Arjmandi, R., Tavakol, M. and Shayeghi, M. 2010. Determination of organophosphorus insecticide residues in the rice paddies. *Intl. J. Environ. Sci. Technol.*, 7: 175-182.
- Bagchi, P., Chatterjee, S., Ray, A. and Deb, C. 1990. Effect of Quinalphos, organophosphorous insecticide, on testicular steroidogenesis in fish, *Clarias batrachus*, *Bulletin of Environ. Contam. Toxicol.*, 44: 871-875.
- Bagheri, F. 2007. Study of pesticide residues (Diazinon, Azinphosmethyl) in the rivers of Golestan province (GorganRoud and Gharehsou), M.Sc. thesis, Tehran University of Medical Science. Tehran, Iran, 125 pp.
- Dey, S. and Bhattacharya, S. 1989. Ovarian damage to *Channa punctatus* after chronic exposure to low concentrations of elsan, mercury and ammonia. *Ecotoxicol. Environ. Saf.*, 17:247-257.
- Dutta, H., Nath, A., Adhikari, S., Roy, P., Singh, N. and Datta, Munshi, J. 1994. Sublethal malathion induced changes in the ovary of an air-breathing fish, *Heteropneustes fossilis*: a histological study, *Hydrobiol.*, 294: 215-218.
- Ferrando, M.D., Gamon, M. and Andreu, E. 1991. Comparative acute toxicities of selected pesticides to *Anguilla anguilla*, *J. Environ. Sci. Health.*, 26: 491-498.
- Ferrando, M.D., Gamon, M. and Andreu, E. 1992. Accumulation and distribution of pesticides in *Anguilla anguilla* from Albufera Lake (Spain), *J. Environ. Biol.*, 13: 75-82.
- Ghosh, P., Bhattacharya, S. and Bhattacharya, S. 1989. Impact of non lethal levels of metacid-50 and carbaryl on thyroid function and cholinergic system of *Channa punctatus*. *Biomed. Environ. Sci.*, 2: 92-97.
- Ghosh, P., Bhattacharya, S. and Bhattacharya, S. 1990. Impairment of the regulation of gonadal function in *Channa punctatus* by metacid-50 and carbaryl under laboratory and field condition. *Biomed. Environ. Sci.*, 3:106-112.
- Haider, S. and Upadhyaya, N. 1985. Effect of commercial formulation of four organophosphorous insecticides on the ovaries of a freshwater teleost, *Mystus vittatus* (Bloch)- A histological and histochemical study. *J. Environ. Sci. Health.*, 20:321-340.
- Haider, S. and Upadhyaya, N. 1986. Effect of Commercial formulation of four organophosphorus insecticides on the LH-Induced Germinal Vesicle Breakdown in the oocytes of a freshwater teleost, *Mystus Vittatus* -a preliminary in vitro study, *Ecotoxicol. Environ. Saf.*, 161-165.
- Hamilton, M.A., Russo, R.C. and Thruston, R.V. 1977. Trimmed Spearman-Karber method for estimating median lethal concentration toxicity bioassay. *Environ. Sci. Technol.*, 11: 714-719.
- Honarpojoh, K. 2003 Study and identification of OP pesticides residues (Azinphosmethyl and Diazinon) in the Mahabad and Siminerood rivers, M.Sc. thesis, Tehran University of Medical Science. Tehran, Iran, pp. 95.
- Kapur, K., Kamaldeep, K. and Toor, H. 1978. The effect of fenitrothion on reproduction of a teleost fish, *Cyprinus carpio communis* (Linn.): A biochemical study, *Bull. Environ. Contam. Toxicol.*, 20: 438-442.
- Kling, D. 1981. Total atresia of the ovaries of *Tilapia leucosticte* (cichlidae) after intoxication with the insecticide lebaycid. *Experientia* 37:73-74.
- Kumar, S. and Pant, S. 1988. Comparative sublethal ovarian pathology of some pesticides in the teleost, *Puntius Conchoniuis* Hamilton, *Bull. Environ. Contam. Toxicol.*, 41: 227-232.
- Lal, B. and Singh, T.P. 1987. The effect of malathion and c-BHC on the lipid metabolism in relation to reproduction in the tropical teleost, *Clarias batrachus*. *Environ. Poll.*, 48:37-47.
- Moore, A. and Waring, C. 1996. Sublethal effects of the pesticide diazinon on olfactory function in mature male Atlantic salmon Parr. *J. Fish Biol.*, 48: 758-775.
- Patyna, P.J., Davi, R.A., Parkerton, T.F., Brawn, R.P. and Cooper, K.R. 1999. A proposed multigeneration protocol for Japanese medaka (*Oryzias latipes*) to evaluate effects of endocrine disruptors. *Sci. Total. Environ.*, 233: 211-220.
- Pawar, K.R. and Katdare, M. 1983. Effect of sumithion on the ovaries of freshwater fish *Garra mullya* (Sykes). *Curr. Sci.*, 16:784-785.
- Ram, R.N. and Sathyanesan, A.G. 1987. Effect of long term exposure to cythion on the reproduction of the teleost fish, *Channa punctatus* (Bloch). *Environ. Pollut.*, 44:49-60.
- Rao, J.V. 2004. Effects of monocrotophos and its analogs in acetylcholinesterase activity's inhibition and its pattern of recovery on euryhaline fish *Oreochromis mossambicus*, *Ecotoxicol. Environ. Saf.*, 59: 217-222.
- Rao, R.P. and Kaliwal, B.B. 2002. Monocrotophos induced dysfunction on estrous cycle and follicular development in mice. *Ind. Health.*, 40:237-44.
- Rastogi, A. and Kulshrestha, S.K. 1990. Effect of sublethal doses of three pesticides on the ovary of a Carp minnow, *Rasbora deniconinus*. *Bull. Environ. Contam. Toxicol.*, 45: 742-747.
- Rattner, B. A., Sileo, L. and Scanes, C. G. 1982. Oviposition and the plasma concentrations of LH, progesterone and corticosterone in bobwhite quail (*Colinus virginianus*) fed parathion. *J. Reprod. Fert.*, 66:147-155.
- Ru, S., Tian, H., Wang, W. and Bing, X. 2010. Effects of monocrotophos on the reproductive axis in the female

- goldfish (*Carassius auratus*) Comp. Biochem. Physiol., Part C 152: 107-113.
- Shayeghi, M., Darabi, H., Abtahi, H., Sadeghi, M., Pakbaz, F. and Golestaneh, S.R. 2007. Assessment of persistence and residue of diazinon and malathion in three Rivers (Mond, Shahpour and Dalaky) of Bushehr province in 2004-2005 years. Iranian South Med. J., 10: 54-60.
- Shukla, L., Srivastava, A., Merwani, D. and Pandey, A.K. 1984. Effect of sublethal malathion on ovarian histophysiology in *Sarotherodon mossambicus*. Comp. Physiol. Ecol. 27:13-17.
- Siddiqui, M.K.J., Rahman, M.F., Mustafa, M. and Bhalerao, U.T. 1991. A comparative study of blood changes and brain acetylcholinesterase inhibition by monocrotophos and its analogues in rats. Ecotoxic. Environ. Saf., 21: 283-289.
- Singh, H. 1989. Interaction of xenobiotics with reproductive endocrine functions in a protogynous teleost, *Monopterus albus*, Marine Environ. Res., 28:285-289.
- Singh, H. and Singh, T. P. 1981. Effect of parathion and aldrin on survival, ovarian <sup>32</sup>P-uptake and gonadotrophic potency in a freshwater catfish, *Heteropneustes fossilis* (Bloch). Endokrinologie 77:173-178.
- Singh, H. and Singh, T.P. 1982. Effect of some pesticides on hypothalamo-hypophyseal-ovarian axis in the freshwater catfish, *Heteropneustes fossilis* (Bloch). Environ. Poll., 27:283-288.
- Singh, S. and Singh, T.P. 1987. Impact of malathion and hexachlorocyclohexane on plasma profiles of three sex hormones during different phases of the reproductive cycle in *Clarias batrachus*, Pest. Biochem. Physiol., 27: 301-308.
- Sinha, N., Lal, B. and Singh, T. P. 1991. Carbaryl-Induced Thyroid Dysfunction in the Freshwater Catfish, *Clarias Batrachus*, Ecotoxic. Environ. Saf., 21: 240-247.
- Tarahi Tabrizi, S. 2001. Study of pesticide residues (diazinon, malathion, metasytoux) in the Tabriz Nahand River, M.Sc. Thesis, Tehran University of Medical Science, Tehran, Iran, pp.88.
- Gross, T.S., Arnold, S.B., Sepulveda, M.S. and McDonal, K. 2001. Endocrine disrupting chemicals and endocrine active agents. Research report 114pp.
- Vryzas, Z., Vassiliou, G., Alexoudis, C. and Papadopoulou-Mourkidou E. 2009. Spatial and temporal distribution of pesticide residues in surface waters in northeastern Greece. Water Res., 43: 1-10.
- Werimo, K., Bergwerff, A.A. and Seinen, W. 2009. Residue levels of organochlorines and organophosphates in water, fish and sediments from Lake portion. Aquatic Eco. Health Manag., 12: 337-341.
- WHO, 2009. Health implications from monocrotophos use: a review of the evidence in India. 60pp.
- WHO, 2004. The WHO recommended classification of pesticides by hazards and guidelines to classification. Geneva: 2004. 56pp.

\*\*\*\*\*