

**CASE REPORT****BILOBED DISTAL LAD ANEURYSM- A RARE CASE REPORT****Mohammed Abiduddin Arif., Ramesh Chandra Mishra and Amaresh Rao Malempati**

Nizam's Institute of Medical Sciences, Hyderabad

**ARTICLE INFO****Article History:**Received 10<sup>th</sup> July, 2016  
Received in revised form 14<sup>th</sup> August, 2016  
Accepted 08<sup>th</sup> September, 2016  
Published online 28<sup>th</sup> October, 2016**Key Words:**

Bi-lobed LAD aneurysm, Medical management

**ABSTRACT**

Coronary artery aneurysm (CAA) is an uncommon clinical finding, with an incidence varying from 1.5%-4.9% in adults, and is usually considered a variant of coronary artery disease (CAD). CAA identified in the context of acute coronary syndrome (ACS) represents a unique management challenge, particularly if the morphology of the CAA is suspected to have provoked the acute clinical syndrome. We report a case of 33-year-old male who presented with chest pain. Chest radiography showed no cardiomegaly, and electrocardiography showed inverted T waves in lead III. Echocardiography showed no regional wall motion abnormality and good biventricular function. CT Coronary angiogram showed Left Anterior Descending artery ectasia with distal segment giant bilobed aneurysm. The patient was discharged on medical management with aspirin and warfarin therapy and advised to be on regular follow up. At 6 months' follow-up, he remained asymptomatic.

Copyright © Mohammed Abiduddin Arif *et al.*, 2016, this is an open-access article distributed under the terms of the Creative Commons Attribution License, which permits unrestricted use, distribution and reproduction in any medium, provided the original work is properly cited.

**INTRODUCTION**

Aneurysms of coronary artery are exceedingly rare clinical entities, encountered incidentally in approximately 0.1% of patients who undergo routine angiography. The first case was reported by Morgagni, while conducting postmortem study. In the order of frequency, the commonest site of aneurysm in the coronary anatomy is a right coronary artery, circumflex followed by anterior descending arteries. Left main aneurysm seems to be the rarest with an incidence of 0.1%. The most common cause of a coronary aneurysm mostly seems to be atherosclerotic.

**Case Scenario**

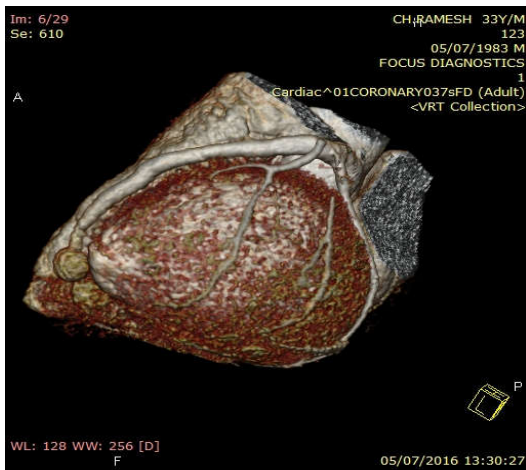
A 33-year-old male, non-hypertensive, non-diabetic presented with acute onset of chest pain at rest that radiated to his jaw and left arm. He denied any history of dyspnoea, orthopnoea, tobacco use, or any noteworthy febrile illnesses during childhood. The physical examination was unexceptional; electrocardiography revealed inverted T waves in lead III, with no ST-segment elevation. Troponin T levels were initially positive. The rest of his laboratory results were normal. Echocardiography showed an ejection fraction of 0.60, with no valvular abnormalities. Subsequent cardiac catheterization showed a large, bi-lobed left anterior descending artery aneurysm that involved the distal portion. CT Coronary angiogram (Fig. 1 to 4) was done for further evaluation. The patient had an uneventful hospitalization and was discharged on aspirin and warfarin therapy. At 6 months' follow-up, he remained asymptomatic.

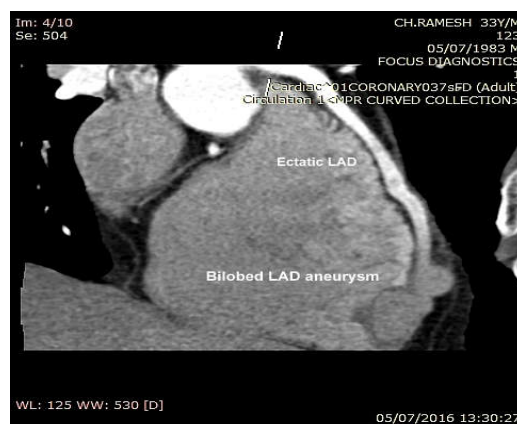

Fig. 1 CT Coronary angiogram showing ectatic Left Anterior Descending Artery (LAD) with distal bi-lobed aneurysm.

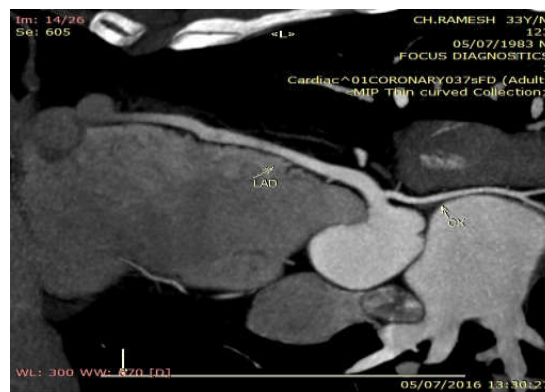

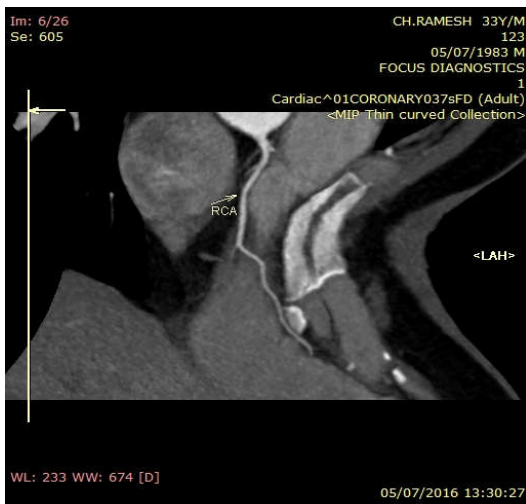Fig. 2 Left circumflex artery normal in course and calibre.



**Fig. 3** Bi-lobed aneurysm proximal lobe approx. 1.5 cm X 1.4 cm, distal lobe approx. 2.2 cm x 1.9 cm.



**Fig. 4** Right coronary artery arising from right sinus

## DISCUSSION

Coronary artery aneurysms (CAAs) were originally described by Morgagni in 1761,<sup>1</sup> and the 1st actual case report was published by Bougon in 1812.<sup>2</sup> Morphologically, these aneurysms may be saccular or fusiform, single or multiple.

Such lesions are generally defined as aneurysmal when their diameters exceed by at least 1.5 to 2 times the diameters of adjacent normal vessels.<sup>1</sup> Most CAAs occur as a consequence of atherosclerosis, but other causes include congenital malformation, Kawasaki disease, traumatic injury, polyarteritis no dosa, systemic lupus erythematosus, Ehlers-Danlos syndrome, scleroderma, Marfan syndrome, and Takayasu's arteritis.<sup>1</sup> No unique cluster of symptoms or risk-factor profile has been ascribed to CAAs, and patients typically present with signs and symptoms indicative of coronary artery disease.<sup>1</sup>

Considerable controversy remains regarding the most appropriate therapeutic strategy for the management of patients with CAAs. Many investigators have hypothesized that abnormal flow within CAAs predisposes patients to thrombus formation and distal embolization, even in the absence of obstructive coronary disease.<sup>1,3,4</sup>

Most investigators would, therefore, agree that the presence of CAAs in and of itself does not warrant operative therapy. Rather, the severity of coexistent coronary artery stenosis is the principal factor in deciding whether to proceed with surgical treatment in patients with CAAs.

Patients not managed surgically must nevertheless be monitored very closely and treated with antiplatelet and anticoagulation therapy to prevent thrombus formation within an aneurysm. Our standard practice is to follow up with these patients every 3 months, and we instruct them to report any symptoms that they have experienced in the interim.

## References

1. Robinson FC. Aneurysms of the coronary arteries. *Am Heart J* 1985; 109:129–35. [PubMed]
2. Daoud AS, Pankin D, Tulgan H, Florentin RA. Aneurysms of the coronary artery. Report of ten cases and review of literature. *Am J Cardiol* 1963; 11:228–37. [PubMed]
3. Baman TS, Cole JH, Devireddy CM, Sperling LS. Risk factors and outcomes in patients with coronary artery aneurysms. *Am J Cardiol* 2004; 93:1549–51. [PubMed]
4. Rath S, Har-Zahav Y, Battler A, Agranat O, Rotstein Z, Rabinowitz B, Neufeld HN. Fate of nonobstructiveaneurysmatic coronary artery disease: angiographic and clinical follow-up report. *Am Heart J* 1985; 109:785–91. [PubMed]

\*\*\*\*\*

### How to cite this article:

Mohammed Abiduddin Arif et al.2016, Bilobed Distal Lad aneurysm- A Rare Case Report. *Int J Recent Sci Res.* 7(10), pp. 13662-13663.