



ISSN: 0976-3031

Available Online at <http://www.recentscientific.com>

CODEN: IJRSFP (USA)

*International Journal of Recent Scientific Research*  
Vol. 9, Issue, 7(E), pp. 28070-28073, July, 2018

**International Journal of  
Recent Scientific  
Research**

DOI: 10.24327/IJRSR

## Research Article

# ROLE OF ORTHODONTIST-INTERDISCIPLINARY SURGICAL MANAGEMENT IN SMILE - CHIN AESTHETICS

**Renuka A Patel., Swati K Khonde., Falguni N Mehta and Karishma K Raval**

Department of Orthodontics and Dentofacial Orthopedics, Government Dental College and Hospital,  
Ahmedabad, Gujarat

DOI: <http://dx.doi.org/10.24327/ijrsr.2018.0907.2387>

### ARTICLE INFO

#### Article History:

Received 15<sup>th</sup> April, 2018  
Received in revised form 7<sup>th</sup>  
May, 2018  
Accepted 13<sup>th</sup> June, 2018  
Published online 28<sup>th</sup> July, 2018

### ABSTRACT

This case report describes the successful treatment of a patient with retropositioned chin with skeletal Class I malocclusion and convex profile by esthetic driven surgical planning combined with orthodontic approach. After 9 months of presurgical orthodontic treatment, antero-superior sliding genioplasty for chin morphology improvement and V/Yplasty for upper lip to decrease gummy smile was performed and significant improvement in facial appearance, masticatory function and occlusion was discernible.

#### Key Words:

Sliding genioplasty, retropositioned chin,  
convex profile, gummy smile

**Copyright © Renuka A Patel et al, 2018**, this is an open-access article distributed under the terms of the Creative Commons Attribution License, which permits unrestricted use, distribution and reproduction in any medium, provided the original work is properly cited.

## INTRODUCTION

The face is balanced when the superior, middle and inferior thirds are approximately equal in size and the structures within each segment are proportional in size and prominence. Anatomically, the chin is the area below the labiomental fold. A variety of methods are used for correction of retrognathic chin including chin augmentation such as by autologous and alloplast materials and also by using distraction or by osteotomy for anterior mandibular advancement. Genioplasty, the alteration of the chin through either osseous manipulation or implant augmentation, is an integral component of aesthetic surgery of the face. When performed with proper preoperative assessment and technical execution, the results can harmonize and restore balance between skeletal, soft tissue, and dental components of the lower face. To this end, proper understanding of the underlying anatomy and the changes associated with movement of the chin, alone or in conjunction with formal orthognathic surgery, is paramount. The horizontal sliding osteotomy was first described by Hofer in 1942. He used an extraoral incision through which a horizontal osteotomy of the anterior half of the inferior border was completed. Following advancement, transosseous sutures were used for stabilization of the mobilized fragment. Converse in 1950, discussed the feasibility of bone grafts introduced

through intraoral approaches.[1] Trauner and Obwegeser in 1957 used the horizontal osteotomy through an intraoral incision with degloving of the anterior mandible.[2] Hinds and Kent in 1969 were the first to realize and discuss the importance of maintaining the soft tissue attachment along the inferior segment and the role of these attachments in achieving maximal soft tissue change. The position of chin is important in establishing correct facial proportion. The chin gives the appearance of strength of face. Facial balance is critical for good facial esthetics. Surgery of the chin has been used for decades to achieve a balance of the lower third of the face. This balance is vital in the establishment of an acceptable esthetic outcome. Horizontal osteotomy for chin augmentation is an old and established procedure while medpore has become popular in the recent years for facial skeletal augmentation. The present case has been treated with antero-superior sliding genioplasty to avoid complications of medpore and osseous augmentation in genioplasty procedure.

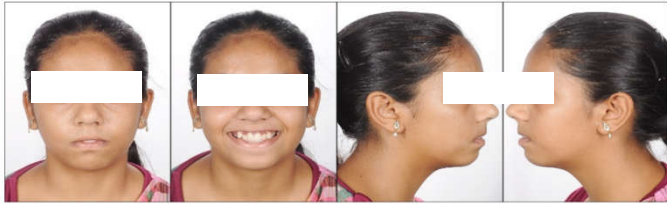### Case Report

A 14 year old hindu female patient came with the chief complain of backwardly placed lower jaw in department of Orthodontics and Dentofacial Orthopedics in Government Dental College and Hospital Ahmedabad.

\*Corresponding author: **Renuka A Patel**

Department of Orthodontics and Dentofacial Orthopedics, Government Dental College and Hospital, Ahmedabad, Gujarat

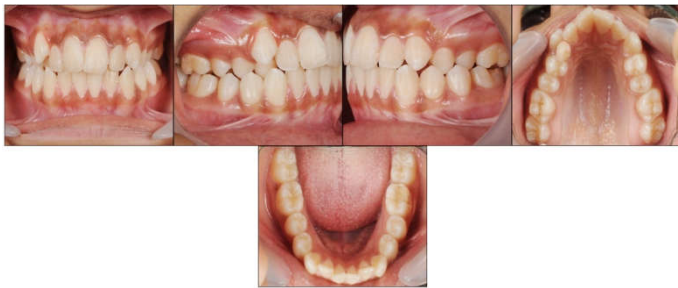**Pre Treatment Extraoral Photographs**



**On clinical evaluation extra orally patient has**

- Convex profile
- Repositioned chin
- Hyperactive mentalis muscle activity
- Leptoprosopic face
- Potentially competent lips.

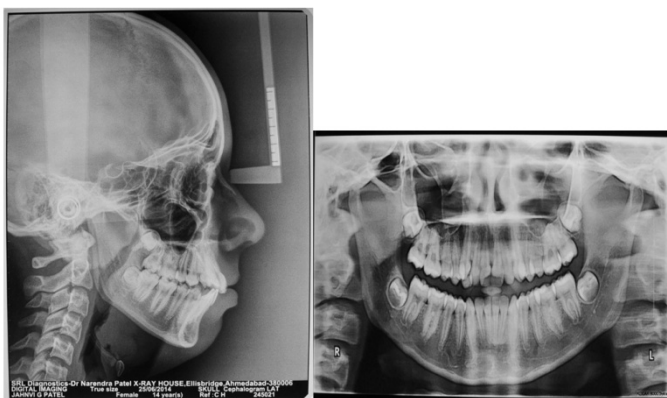
**Pretreatment Intraoral Photographs**



**Intraoral clinical findings revealed**

- Angle's Class I molar and canine relationship bilaterally
- Over retained buccally placed upper right deciduous canine
- Mild crowding was present in upper and lower anteriors
- Overjet is 8mm and overbite is 3 mm
- Lower dental midline is shifted by 2mm towards left in relation to upper midline
- Cross bite present in maxillary premolar region bilaterally

**Pre Treatment Cephalogram And OPG**



**Cephalometric Analysis**

Hard tissue parameters			
	Normal value	Pre rx	Present
SNA	80	79	80
ANB	2-4	1	4
Facial angle	82-95	87	87 *
Nasion Perpendicular to A	0±2	0mm	2mm
Nasion Perpendicular to Pog	0±4mm	-8mm	-5mm

	Small : 20-23	30mm	27mm
Max- Mand differential	Med : 27-30		
	Large : 30-33		
Facial Axis angle	90	85	87
Growth Axis		69	69
Y axis	53-66	60	61
SE	22	12	19
Z angle	80±9	57	63
ANB	4	3	2
	Pre treatment	Pre surgical	Post treatment
Beta Angle	34	33	35
W Angle	54	54	56
Yen Angle	119	119	122
App-Bpp	8	8	4
Wits	-4	-5	-6

N ⊥ Pog	-5mm	-4mm	-5mm
N-A-Pog	7°	6°	0°
N-A (HP)	-1mm	-1mm	0mm
N-B(HP)	-7mm	-6mm	-1mm
N-Pog (HP)	-10mm	-7mm	0mm*
N-ANS ( HP)	50mm	48mm	47mm *
ANS-Gn( HP)	64mm	65mm	63mm *
PNS-N( HP)	51mm	50mm	48mm
PNS-ANS(HP)	51mm	49mm	49mm
Go-Pog(linear)	70mm	67mm	70mm *
B-Pog(MP)	5mm	4mm	7mm *
<b>Bjork's sum</b>	<b>393°</b>	<b>393°</b>	<b>390°</b>
Jaraback's ratio	64.65%	65.21%	67.85%
Mandibular base length	70mm	67mm	70mm *
Maxillary base length	45mm	44mm	44mm *

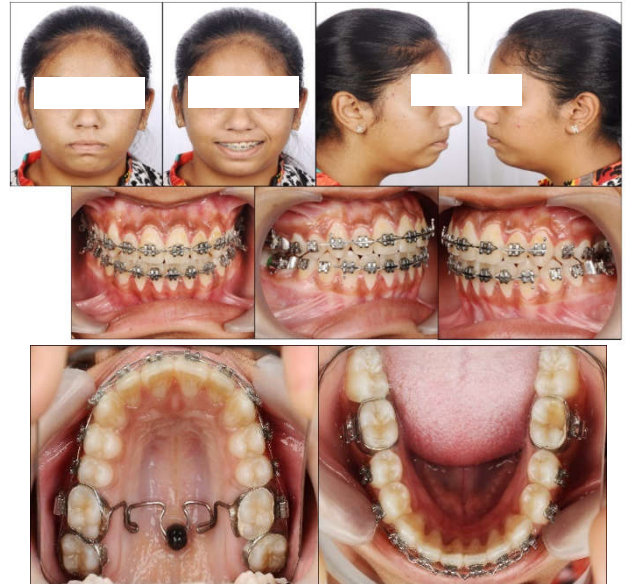
Soft tissue parameters			
Labio-Mental fold	130	131	136 *
Lip chin throat angle	110±8	145	142 *
Submandibular length	42±6mm	30	32*
Upper lip length	20±2mm	20	21 *
Lower lip/chin length	40±2mm	48	43 *
Upper lip : lower lip / chin length	1:2	1:1.5	1:2 *
Chin prominence	0±2mm	1mm	8mm *
Mandibular plane angle	32	34	33 *
Facial contour angle	-13±4	-20	-21 *
	Upper lip : 4mm behind	U:-2	U:-2 *
E line	Lower lip : 2mm behind	L:7	L:3
	U : 0mm	U:0mm	U:0mm *
S line	L : 0mm	L:4mm	L:5mm
Chin thickness	10-12mm	14mm	11mm *

Mx 1 to Mx occlusal plane	52°	56°	55° *
Md 1 to Md occlusal plane	63°	59°	62° *
Mx 1 exposure	3mm	6mm	0mm *
Overjet	4mm	2mm	1mm
Overbite	3mm	2mm	1mm
Upper lip thickness	10mm	12mm	9mm *
Lower lip thickness	12mm	13mm	9mm
Pog-pog'	14mm	13mm	13mm *
Me-me'	7mm	7mm	7mm
Nasolabial angle	127°	117°	132° *
Upper lip length	21mm	22mm	25mm *
Interlabial gap	3mm	9mm	0mm *
Lower lip length	45mm	40mm	42mm *
Lower 1/3 <sup>rd</sup> height	69mm	70mm	67mm *
Maxillary height	23mm	25mm	25mm

**On cephalometric evaluation**

- Patient has Class I skeletal base pattern(ANB-4°,Beta angle-34°,W angle-54°,Yen angle-119°)

- Proclined upper and lower anteriors(1 to NA-29°, 7mm and 1 to NB-30°, 8mm)
- Average growth pattern (Y axis-60°, Jaraback's ratio- 64.65%)
- Convex soft tissue profile (N-A-Pog- 7°)
- Retropositioned chin(Nasion Perpendicular to Pog,SE, N-Pog (HP), Go-Pog(linear), B-Pog(MP), ANS-Gn, Mandibular base length, Lower lip/chin length, Upper lip : lower lip / chin length, Chin prominence, E line, S line, Chin thickness, Pog-pog', Me-me')



**Problem List**

**Dentoalveolar Problems**

- Increased overjet and overbite
- Crossbite in maxillary premolar region
- Crowding in maxillary and mandibular arch
- Rotation of individual teeth
- Proclined upper and lower anteriors

**Soft tissue Problems**

- Convex soft tissue profile
- Retropositioned chin

**Diagnosis**

Angle's Class I molar relation bilaterally superimposed on skeletal Class I with orthognathic maxilla and retropositioned chin; on average growth pattern, with Class I canine relation on left side with proclined maxillary and mandibular anterior teeth, increased overjet and overbite, crowding in maxillary and mandibular arch, crossbite in maxillary premolar region, convex profile with leptoprosopic face, gummy smile with increase incisor exposure, potentially competent lips, hyperactive mentalis activity and obtuse nasolabial angle.

**Treatment Objectives**

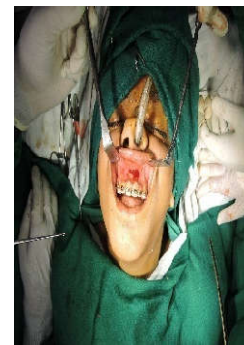- To maintain Class I skeletal jaw bases
- To maintain Angle's Class I molar relation
- To achieve and maintain Angle's Class I canine relation
- To achieve ideal inclination of U/L anteriors
- To achieve ideal overjet and overbite
- To relieve crowding in maxillary and mandibular arches
- To correct rotations of individual teeth
- To improve facial esthetics by improving chin position
- To improve smile esthetics

**Treatment Plan**

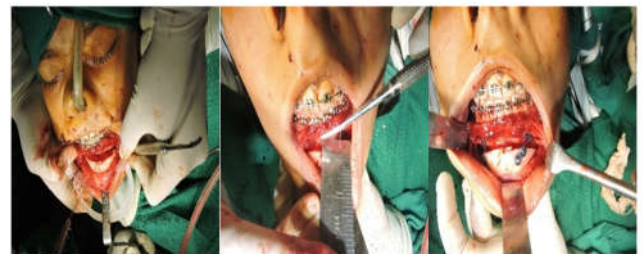- **Phase I (Orthodontic Phase):** extraction of overretained right deciduous canine followed by fixed mechanotherapy (0.022MBT) pre adjusted edgewise mechanotherapy.
- **Phase II (Surgical Phase):** Osseous antero-superior sliding genioplasty and V/Y plasty for upper lip to improve gummy smile by lip lengthening followed by finishing and detailing.

**Pre Surgical photographs after Orthodontic Treatment**

**Photographs of Surgical Procedure**

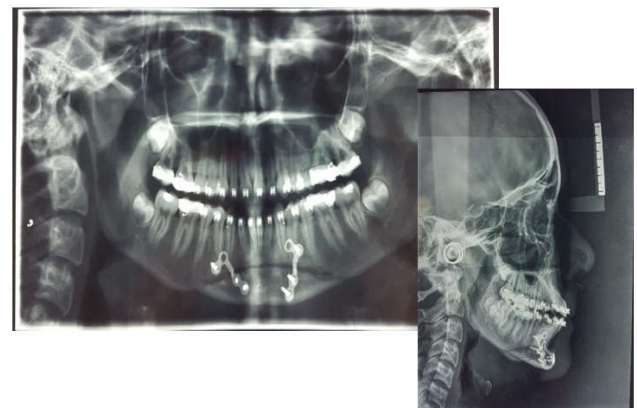


**V/Y Plasty in Upperlip**

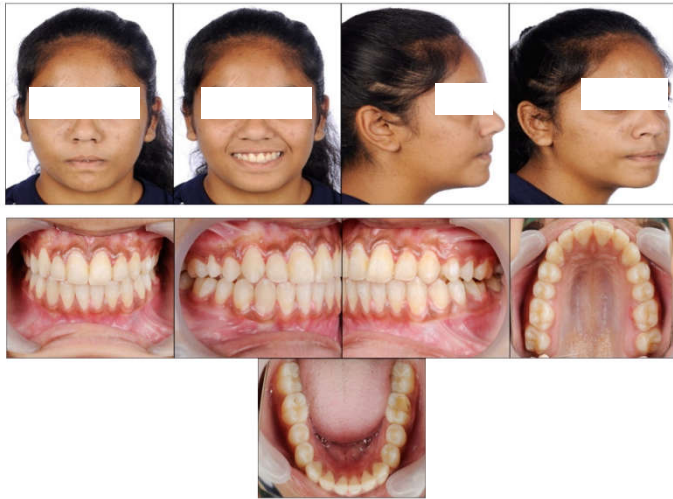

**Osseous Anterior Superior Sliding Genioplasty**

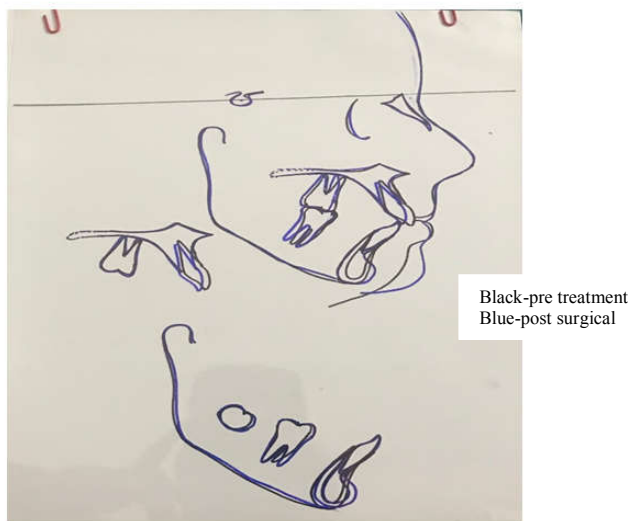
**After Surgical Procedure - Radiographs**



**Post Treatment Photographs - After Surgical Phase**



**Superimposition- Pre Treatment and Post Surgical**



### Treatment Progress

**Phase I Orthodontic phase:** Fixed mechanotherapy (0.022 MBT with 0° canine torque) was selected  
Wire sequence:

1. 0.016 Niti was given for 2months.
2. 0.017x0.025 Niti wire was given for 2 months.
3. 0.017x0.025 SS wire was given for 6 weeks then modified Transpalatal arch with bead and L loop was cemented for correction of cross bite in relation to 2<sup>nd</sup> molar and sliding mechanics was used for space closure.
4. 0.019x0.025 HANT wire with cinch back by annealing the distal end of the wire for 3 weeks.
5. 0.019x0.025 SS wire was given and continued during surgical phase.

**Surgical phase:** Surgical procedure was done by team of oral surgery department at government dental college and hospital, Ahmedabad.

1. Osseous Antero-superior Sliding Genioplasty was done with 7mm anterior advancement and 2 mm superior position of chin.
2. Upper Lip surgery (V/Yplasty) to reduce gummy smile and incisor exposure

**Postsurgical:** upper lip stretching and blowing exercise was recommended to improve lip tonicity and lip seal.

**Orthodontic phase with finishing and detailing:** Upper and lower 0.018 SS round wire with Class II settling elastics for 6 weeks was given.

Fixed appliances were removed and upper and lower Begg's retainer was delivered.

### DISCUSSION

Osseous genioplasty is highly versatile that can allow movement in all 3 dimensions. Osseous genioplasty when performed in isolation or as a component of formal orthognathic surgery is an integral component of aesthetic alteration of face. When executed with preoperative assessment, stable results can harmonize and restore balance between skeletal, soft tissue and dental component of lower face. So, with proper knowledge and understanding of underlying dysmorphology, diagnosis and treatment planning along with surgical technique by orthodontist plays a vital role for facial esthetics enhancement.

Genioplasty primarily has been used to achieve a sliding advancement of the inferior mandibular border for the correction of microgenia. Alloplastic Augmentation, the use of alloplasts affords the possibility of not only AP augmentation but also vertical and more importantly lateral augmentation. Some unwanted sequelae associated with the use of alloplastic materials are poor chin contour, resorption of bone and occasionally teeth under the implant, mobility to palpitation, both early and late infection and noninfectious inflammatory responses and unpredictable soft tissue response. Orthognathic surgery is time consuming and not all patients will be willing to undertake it. Upper Lip V/Y plasty surgery is done to reduce gummy smile for facial aesthetic enhancement. It doesnot alter the lip morphology. Botox is also used to reduce gummy smile but it isnot indicated in young individual because of neurotoxicity and the result is temporary for 4-5 months only.

### CONCLUSION

Osseous antero-superior sliding genioplasty combined with V/Y plasty can make significant difference in facial esthetics with stable results and high patient's satisfaction. So, Antero-superior sliding genioplasty is a safe and effective means of creating esthetic changes by producing alterations in the chin morphology with no complications. V/Y plasty lip surgery to decrease gummy smile without altering lip morphology is a good alternative to enhance smile esthetics. In recent years, there has been shift in esthetic driven orthodontic diagnosis and treatment planning paradigm from conventional treatment planning. Each and everyone is unique in their facial esthetics and proportions. So, each patient's desires and goals should be considered.

### Reference

1. Aesthetic Alteration of the Chin Edward I. Lee, MD1 1 Division of Plastic Surgery, Michael E. DeBakey Department of Surgery, Baylor College of Medicine, Houston, Texas *Semin Plast Surg* 2013;27:155-160.
2. Clinical Facial Analysis Elements Principles and Techniques Fabio meneghini Medical Illustration by Massimiliano Crespi Springer-2005.