



ISSN: 0976-3031

Available Online at <http://www.recentscientific.com>

CODEN: IJRSFP (USA)

*International Journal of Recent Scientific Research*  
Vol. 10, Issue, 01(D), pp. 30402-30405, January, 2019

**International Journal of  
Recent Scientific  
Research**

DOI: 10.24327/IJRSR

## Research Article

### FACIAL ASYMMETRY CORRECTION OF CLASS III PATIENT USING STEREOGRAPHIC MODEL ASSESSMENT-A CASE REPORT ON THE TECHNIQUE

**Kaushik Prakash., Ratna Parameswaran., Sanjay Sundararajan.,  
Devaki Vijayalakshmi and Arani Nandakumar**

Department of Orthodontics and Dentofacial Orthopaedics, Faculty of Dental Sciences,  
Meenakshi Academy for Higher Education and Research, Chennai, India

DOI: <http://dx.doi.org/10.24327/ijrsr.2019.1001.3052>

#### ARTICLE INFO

##### Article History:

Received 13<sup>th</sup> October, 2018  
Received in revised form 11<sup>th</sup>  
November, 2018  
Accepted 8<sup>th</sup> December, 2018  
Published online 28<sup>th</sup> January, 2019

##### Key Words:

Stereolithographic model, class III  
skeletal base, facial asymmetry,  
orthognathic surgery

#### ABSTRACT

Management of facial asymmetry poses as a challenge to many orthodontists due to the topographic intricacies of the various facial structures. Traditional manual model of surgery, though an essential aid to treatment planning can be time consuming, complicated and may leave place for potential errors. Stereolithographic model using three- dimensional approach is a revolutionary change in the field of facial asymmetry management. The aim of this study was to use stereolithographic model for orthognathic-surgical treatment of a patient with facial asymmetry having class III skeletal base. A 14-year old female patient presented with a class III skeletal base with hemi mandibular elongation. Stereographic models were designed from the CT scan of each patient. The images were reformatted into three- dimensional plane using these models. Extraction of impacted third molars in the osteotomy site followed by extraction of upper first premolars were planned for the orthodontic part of the treatment. Le forte I maxillary impaction of 4 mm with jaw correction and Bilateral sagittal split osteotomy setback of 5 mm was planned for the surgical part in the virtual surgical wafer. The jaw procedures were performed in accordance with the virtual plan. A 5-year follow-up showed remarkable improvement in the facial asymmetry of the patient with stable occlusion. This complicated case therefore highlights the advantages of rapid prototyping using CT images for the production of stereolithographic models for a better and more precise correction of facial asymmetries.

**Copyright © Kaushik Prakash et al, 2019**, this is an open-access article distributed under the terms of the Creative Commons Attribution License, which permits unrestricted use, distribution and reproduction in any medium, provided the original work is properly cited.

#### INTRODUCTION

The facial beauty is a result of symmetry and proportionality between different facial structures.<sup>1</sup> There exists minor facial asymmetry in all individuals and even in those considered to be aesthetically attractive, is usually considered subclinical<sup>2,3</sup>. The point at which these subclinical changes become gross facial asymmetry depends on the patient's sensitivity and clinicians ability. Treatment approaches for facial asymmetries are through orthopaedics, orthodontics, orthognathic surgery or a combination of these.

Treatment Planning of such patients with gross facial asymmetry requires high levels of predictability. Traditional evaluation through clinical assessment, photographs and radiographs were inconclusive because of limited value in interpreting the region of the asymmetry. Treatment planning of an asymmetric case requires three-dimensional consideration

in the sagittal, coronal and horizontal planes because complex three-dimensional (3D) structures are being projected onto two-dimensional (2D) planes, Which led to the implementation of the three-dimensional approach for treatment planning by rapid prototyping using stereolithographic models for an enhanced predictability of treatment outcomes. The use of rapid prototyping based on stereolithography to construct skeletal models was initially reported by Mankovich *et al.* in 1990 (4). More recently this technology has been widely used as an aid in dentistry for orthognathic and cranio-maxillofacial surgery (5,6), Traumatology (7), dental implantology. This case report illustrates the use of rapid prototyping using stereolithographic model for orthognathic-surgical treatment of a patient of class III skeletal base with facial asymmetry due to heme-mandibular elongation. The stereolithographic model was instrumental in extensive treatment planning. Also, we present excellent follow-up of the case up to 5-years.

\*Corresponding author: **Kaushik Prakash**

Department of Orthodontics and Dentofacial Orthopaedics, Faculty of Dental Sciences, Meenakshi Academy for Higher Education and Research, Chennai, India

## CASE REPORT

### Diagnosis and Etiology

A 14-year-old female reported with a complaint of facial asymmetry and eating difficulties reported in our Department of Orthodontics & Dentofacial orthopaedics. The patient had a dolichocephalic head and leptoprosopic facial type, positive smile; displays 60% of the upper tooth crowns. The patient presented a concave profile and anterior divergence, gibbous nose, acute nasolabial angle and lip incompetence. Extraoral clinical examination in the frontal plane revealed gross facial asymmetry confined to the lower third of the face. The chin deviated to the left side with a relative 'fullness' on the same side and a relative 'flatness' on the contralateral side. Profile view showed a skeletal class III profile. Patient's intra-oral examination revealed lower midline rotation to the right cross bite was present. In the sagittal plane, Class III molar and the canine relationship was noted on the right and left sides. There were non-coincident dental midlines with mandibular dental midline, and the mentum deviated to the left 3 mm and 6 mm, respectively. There was also overbite of 1mm and differential overjet of +2mm on the right and -2mm on the left sides.

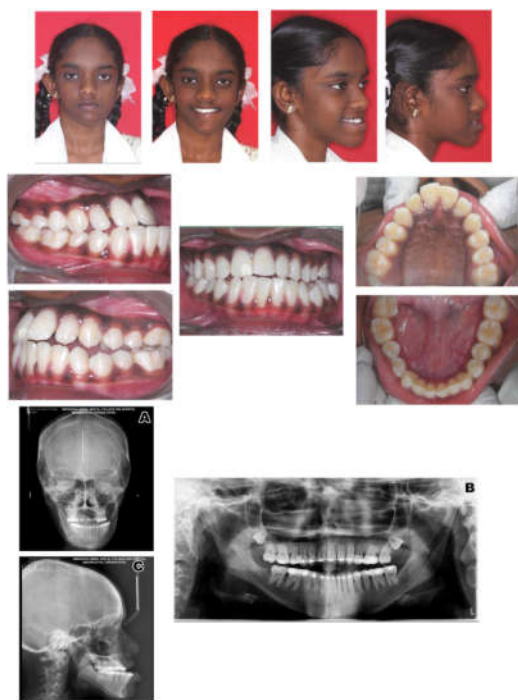

FIG.1 - Pre-treatment records

The cephalometric analysis presented a skeletal Class III pattern with an essential vertical component, as displayed by these cephalometric measures: ANB=-3°, WITTS= -6,5 mm, SN.GoGn= 35° and FMA= 28°. Analysis of the posteroanterior radiograph revealed mild maxillary deviation of 0.5 mm to the right side and mandibular deviation of 6 mm to the left side. The panoramic radiograph showed the presence of developing third molars.

Based on these findings she was diagnosed as 'Angle's dentoalveolar class III malocclusion on an asymmetric class III skeletal base with orthognathic maxilla and prognathic mandible on a high mandibular plane angle and increased lower anterior facial height with proclaimed upper and lower

anterior and unilateral posterior crossbite on left side with a probable aetiology of Hemi-mandibular elongation on the right side'.

The objectives of the treatment were

Correction of Facial asymmetry and achieving ideal soft tissue profile.

Correction of crossbite and establishing ideal overjet and overbite.

Also, achieving stable and functional molar relationship with class I canine relationship.

### Treatment Plan & Alternatives

The stereolithographic models were prepared from the CT of each slice 1mm. The following treatment options were laid out to the patient after evaluating the stereolithographic model:

An ideal treatment plan consisting of orthodontic treatment combined orthognathic surgery in the maxilla and mandible, with the extraction of maxillary first premolars. Surgical part included Le forte I maxillary impaction of 4 mm with yaw correction and Bilateral sagittal split osteotomy setback of 5 mm. The second was a compensatory Orthodontic treatment Involving extractions of mandibular first premolars alone, but considering the severity the second plan was a suboptimal one and patient opted for the orthodontic - orthognathic approach.

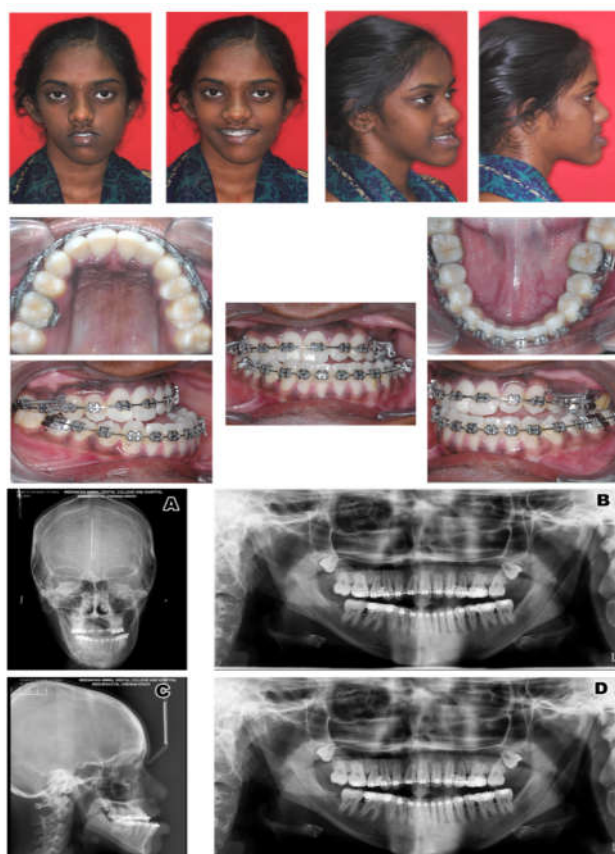


FIG.2 - Pre-surgical records

### Treatment progress

#### Pre-surgical phase

Extractions of impacted third molars found in the osteotomy site are carried out. Extractions of upper first premolars were

performed to decompensate the malocclusion. Pre-surgical orthodontics begun with the bonding of 0.022 MBT pre-adjusted edgewise appliance. Alignment started using 0.016" superelastic NiTi archwires. After initial alignment, 0.019 x 0.025" upper and lower nitinol archwires were placed to align further and level the arches. In the next appointment after two months, space closure was initiated using 0.019 x 0.025" upper and lower stainless steel archwires. The retraction was done using frictionless mechanics. After the incisors are placed in their ideal positions in their alveolar processes, and negative overjet was obtained, 0.021 x 0.025" upper and lower nitinol archwires were placed. Then 0.021 x 0.025" TMA upper and lower coordinated archwires were placed. In the end, 0.021 x 0.025" stainless steel upper and lower coordinated archwires were placed as stabilising archwires. The study models were taken to check the coordination of the arch. The surgical splint preparation was carried on before surgery as a part of final surgical planning.

**Surgical Phase**

The surgical phase began with Le forte I maxillary impaction of 4 mm with yaw correction followed by bilateral sagittal split osteotomy for the setback of the mandible by 5 mm. The soft tissues of the cheek and lower border of the mandible were pulled upward from the periosteum to prevent the soft tissues of the affected side from hanging loosely after the operation. Stabilization was done using rigid internal fixations.

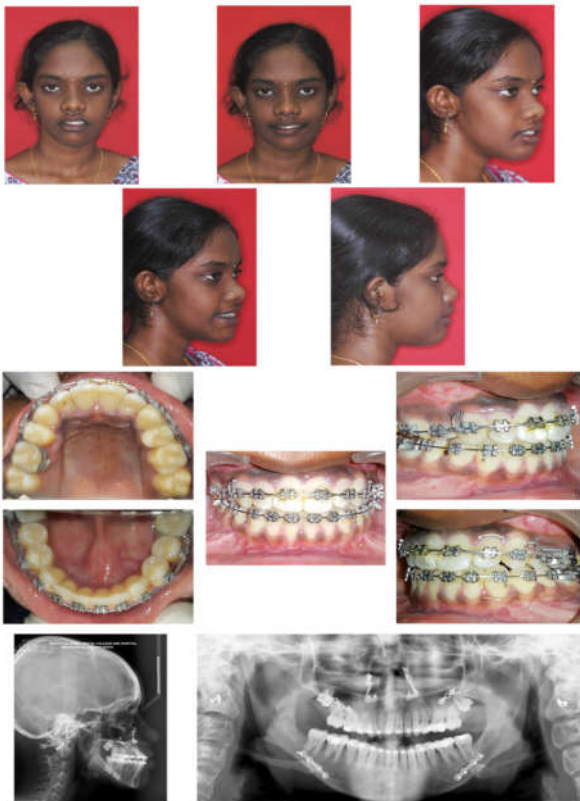

FIG.3 - Immediate Post-surgical records

**Post Surgical**

The patient was reviewed after six weeks of surgery. Stabilization archwire was removed and replaced with upper and lower 0.019 x 0.025" TMA wires. Following settling, the

appliance was debonded after 2weeks and upper & lower Begg's wraparound retainers were given.

Postoperative lateral cephalogram was taken and superimposed with preoperative lateral cephalogram. Frontal and profile photographs showed a remarkable difference in the patient.

**RESULTS**

The treatment concluded by 24 months, by which mandibular prognathism and asymmetry were eliminated, and facial esthetics has considerably improved the profile was enhanced. An overall improvement in facial harmony as a result of the decrease of the lower facial third. The cephalometric values indicate of changes post surgery Table1 achieving a skeletal class I, straight profile, a confident smile thus providing facial balance and harmony of the soft tissues.

The intra-oral changes obtained post-treatment, as shown in Fig. illustrates class I molar relationship and canine relationship with adequate intercuspation and normal overjet and overbite with coincident upper midline. The crossbite which existed pretreatment was corrected thus leaving a stable occlusion. The dental midlines were coinciding, and arch form was improved dental inclinations were enhanced thus establishing good root parallelism.

The retainer phase began with Begg's wrap-around in maxillary dentition and Fixed lingual retainers in the mandible with the aim of enhancing occlusal settlement and control muscle strength. A 5-year follow-up shows good retention. However, a limited amount of relapse is seen which might be due to the inherent growth potential often associated with class III skeletal base.

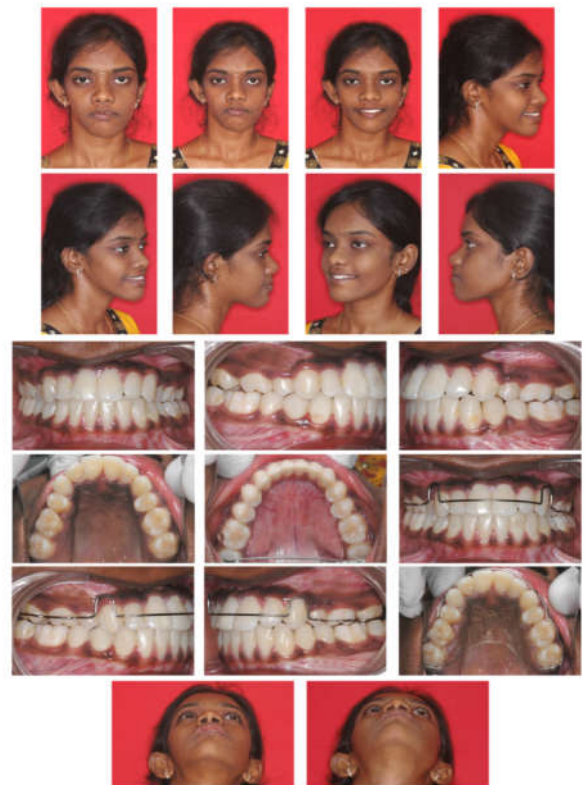

FIG.4 - Post treatment records

## DISCUSSION

It is essential to understand the components of facial asymmetry to outline an accurate and effective treatment plan (8,9). The analysis of postero-anterior, submento-vertex, lateral cephalograms or opg radiographs is often deemed inconclusive in understanding if the asymmetry is related to the maxilla, mandible or both, in the sagittal or transverse directions, and if the anomaly is also associated with dental compensations (10,11). The Current three-dimensional computed reconstruction allows elaboration of realistic and spatially accurate images for diagnosis and surgical planning. The manipulation of these images allows the construction of physical model called Stereolithography which used in our case of an asymmetric facial correction. The most significant advantage stereolithography is the full understanding of bony anatomy before surgery (12). This process reproduces the computerised tomography and the magnetic resonance data with fidelity and with a maximum error of 0.1 mm, yielding highly accurate stereolithographic models as in our case (13). The stereolithographic model of the patient presented significant facial asymmetry with occlusal plane inclination, mandibular asymmetry and mentum deviation to the left. Haraguchi *et al.* (14) and Severt and Proffit (15) have reported that in patients with dentofacial deformities with mandibular deviation, lateral excursion to the left was present in over 85% of the studied population. According to Haraguchi *et al.* (14), the mandible is more asymmetrical than the maxilla because of its higher growth potential. While the mandible is a movable bone, the maxilla rigidly connects to the adjacent skeletal structures through sutures and synchondroses.

Also, the model highlights narrow maxilla associated with posterior crossbite in the left side. According to Haraguchi *et al.* (14), it is difficult to determine if the posterior crossbite is a consequence of narrow maxilla or if it merely results from the mandibular deviation. In the present case, posterior crossbite correction is done by incorporation of yaw during surgery. The maxillary right and left first premolars were extracted to correct the maxillary midline, dental compensations and negative dentoalveolar discrepancy. The inclination of the mandibular teeth was increased to promote satisfactory postsurgical interincisal relationship. The objectives of the presurgical orthodontic treatment were achieved, and only small corrections were necessary after surgery, obtaining adequate intercuspation and pleasant facial esthetics. Twenty four months after removal of the orthodontic appliance, the treatment can be considered as successful. The goals of the orthodontic-surgical treatment, namely having coincident the maxillary and facial midlines, correlating the mentum with the sagittal midline, leveling the lip commissures, giving symmetric appearance to the maxillary canines, aligning and leveling the maxillary and mandibular teeth, and obtaining ideal anteroposterior, transverse and vertical occlusion, overjet and overbite, were wholly achieved. When the skeletal problem compromises the facial esthetics, the surgical-orthodontic treatment is the most indicated for patients who do not present facial growth potential and mainly for those who have facial asymmetry. A correct diagnosis and planning, as well as an appropriate execution of the treatment plan, are determinant factors for having success and long-term stability. In the case presented in this report, the orthodontic-surgical treatment was well

indicated for correction of the Class III skeletal malocclusion and the patient's facial asymmetry, proving adequate masticatory function and pleasant facial esthetics.

## CONCLUSION

We conclude that rapid prototyping using CT images for production stereolithographic models allows the understanding of anatomic details with high quality, simulating surgical procedures, and producing and adapting biomaterials (plates, screws, prosthesis). It also reduces surgical time and morbidity. However, the main disadvantage is the availability of equipment and the high cost.

## References

1. Lines PA, Lines RR, Lines CA. Profile metrics and facial esthetics. *Am J Orthod Dentofacial Orthop* 1978; 73:648-57.
2. Peck S, Peck L, Kataja M. Skeletal asymmetry in esthetically pleasing faces. *Angle Orthod* 1991; 61(1):43-8.
3. Cohen MM Jr. Perspectives of craniofacial asymmetry. Part III. Common and/or well known causes of asymmetry. *Int J Oral Maxillofac Surg* 1995; 24:127-33.
4. Mankovich NJ, Cheeseman AM, Stoker NG. The display of three dimensional anatomy with stereolithographic models. *J Digital Imaging* 1990; 3:200-03.
5. Anderl H, Zur Nedden D, Muhlbauer W. CT-guided stereolithography as a new tool in craniofacial surgery. *Br J Plast Surg* 1994; 47:60-4.
6. D'urso PS, Barker TM, Earwaker WJ, Bruce LJ, Atkinson RL, Lanigan MW, *et al.* Stereolithography biomodelling in cranio-maxillofacial surgery: a prospective trial. *J Craniomaxillofac Surg* 1999; 27:30-37.
7. Kermer C, Rasse M, Lagogiannis G, Undt G, Wagner A, Millesi W. Colour stereolithography for planning complex maxillofacial tumour surgery. *J Craniomaxillofac Surg* 1998; 26:360-362.
8. Hayashi K, Muguruma T. Morphologic characteristics of the dentition and palate in cases of skeletal asymmetry. *Angle Orthod* 2004; 74:26-30.
9. Ko EW, Huang CS, Chen YR. Characteristics and corrective outcome of face asymmetry by orthognathic surgery. *J Oral Maxillofac Surg* 2009; 67:2201-09.
10. Van Elslande DC, Russett SJ, Major PW, Flores-Mir C. Mandibular asymmetry diagnosis with panoramic imaging. *Am J Orthod Dentofacial Orthop*. 2008;134(2):183-92
11. Pirttiniemi P, Miettinen J, Kantomaa T. Combined effects of errors in frontal-view asymmetry diagnosis. *Eur J Orthod* 1996; 18(6):629-36.
12. McGurk M, Amis AA, Potamianos P, Goodger NM. Rapid prototyping techniques for anatomical modelling in medicine. *Ann R Coll Surg Engl* 1997; 79:169-174.
13. Nikzad S, Azari A. A novel stereolithographic surgical guide template for planning treatment involving a mandibular dental implant. *J Oral Maxillofac Surg* 2008 Jul; 66(7):1446-54.
14. Haraguchi S, Takada K, Yasuda Y. Facial asymmetry in subjects with skeletal Class III deformity. *Angle Orthod* 2002; 72:28-35.