



ISSN: 0976-3031

Available Online at <http://www.recentscientific.com>

CODEN: IJRSFP (USA)

International Journal of Recent Scientific Research
Vol. 10, Issue, 04(C), pp. 31831-31833, April, 2019

**International Journal of
Recent Scientific
Research**

DOI: 10.24327/IJRSR

Research Article

COMPARISON OF CLINICAL OUTCOMES FOLLOWING THE USE OF A LASER DEEPITHELIALISED FREE GINGIVAL GRAFT / CONNECTIVE TISSUE GRAFT IN THE MANAGEMENT OF GINGIVAL RECESSION DEFECTS

**Purva Dalmia, Swarupa. Harinath Parthasarathy,
Anupama Tadepalli and Deepa Ponnaiyan**

Department of Periodontics, SRM Dental College and Hospital,
Ramapuram, Chennai-89

DOI: <http://dx.doi.org/10.24327/ijrsr.2019.1004.3346>

ARTICLE INFO

Article History:

Received 10th January, 2019
Received in revised form 2nd
February, 2019
Accepted 26th February, 2019
Published online 28th April, 2019

Key Words:

Connective Tissue, Gingival Recession,
Graft, Laser

ABSTRACT

Thickness, volume, histological compositions are the significant features influencing the success of connective tissue grafts (CTG). Laser assisted de-epithelialized gingival graft (DGG-L) is a novel graft harvesting technique quoted in literature, proposed to procure adequate collagen-rich connective tissue from lamina propria of the palatal mucosa. This case series aimed to compare the clinical outcomes following use of de-epithelialized gingival grafts DGG-L / conventionally harvested CTG along with coronally advanced flap (CAF) in management of gingival recession defects. 10 Miller's Class I / II gingival recession sites were randomly treated either with CAF+DGG-L or CAF+CTG. Results were expressed in terms of the mean root coverage%. At the end of 6 months, both the treatments resulted in 100% root coverage. Histological examination of grafts demonstrated that DGG-L composed of larger amounts of fibrous connective tissue and lower amount of fatty glandular layer compared to conventional CTG.

Copyright © Purva Dalmia, 2019, this is an open-access article distributed under the terms of the Creative Commons Attribution License, which permits unrestricted use, distribution and reproduction in any medium, provided the original work is properly cited.

INTRODUCTION

Gingival recession is the exposure of root surface resulting from apical migration of gingival margin. Different treatment modalities have been employed to attain root coverage in gingival recession. Complete coverage of the recession defect and integration of the new tissue with adjacent soft tissue is an essential component of periodontal therapy. Connective tissue grafts along with advanced flap are considered as the gold standard technique for root coverage procedures.^{1,2} The procedure of harvesting CTG from palate is often complicated.^{3,4,5,6} Comparison of various CTG harvesting techniques addressed histological composition of the graft as well as palatal wound healing. Zucchelli et al⁷ proposed CTG harvesting by scalpel de-epithelialization of gingival grafts (DGG) and noted that these grafts had relatively dense connective tissue and were comparatively prone for minimal postoperative shrinkage over conventionally harvested CTG.⁶ Further the author concluded that 2 mm a residual soft tissue covering the donor site resulted in limited pain and better post-operative wound healing.⁸ Diode lasers facilitate in situ de-epithelialization. *Yilmaz et al*⁹ have described several

advantages of an adjunctive use of diode laser application such as; reduced post-operative bleeding, shorter operating time, minimal swelling and better post-operative patient's perceptions. Limited reports were published in literature using Diode lasers for deepithelization of grafts. Hence, the current case series compares the clinical outcomes of the laser de-epithelialized gingival grafts with CTG harvested by single incision in management of isolated maxillary gingival recession defects.

Case Description

This pilot investigation was approved by institutional ethical committee and review board. Patients were recruited from outpatient clinics, department of periodontics and implantology from August 2017 to February 2018. 10 systemically healthy subjects diagnosed with chronic periodontitis, with a mean age of 25-50 years requiring surgical management of gingival recession were recruited and subjects were informed about the nature of the study and duly signed consent was obtained. Isolated maxillary recession sites belonging to either Miller's Class I / II criteria with adequate attached gingiva and

*Corresponding author: **Purva Dalmia**

Department of Periodontics, SRM Dental College and Hospital, Ramapuram, Chennai-89

vestibular depth were included. Exclusion criteria comprised of sites with periodontal pockets, interproximal bone loss, cervical caries/restorations, abrasion defects and malposed teeth, poor oral hygiene maintenance, contraindicated for periodontal surgery. The patients initially completed a phase I periodontal therapy, including oral hygiene instructions to eliminate habits related to the aetiology of the recession, scaling & root planning. The clinical parameters were recorded using a standardized acrylic stent and UNC-15 probe which included, Gingival recession depth (GRD), Gingival recession width (GRW), Root coverage percentage (RC%), Probing pocket depth (PPD), Clinical attachment level (CAL), Keratinized tissue width (KTW). Visual analog esthetic score (VAS-E) and Visual analog pain scores (VAS -P) were also evaluated.

Surgical Procedure: Sites were randomized by using chit method. Under local anaesthesia coronally advanced flap as described by Zucchelliet al was elevated.¹⁰ Root surface debridement was carried out using area specific currettes. Recipient site dimensions were arbitrarily measured using a periodontal probe. Graft harvesting was done as mentioned below. In test group, at the donor site de-epithelialization was done using soft tissue diode laser (810 nm) at a power setting of 1W in contact and continuous mode. The laser tip was passed from lateral to medial aspect to ensure the removal of all visible epithelium seen on the outer side of the predefined graft area. Care was taken to avoid direct contact of the laser with the palatal bone by placing the insert tip parallel to the mucosa. Capillary bleeding from the donor site ensured complete de-epithelialisation and further the required dimensions of the graft were procured.(FIGURE 1) In control group, connective tissue graft was harvested with the aid of 15-C blade from the palate using a single incision technique.¹¹ (FIGURE 2) The obtained grafts was trimmed to adequate thickness by removing excess fatty glandular tissue. The donor surgical site was approximated with simple interrupted loop sutures.

The DGG-L /CTG grafts were placed and adapted at the recipient sites and the flaps were coronally advanced and secured using 4-0 vicryl sutures. Coe pack was placed in order to protect the surgical site. Post operatively patients were prescribed with analgesics and recalled after 2wks for suture removal. Patients were reviewed at 1, 3 and 6months intervals. Healing was uneventful in all the patients without any post-operative complications. Clinical parameters were recorded at baseline and 6 months intervals.

Table 1 shows the mean descriptive parameters of groups at baseline and 6 months. Both test and control groups showed improved recession parameters from baseline to 6 months. With RH & RW, 3±1 & 4.2±0.6mm at baseline in test group and 3.2±0.74 & 4.8±0.4mm at baseline in control group and recession height and recession width reduced to 0 at post op 6 months. Both test and control groups achieved 100% root coverage at the end of 6 months. All the other clinical parameters showed similar trend between test and control groups. Mean VAS-E scores were 9.8±0.4 and 9.6±0.4 for test and control group respectively, at the end of 6 months.

Histological evaluation: For histological evaluation, a portion of the procured grafts i.e., 2×2mm of tissue blocks were sectioned from the grafts before transferring to recipient sites

and were examined using Masson-Goldner-Trichromestaining technique. The histological examination at 20x magnification demonstrated that harvesting technique greatly influences the composition of grafts. In particular, a de-epithelialized harvested FGG consisted mainly larger amounts of dense fibrous connective tissue and lower amount of fatty glandular layer compared to conventional CTG.

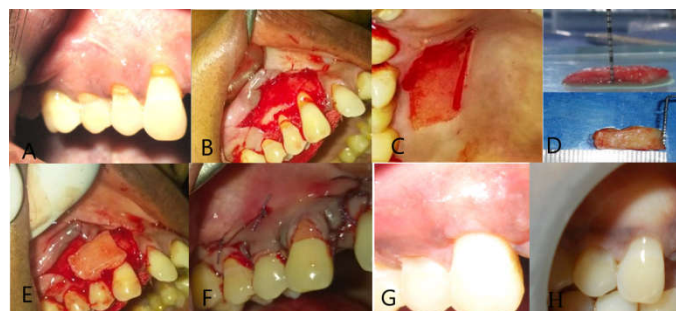


Figure 1 (a) Class 2 gingival recession in 13, (b) Coronally advanced flap procedure, (c) De-epithelialisation of donor site using laser, (d) DGG-L dimensions, (e) DGG-L adaptation at recipient site, (f) Flap advancement and approximation, (g) Review at 3 months and (h) Review at 6 months

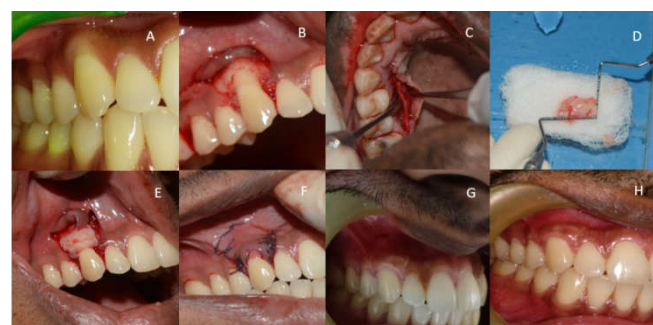

Figure 2 (a) Class 1 gingival recession in 13, (b) Coronally advanced flap procedure, (c) Connective tissue graft(CTG) harvesting, (d) CTG dimensions (e) CTG adaptation, (f) Flap advancement and approximation, (g) Review at 3 months and (h) Review at 6 months

Table 1 Descriptive Parameters Of Study Groups At Various Time Points

Parameter	Test	Control
Age	36.8±8.16	36.8±8.06
Gender	Male	4(80%)
	Female	1(20%)
Class of recession	Class i	4(80%)
	Class ii	1(20%)
Recession depth	Baseline	3±1
	6 mon	0
Recession width	Baseline	4.2±0.6
	6 mon	0
Root coverage percentage	6 mon	100%
Width of keratinised tissue	Baseline	3.4±0.7
	6 mon	5.2±0.4
Probing pocket depth	Baseline	1.8±0.4
	6 mon	1
Clinical attachment level	Baseline	4.8±0.9
	6 mon	1
Vas esthetic scores	6 mon	9.8±0.4
	1wk	3.8±1.6
Vas pain scores at donor sites	2wks	2±1
	4wks	0.3±0.4

DISCUSSION

Different SCTG harvesting techniques have been introduced over the years to retrieve an ideal quality and quantity of grafts.

According to Zucchelli et al,⁷ traditional CTG harvesting techniques are not recommended if the palatal soft tissue is not sufficiently thick because of the risk of primary flap necrosis or the insufficiency of the graft (due to the presence of a fatty and glandular tissue instead of a desirable connective tissue). DGG technique allows the incorporation of the portion of connective tissue closest to the epithelium into the graft. This tissue is dense, firmer, more stable. Therefore, the DGG is a harvesting technique designed to leave the deep portion of the submucosa and the periosteum excluded from the graft.

De-epithelialization of graft can be done using scalpel or using laser. De-epithelialization with a scalpel blade can be technique sensitive for an inexperienced clinician. The advantage of laser-aided de-epithelialization of FG is that it is done intraorally, before harvesting, and can be performed uniformly in a controlled manner. Similar to Zucchelli's graft requisites, one can harvest ideal donor tissue with minimal submucosa/adipose tissue.⁷ Thus, in the de-epithelialization was carried out using diode dental laser. The results of our study indicated that the DGG-L grafts were equally effective in treatment of gingival recession as with the control group. There were no differences in root coverage outcomes between groups at 6 months. So far in literature there were no studies comparing the clinical efficacy of DGGL/ conventional CTG. Hence, we couldn't associate our outcomes with other studies. Ozcelik et al⁸ in 2016 reported that the mean RC% obtained with de-epithelialization by using diode laser was 96.3% (6mon) which is in accordance with our test group. Cases reported by Jerry Ching, Yi Lin et al., 2018 using Er, Cr: YSGG de-epithelialization also resulted similar RC% at 9months (100%).¹² Therefore, it can be hypothesised that the epithelial removal by laser is effective and diode lasers can be used for this purpose. Efforts have been made to improve palatal healing and to decrease patient morbidity. Wang et al.¹³ evaluated the effect of diode light irradiation (DL) on the donor wound of FG in rats and reported that DL accelerated the wound closure and re-epithelialization on the palatal wound.

The limitations of the current investigation was that the donor site morbidity wasn't evaluated future studies were recommended to evaluate this parameter and the findings of this case series must be investigated by studies with alarger number of patients, longer follow-up.

CONCLUSION

Though there were no differences in clinical outcomes, histological specimens clearly demonstrated that harvesting technique influences the composition of grafts. In particular, a DE-harvested FG, i.e., from a more superficial aspect of the palate, consists mainly of the lamina propria that contains much larger amounts of fibrous CT and much lower amounts of fatty glandular layer compared to an harvested CTG. The predictability and effectiveness of DGG-L technique (epithelial removal) should be confirmed with long-term studies.

References

1. Cairo, F., Cortellini, P., Tonetti, M., Nieri, M., Mervelt, J., Pagavino, G. & Pini-Prato, G. P. Stability of root coverage outcomes at single maxillary gingival recession with loss of interdental attachment: 3-year

- extension results from a randomized, controlled, clinical trial. *J Clin Periodontol* 2015; 42, 575–581.
2. Tatakis, D. N., Chambrone, L., Allen, E. P., Langer, B., McGuire, M. K., Richardson, C. R., Zabalegui, I. & Zadeh, H. H. Periodontal soft tissue root coverage procedures: a consensus report from the AAP Regeneration Workshop. *J Periodontol* 2015; 86, S52–S55.
3. Griffin, T. J., Cheung, W. S., Zavras, A. I. & Damoulis, P. D. Postoperative complications following gingival augmentation procedures. *J Periodontol* 2007; 77, 2070–2079.
4. Wessel, J. R. & Tatakis, D. N. Patient outcomes following subepithelial connective tissue of graft and free gingival graft procedures. *J Periodontol* 2008; 79, 425–430.
5. Zucchelli, G., Mounssif, I., Mazzotti, C., Montebugnoli, L., Sangiorgi, M., Mele, M. & Stefanini, M. Does the dimension of the graft influence patient morbidity and root coverage outcomes? A randomized controlled clinical trial. *J Clin Periodontol* 2014; 41, 708–716.
6. Zuhr, O., Baumer, D. & Hurzeler, M. The addition of soft tissue replacement grafts in plastic periodontal and implant surgery: critical elements in design and execution. *J Clin Periodontol* 2014; 41 S123–S142.
7. Zucchelli, G., Mele, M., Stefanini, M., Mazzotti, C., Marzadori, M., Montebugnoli, L. & de Sanctis, M. Patient morbidity and root coverage outcome after subepithelial connective tissue and de-epithelialized grafts: a comparative randomized-controlled clinical trial. *J Clin Periodontol* 2010; 37, 728–738.
8. Ozcelik O, Seydaoglu G, Haytac CM. Diode laser for harvesting de-epithelialized palatal graft in the treatment of gingival recession defects: a randomized clinical trial. *J Clin Periodontol* 2016; 43: 63–71.
9. Yilmaz, E., Ozcelik, O., Comert, M., Ozturan, S., Seydaoglu, G., Teughels, W. & Haytac, M. C. Laser-assisted laterally positioned flap operation: a randomized controlled clinical trial. *Photomed Laser Surg* 2014; 32, 1–8.
10. De Sanctis M, Zucchelli G. Coronally advanced flap: a modified surgical approach for isolated recession-type defects: Three-year results. *J Clin Periodontol*. 2007 Mar; 34(3):262-8.
11. Hurzeler, M. B. & Weng, D. A single-incision technique to harvest subepithelial connective tissue grafts from the palate. *Int J Periodontics Restorative Dent* 1999; 19, 279–287.
12. Lin CY, Nevins M, Kim DM. Laser De-epithelialization of Autogenous Gingival Graft for Root Coverage and Soft Tissue Augmentation Procedures. *Int J Periodontics Restorative Dent* 2018 May 1; 38(3).
13. Wang, C. Y., Tsai, S. C., Yu, M. C., Lin, Y. F., Chen, C. C. & Chang, P. C. 660 nm LED light irradiation promotes the healing of the donor wound of free gingival graft. *J. Periodontol*. 2015; 86, 674–681