



ISSN: 0976-3031

Available Online at <http://www.recentscientific.com>

CODEN: IJRSFP (USA)

International Journal of Recent Scientific Research
Vol.13, Issue, 12 (A), pp.2480-2483, November, 2022

**International Journal of
Recent Scientific
Research**

DOI: 10.24327/IJRSR

Research Article

Surgical management of intestinal obstruction due to black natural pebble stone in a labrador female dog

S.H. Talekar^{1*}, N.R. Padaliya², D.J. Chauhan³, and H.A. Rokad⁴

Dept. of Veterinary Surgery and Radiology, College of Veterinary Science and Animal Husbandry, Kamdhenu University, Junagadh, Gujarat (362 001), India

DOI: <http://dx.doi.org/10.24327/ijrsr.2021.1312.0507>

ARTICLE INFO

Article History:

Received 10th October, 2022

Received in revised form 25th October, 2022

Accepted 10th November, 2022

Published online 28th November, 2022

Keywords:

Foreign body, Gastrointestinal, Labrador retriever, Pebble stone

ABSTRACT

The present study was conducted at the Department of Veterinary Surgery and Radiology, College of Veterinary Science and Animal Husbandry, Kamdhenu University, Junagadh, Gujarat, India during the February 2022. A 4.5 year old Labrador retriever female dog with history of constant vomiting, complete anorexia, abdominal pain, absence of defecation and partially responding to medical treatment since a last three months was presented to **Department of Veterinary Surgery & Radiology, COVSAH & AH, KU, Junagadh**. Radiological examination revealed single stone like slightly uniform radiopaque structure seen in intestinal area. Haematological examination reveals polycythemia, neutrophilia and increased levels of, WBC, RBC indices, MCV and MCH, Urea, Total protein, and ALP. Other haematological and blood serum values were within the normal limit. Surgical removal of black natural pebble stone under general anaesthesia with Atropine @ 0.04 mg kg⁻¹ as pre-anaesthetic, Ketamine @ 10mg kg⁻¹ and Diazepam @ 0.05 mg kg⁻¹ mixture anaesthesia as induction and Isoflurane for maintenance with vapour setting 3–4% at induction with oxygen flow at 60 L kg⁻¹ and is reduced between 1–3% during the maintenance with oxygen flow at 20 L kg⁻¹ was found suitable anaesthetic protocol. Post operatively intravenous fluid was given for five days as ringers lactate, dextrose normal saline, dextrose 25% and Metrogl. Melonex was given @ 0.5 mg kg⁻¹ as a pain killer for three days subcutaneously. Ceftriaxone was given @ 25 mg kg⁻¹ as antibiotics along with antiseptic surgical wound dressing with liquid betadine and stitches was removed on 12th post operative day. Animal showed uneventful recovery after surgery with diminishing the symptoms. History was taken up to 6 month but no incidence of intestinal obstruction was noted.

Copyright © S.H. Talekar, 2022, this is an open-access article distributed under the terms of the Creative Commons Attribution License, which permits unrestricted use, distribution and reproduction in any medium, provided the original work is properly cited.

INTRODUCTION

Intestinal obstruction in dogs is an emergency condition and has a different number of causes. Intestinal obstruction is commonly due to indiscriminate habits in dogs they can ingest foreign bodies or objects such as toys, thread, and bones etc. which enable to pass through the intestine and becomes lodged. May perforate stomach or intestines. Intestinal obstruction may be partial or complete especially in small or large intestines (Hobday *et al.*, 2014). Blood supply to the GI tract becomes comprised which leads to necrosis/ death of intestinal tissues and possible perforation or infection. Bacteria can spill into abdominal cavity causes septic peritonitis. Intestinal obstruction is an emergency or deadly if not catch or treated early (Boothe *et al.*, 1992).

In emergency practice, gastrointestinal foreign body (FB) ingestion is very common in dogs. Foreign bodies can pass

through the gastrointestinal tract without showing clinical signs, or they can cause damage and have a clinical impact (Palma *et al.*, 2022). Symptoms of intestinal obstruction may be projectile vomiting, loss of appetite, straining during bowel movements, diarrhea, tarry stools, inability to defecate, lethargy, burping, excessive drooling, abdominal bloating, abdominal pain, remaining still and refusing to lie down (Poggiani *et al.*, 2020). Ingestion of objects that cannot be broken down through digestion. Rawhides, bones, toys, clothes, towels, stuffed animals, rocks, sticks, tennis balls, shoelaces, hair ties/bands and ribbon etc. Intestinal parasites, intestinal stricture (narrowing of the intestine), gastroenteritis, abdominal tumor, hernia and Intussusception (folding of the intestine) can be life-threatening and include possible aspiration, electrolyte and acid-base disturbances, and dehydration. Depending on the underlying cause of the obstruction, the site can undergo tissue damage resulting in perforation, endotoxemia, and

*Corresponding author: S.H. Talekar

Dept. of Veterinary Surgery and Radiology, College of Veterinary Science and Animal Husbandry, Kamdhenu University, Junagadh, Gujarat (362 001), India

hypovolemic shock (Eastwood *et al.*, 2005). Diagnosis is based on history pet swallow something large, sharp or indigestible the best action is to induce vomiting. A physical examination will allow the veterinarian to feel the abdomen to reveal masses, intussusception, pain or foreign objects. Hematology identifies anemia or infection. Abdominal radiographs can aid in visualizing foreign bodies, tumors, and abnormal bowels. Ultrasound is another good tool to identify presence of an obstruction and its location. Barium sulfate is a metallic compound that shows up on x-ray. If the barium is blocked from flowing or is delayed in movement, this can indicate an obstruction and help to pinpoint its location (Hoffman *et al.*, 2009). If diagnostics indicate an intestinal obstruction, exploratory surgery (Laparotomy) can be performed (often the same day) to locate and remove the obstruction. This case reports described the clinical findings and successful surgical treatment for retrieval of black natural pebble stone as an intestinal obstruction in dog (Singh *et al.*, 2013)

A physical examination and blood tests are often performed to rule out other causes for the observed clinical signs. Abdominal palpation is important in the diagnosis of an obstruction, but advanced diagnostics are often required for confirmation. Abdominal radiographs (X-rays) are the most common diagnostic test performed to help visualize evidence of a FB/obstruction (Gibson, 2020).

Gastrointestinal (GI) foreign bodies are common in dogs and cats and the need for surgical removal of foreign bodies is frequent in veterinary practice (Poggiani *et al.*, 2020, Lopez *et al.*, 2020, Wells *et al.*, 1995, Westgarth *et al.*, 2013). GI foreign bodies are classified by clinical impact, for example, partial or complete obstruction, or by the nature of the foreign body, such as a discrete or linear foreign body (LFB). The underlying pathophysiology of GI foreign body obstruction is the result of failure of forward flow of GI contents secondary to the physical presence of the foreign material. Imaging is a critical component of the diagnostic workup in patients with suspected foreign body ingestion (Cornell and Koenig, 2015).

MATERIAL AND METHODS

The present case was operated at the Department of Veterinary Surgery and Radiology, College of Veterinary Science and Animal Husbandry, Kamdhenu University, Junagadh, Gujarat, India during the February 2022. Pre-anaesthetic evaluation was performed by observing the general health status and physical examination. The clinical status of the dogs was assessed by recording Heart Rate, (HR) Respiratory Rate (RR), Rectal Temperature (RT), Mucous Membrane (MM) colour, Capillary Refill Time (CRT). A case was pre-medicated with Atropine sulphate @ 0.04 mg kg⁻¹, Ketamine and Diazepam was used for induction @ 10mg kg⁻¹ and 0.5mg kg⁻¹ respectively. Anaesthesia was maintained with Isoflurane alone with oxygen flow.

1.

RESULTS AND DISCUSSION

A 4 year and 6 months year old Labrador retriever bitch with history of constant vomiting, complete anorexia, abdominal pain, and absence of defecation was operated at Department of Veterinary Surgery & Radiology, COVS & AH, KU, Junagadh during 2nd February, 2022 Clinical study reveals with decreased heart rate, respiration rate and increased body temperature. Haematological examination reveals Haematological

examination reveals polycythemia (HB 21.3 gdl⁻¹) and increased levels of WBC (18,400cumm⁻¹), RBC indices (HCT 63.1%, MCV 75.8 fL, and MCH 25.5 pg), Urea (34.96), Total protein (9.09mgdl⁻¹), and ALP (393.61 IUL⁻¹). Other haematological values, DLC, LFT & KFT are as follows R.B.C.: 8.33millions, Neutrophils: 84%, Lymphocytes: 24%, Monocytes: 05%, Platelets: 1,91,000cumm⁻¹, Creatinine: 1.19 mgdl⁻¹, BUN: 16.43 mgdl⁻¹, Total Bilirubin:0.32 mgdl⁻¹, Direct Bilirubin:0.10, S.G.P.T.: 37.12 IuL⁻¹. Radiological examination revealed single stone like slightly uniform radiopaque structure seen in intestinal area. The case was very chronic and suffering since three months, initially dog was taking liquid diet may be due to partially obstruction. After series of x-ray was taken during medical management but there was no further movement of foreign body and symptoms become very prominent and condition of dog deteriorates day by day then with owner consent successful surgical retrieval of foreign body was done. Similar findings were reported by Poggiani *et al.*(2020).Pre-operative adequate quantity of intravenous fluid RL 350 ml, DNS 250 ml, Metrogyl @44 mgkg⁻¹, Dextrose 25% 100 ml, Dexamethasone 2 ml), PAN 40 mg IV⁻¹, Botropase 1 ml IV⁻¹, antibiotics Ceftriaxone @ 25 mg kg⁻¹ and analgesic (Meloxicalm 0.5 mgkg⁻¹) was administered for stabilization of the patient.

The ventral midline area from xiphoid region to pubis was prepared aseptically for the surgery. The bitch was pre-medicated with Atropine sulphate @ 0.04 mgkg⁻¹ body weight SC⁻¹ and mixture of Ketamine HCL @10mgkg⁻¹ and Diazepam @ 0.5 mgkg⁻¹ IV⁻¹ as an induction and maintained general anaesthesia with 2–3% Isoflurane. Removed black natural pebble stone with enterotomy incision on dilated bowel on proximal side. Closure of incision with routine manner. Post operatively intravenous fluids DNS, RL and Metrogyl for rehydration, Ceftriaxone antibiotic for five days and Melonex as a pain killer for three days. Withheld water intake for two days and food for 5 days. The bitch showed progressive signs of improvement in the post-operative period. The skin sutures were removed 12th day post-operatively and the animal made an uneventful recovery while similar findings observed in dogs and cat (Poggiani *et al.*, 2020, Lopez *et al.*, 2020, Wells *et al.*, 1995, Westgarth *et al.*, 2013).



Figure 1 Two year old female Beagle dog.

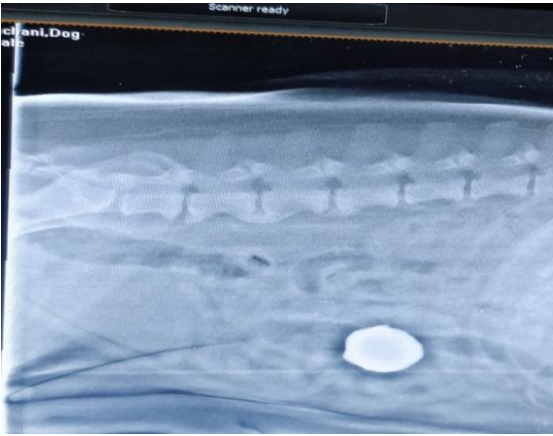

Figure 2 Radiograph revealed radiopaque foreign body.

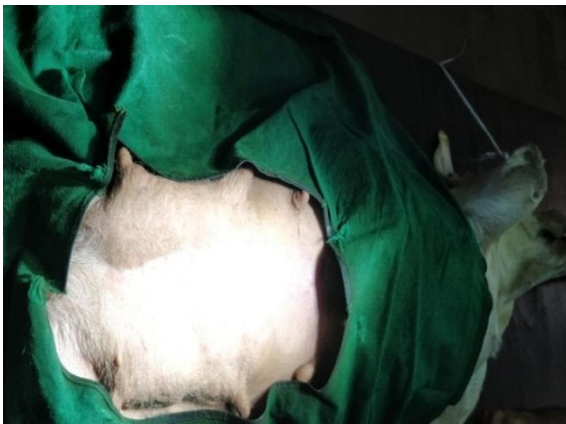

Figure 3 Preparation of surgical site.

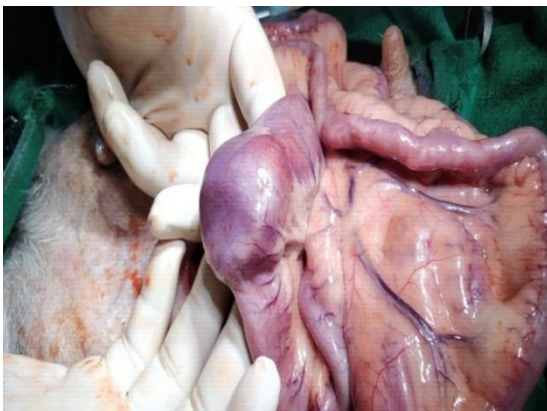

Figure 4 Distended bowel due to Foreign body.

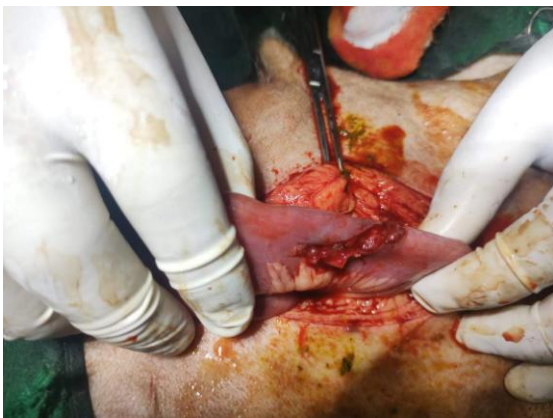


Figure 5 Enterotomy incision

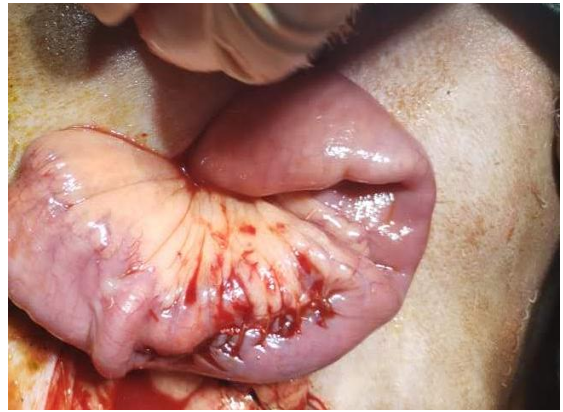


Figure 6 Closure of enterotomy incision

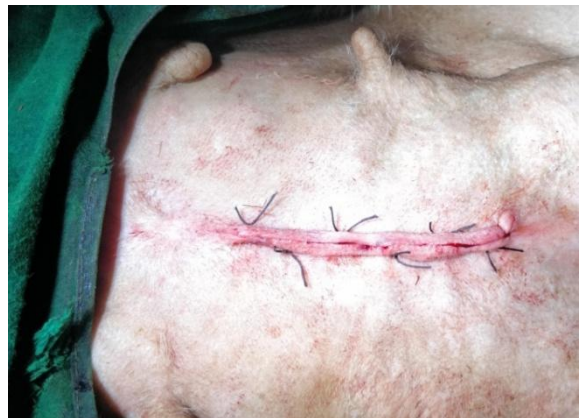

Figure 7 Skin sutures.

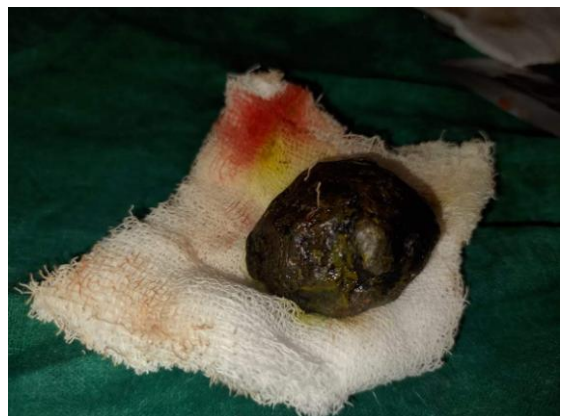

Figure 8 Retrieved of black natural pebble stone

CONCLUSION

The case report Enterotomy with full thickness incision dilated bowel on proximal side is found suitable for removal black natural pebble stone. In dog GI tract obstruction immediate decision of exploratory laparotomy followed by Enterotomy with proper asepsis and post operative care by withholding water for 2 days and food at least 5 days gives uneventful recovery. Post operative care with proper rehydration, PAIN management and suitable antibiotic therapy helps fast recovery of patients.

References

1. Boothe, H., Slater, M., Hobson, H., Fossum, T., 1992. Exploratory celiotomy in 200 non-traumatized dogs and cats. *Veterinary Surgery* 21(6), 452–457.
2. Eastwood, J., McInnes, E., White, R., Elwood, C., Stock,

- G., 2005. Caecal impaction and chronic intestinal pseudo-obstruction in a dog- A case report. *Journal of Veterinary Medicine. A Physiology, Pathology, Clinical Medicine* 52(1), 43–44.
3. Hoffman, C., Mastrocco, A., Hughes, D., 2005. Acid-base and electrolyte abnormalities in dogs with gastrointestinal foreign bodies. *Journal of Veterinary Internal Medicine* 19, 816–821.
4. Hobday, M., Pachtinger, G., Drobatz, K., Syring, R., 2014. Linear versus non-linear gastrointestinal foreign bodies in 499 dogs: Clinical presentation, management and short-term outcome. *Journal of Small Animal Practice* 55, 560–565.
5. Lopez, D., Hayes, G., Fefer, G., McCalla, S.A., La-Londe Paul, D.F., Flanders, J.A., Summer, J.P., 2020. Effect of subcutaneous closure technique on incisional complications and postoperative pain in cats undergoing midline celiotomy: a randomized, blinded, controlled trial. *Veterinary Surgery* 49(2), 321–328.
6. Poggiani, F., da Costa Duarte, R., Santana, M., Galera, P., 2020. Endoscopic removal of foreign body in upper gastrointestinal tract in dogs: Success rate and complications. *Acta Science Veterinaria* 48, 1735.
7. Wells, K., Bright, R., Wright, K., 1995. Caecal impaction in a dog- A case report. *Journal of Small Animal Practice* 36(10), 455–457.
8. Singh, J., Monsang, S.W., Madhu, D.N., Sarode, I.P., Kinjavdekar, P., Pawde, A.M., Amarpal, Aithal, H.P., Zama, M.M.S., 2011. Surgical management of Caecal faecolithiasis in a non-descript dog. *Indian Journal of Canine Practice* 3(2), 134–137.
9. Talekar SH, Joice P Joseph, Manish Soni, Katara KP, Harshith BH and Kamaliya RU Surgical management of intestinal obstruction due to bristles of sweep broom in a queen cat: *International Journal of Science, Environment and Technology*, 2018; Vol. 7, No 3, 2018, 872 – 876.
10. Talekar SH, Padaliya NR and Dodia VD Successful surgical management of intestinal faecoliths in a queen cat: *International Journal of Science, Environment and Technology*, 2022; Vol. 11, No 4, 2022, 229 – 233.
11. Talekar SH, Padaliya NR, Dodia VD and Manish Soni Successful surgical management of intestinal faecoliths in a Beagle bitch: *International Journal of Science, Environment and Technology*, 2022; Vol. 11, No 4, 2022, 216 – 219.
12. Westgarth, S., Singh, A., Vince, A.R., 2013. Subclinical cecal impaction in a dog- A case report. *Canine Veterinary Journal* 54(2), 171–173.
