

ISSN: 0976-3031

Available Online at <http://www.recentscientific.com>

CODEN: IJRSFP (USA)

*International Journal of Recent Scientific Research*  
Vol. 13, Issue, 12 (A), pp. 2693-2698, December, 2022

**International Journal of  
Recent Scientific  
Research**

DOI: 10.24327/IJRSR

## Research Article

# GENDER AND AGE DETERMINATION OF DENTULOUS PATIENTS - A RADIOGRAPHIC STUDY

Abhishek Banerjee\*<sup>1</sup>, ShivaKumar G.C.<sup>2</sup>, Neeta Misra<sup>1</sup>, Deepak U.<sup>1</sup>, Puja Rai<sup>1</sup>, Shweta Singh<sup>1</sup>

<sup>1</sup>Department of Oral Medicine and Radiology, Babu Banarasi Das College of Dental Sciences, Lucknow, India

<sup>2</sup>Department of Oral Medicine and Radiology, People's College of Dental Sciences and Research Centre, Bhopal, India

DOI: <http://dx.doi.org/10.24327/ijrsr.2021.1312.0553>

### ARTICLE INFO

#### Article History:

Received 28<sup>th</sup> October, 2022

Received in revised form 25<sup>th</sup> November, 2022

Accepted 14<sup>th</sup> December, 2022

Published online 28<sup>th</sup> December, 2022

#### Keywords:

Forensic, mental foramen, gender determination, age estimation, digital, panoramic radiography.

### ABSTRACT

**Objectives:** Remains of human skeleton identification are an important part in forensic science. This study has been conducted for determination of gender and age estimation using digital panoramic radiographs in dentulous patients. **Material and Methods:** Study sample consisted of 200 patients referred for digital panoramic radiographs. For gender and age determination, measurements were made using the reference lines drawn from anatomical landmarks. **Results:** Present study showed that there was a statistically significant difference in the measurements between males and females on the right side. There was no statistically significant difference between the two age groups for different variables except for distance between the superior margins of the Mental Foramen(MF) to the inferior border of the mandible which showed significant difference. Most common appearance of MF was found to be "Separated" type. Test results however showed a statistically non significant association with gender. Most common horizontal location of MF was found to be in line with second premolar in both gender. The position of MF relative to the apex of second premolar was found to be 78 on the mesial side. **Conclusions:** It is possible to conclude that the measurements can be used to determine the gender. Appearance of MF was found to be "Separated" type which cannot be used for gender determination. Most common horizontal location of MF was found to in line with second premolar. Most common position of MF relative to the apex of second premolar was found to be intersecting in males and mesial in females with no statistical significant association.

Copyright © Abhishek Banerjee 2022, this is an open-access article distributed under the terms of the Creative Commons Attribution License, which permits unrestricted use, distribution and reproduction in any medium, provided the original work is properly cited.

### INTRODUCTION

Gender determination using the remains of human skeleton is the first step which is followed by estimation of age and stature which is dependent on gender<sup>[1]</sup>.

The reliability of gender determination depends on the completeness of the remains and the degree of sexual dimorphism inherent in the population. When the entire adult skeleton is available for analysis, gender can be determined up to 100% accuracy. Skull is the most dimorphic and easily sexed portion of skeleton after pelvis, providing accuracy up to 92%. But in cases where intact skull is not found, mandible may play a vital role in sex determination. Presence of a dense layer of compact bone makes it very durable. Dimorphism in mandible is reflected in its shape and size. Male bones are generally bigger and more robust than female bones<sup>[2]</sup>.

Distinguishing males from females and the differences in ethnic groups by analyzing the morphological characteristics of bone is important in the field of physical and forensic

anthropology<sup>[3]</sup>. Determining the identity of a person is of considerable significance from the ethical, legal, and criminal perspectives; not only is it the prerequisite for officially declaring an individual dead but it is also the basis for dealing with mass disasters, crimes, and war crimes<sup>[4]</sup>. Morphological changes of the mandible are thought to be influenced by the occlusal status and age of the subject. Longitudinal studies have shown that remodeling of the mandibular bone occurs with age<sup>[5]</sup>.

The Mental Foramen (MF) is an important anatomical structure located in the body of mandible. It represents the termination of mental canal which opens onto the surface in oblique direction. Radiographic evaluation of the position of MF becomes an obligation for accurate diagnosis<sup>[6]</sup>. Mental foramen is one such landmark on the mandible which is stable. The mental foramen morphology, in terms of position, varies not only according to age, gender and ethnicity but even within the same race, in different geographic regions and within the inhabitants of the same geographic area<sup>[7]</sup>. The radiographic method is simplest

\*Corresponding author: **Abhishek Banerjee**

Department of Oral Medicine and Radiology, Babu Banarasi Das College of Dental Sciences, Lucknow, India.

and cheapest method for age estimation and gender determination when compared to the histological and biochemical methods. Among radiographic methods Panoramic radiography is the most preferred diagnostic modality as it allows a more accurate localization of mental foramen[8]. Panoramic radiography is a widely used technique with the advantage of providing a satisfactory coverage of both jaws, with a relatively low-radiation dose, in a short-period of time, and at lower cost if compared to more sophisticated techniques[9]. The image quality of the panoramic radiography is increased by the digitization<sup>[10]</sup>.

Hence this study aimed at documenting anatomical information on appearance, size, horizontal and vertical locations of Mental Foramen in Panoramic Radiograph. We also determined the relationship of age and gender with its radiographic appearance and location.

## MATERIAL AND METHODS

The study population was drawn from the patients attending the outpatient Department of Oral Medicine and Radiology. The study sample consisted of 200 patients from both genders. Panoramic radiographs of the patients were studied and sent for statistical analysis.

### *Materials and Equipments used in the study with specifications and company*

1. Digital panoramic radiograph [Planmeca Proline XC, SN: XC430638, 180-240V, 50 Hz]
2. Installed in AERB (Atomic Energy Radiation Board) certified quality assurance facility.
3. AutoCAD software 2009.

### *Inclusion criteria*

- Age groups from 20 years to 60 years.
- All teeth in the region of measurement have to be present.
- Evidence of alveolar crest resorption in premolar and first molar regions should be absent.
- Radiographic images of the mental foramen and the borders of the mandible should be distinct, free of artifacts in the site of measurement.
- First and second premolars should be in reasonably normal position and alignment.

### *Exclusion Criteria*

- Patients should not have history of any systemic disease that might affect bone metabolism.
- Any pathology or congenital anomaly in the mandible that could affect the interpretation of the radiographic image.
- Presence of severe crowding and spacing in lower arch.

## SAMPLING METHOD

The study group consists of randomly selected samples of 200 patients consisting of 2 age groups: Group I (20-39 years) and Group II (40-60 years). Case history was recorded. The subjects were selected according to the inclusion and exclusion criteria.

### *For gender determination*

Radiographs were viewed digitally. Measurements were made using the reference lines drawn from anatomical landmarks. A line joining the most prominent point on the chin the 'menton' and the most prominent point of the angle of the mandible

'joining' will be marked using AutoCAD software. The mental foramen will be identified and marked on the right side. A line perpendicular to this tangent is marked from the inferior mandibular border to the alveolar crest such that it intersected the inferior edge of the mental foramen on the right side.

### *Four measurements were made and analyzed on every radiograph on the right side digitally*

1. Distance from the inferior surface of the mandibular body to the height of the alveolar crest on the right side (height).
2. Distance between the superior margins of the mental foramen to the inferior border of the mandible on the right side (SM to IB).
3. Distance between the inferior margins of the mental foramen to the inferior border of the mandible on the right side (IM to IB).
4. Distance between the superior margin of the mental foramen to the alveolar crest on the right side (SM to AC) – were measured.

### *For age estimation*

### *The appearance of mental foramina are of four different types*

1. Continuous type: foramen which showed continuity with the mandibular canal.
2. Separated type: foramen which was distinctly separated from mandibular canal.
3. Diffuse type: foramen which had an indistinct border.
4. Unidentified type: the foramen which could not be identified on the panoramic radiographic under given exposure and viewing conditions.

- If there appeared to be multiple foramina, then the uppermost and the nearest landmark to the mandibular canal was considered as true radiographic mental foramen.
- The horizontal location in relation to the apices of the teeth will be determined and categorized as follows

1. Anterior to first premolar (Location 1)
2. In line with first premolar (Location 2)
3. Between first and second premolar (Location 3)
4. In line with second premolar (Location 4)
5. Between second premolar and first molar (Location 5)
6. In line with first molar (Location 6)

- The long axis of the premolars and 1st molar will be considered as vertical references to determine the horizontal location.
- The average position was determined. A horizontal line XY will be drawn at the occlusal level. Another line EF will be drawn parallel to the line XY at the apex of second premolar. Perpendicular line AB will be drawn passing through the apex of the mandibular second premolar through the long axis of the clinical crown (perpendicular to lines XY and EF) to the inferior border of the mandible. The average position of the mental foramen (in relation to the line AB) relative to the apex of 2nd premolar will be recorded as mesial, distal or intersecting this line.

The vertical location was estimated by determining the shortest perpendicular line joining the alveolar ridge and the lower border of mandible, passing through the center of mental foramen. Measurements will be made (in mm) from the

alveolar ridge to the upper border of mental foramen (a), from the lower border of foramen to the lower border of mandible (b), the diameter of mental foramen itself.

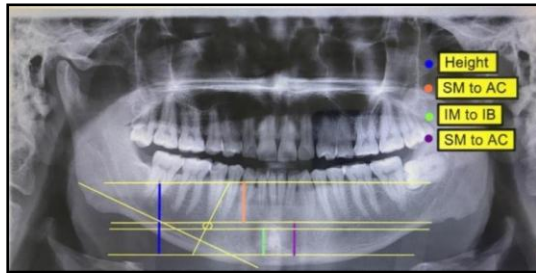


Figure 1 Measurements in orthopantomogram radiograph for gender determination.

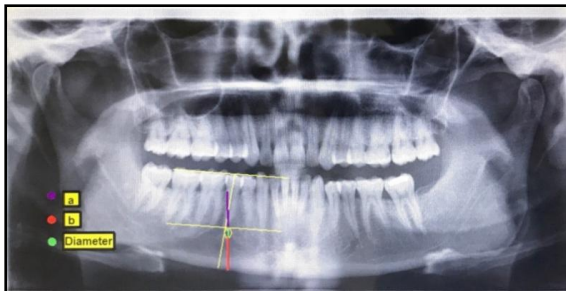


Figure 2 Measurements in orthopantomogram radiograph for age estimation

## RESULTS

### For gender determination

In the present study, on comparison of males and females, the mean value for the height of the mandible was recorded at  $24.14 \pm 2.04$  mm for males and  $21.93 \pm 1.96$  mm for females which was statistically highly significant at p-value 0.0001 (t value = -7.616). The mean value for the SM to IB was recorded at  $11.29 \pm 1.42$  mm for males and  $10.12 \pm 1.17$  mm for females which was statistically highly significant at p-value 0.0001 (t value = -6.359). The mean value for the IM to IB was recorded at  $8.98 \pm 1.39$  mm for males and  $7.84 \pm 1.21$  mm for females which was statistically highly significant at p-value 0.0001 (t value = -6.186). The mean value for the SM to AC was recorded at  $12.83 \pm 1.72$  mm for males and  $11.84 \pm 1.62$  mm for females which was statistically highly significant at p-value 0.0001 (t value = -4.19) (Table 1)

significant difference. The mean value for the SM to IB was recorded at  $10.95 \pm 1.50$  mm for age group between 20-39 years and  $10.46 \pm 1.31$  mm for age group between 40-60 years which was statistically significant at p-value 0.0147 (t value = -2.46).

In the present study, statistically highly significant difference was observed when comparison of males and females in different variables of age group between 20-39 years. The mean value for the height of the mandible was recorded at  $24.02 \pm 2.19$  mm for males and  $22.13 \pm 1.68$  mm for females which was statistically highly significant at p-value <0.0001 (t value = -4.842). The mean value for the SM to IB was recorded at  $11.58 \pm 0.22$  mm for males and  $10.33 \pm 1.13$  mm for females which was statistically highly significant at p-value <0.0001 (t value = -4.569). The mean value for the IM to IB was recorded at  $9.06 \pm 1.54$  mm for males and  $7.78 \pm 1.34$  mm for females which was statistically highly significant at p-value <0.0001 (t value = -4.434).

Present study also observed statistically highly significant difference on comparison of males and females in different variables of age group between 40-60 years. The mean value for the height of the mandible was recorded at  $24.27 \pm 1.89$  mm for males and  $21.74 \pm 2.21$  mm for females which was statistically highly significant at p-value <0.0001 (t value = -6.152). The mean value for the SM to IB was recorded at  $11.01 \pm 1.20$  mm for males and  $9.92 \pm 1.18$  mm for females which was statistically highly significant at p-value <0.0001 (t value = -4.58). The mean value for the IM to IB was recorded at  $8.89 \pm 1.23$  mm for males and  $7.90 \pm 1.08$  mm for females which was statistically highly significant at p-value <0.0001 (t value = -4.277). The mean value for the SM to AC was recorded at  $13.20 \pm 1.56$  mm for males and  $11.83 \pm 1.73$  mm for females which was statistically highly significant at p-value <0.0001 (t value = -4.159).

Females and males both showed statistically no significant difference in the measurements of height of the mandible and SM to AC, SM to IB, and IM to IB on comparison of age groups between 20-39 years and 40-60 years.

### For age estimation

Each radiograph was analyzed to record the horizontal and vertical locations. Chi-square and t-test were employed.

The most common appearance of MF was found to be

Table 1 Comparison of Males and Females in Different Variables on Right Side

Summary	Height			SM to IB			IM to IB			SM to AC		
	Male	Female	Combined	Male	Female	Combined	Male	Female	Combined	Male	Female	Combined
N	100	100	200	100	100	200	100	100	200	100	100	200
Minimum	16.49	17.61	16.49	7.98	7.62	7.62	5.88	4.87	4.87	8.02	8.7	8.02
Maximum	29.19	28.81	29.19	15.25	12.61	15.25	13.16	10.61	13.16	18.17	17.49	18.17
Mean (mm)	24.14	21.93	23.04	11.29	10.12	10.71	8.98	7.84	8.41	12.83	11.84	12.34
SD	2.04	1.96	2.28	1.42	1.17	1.42	1.39	1.21	1.42	1.72	1.62	1.74
SE	0.20	0.20	0.16	0.14	0.12	0.10	0.14	0.12	0.10	0.17	0.16	0.12
95% CI-Upper Bound	24.35	22.13	23.20	11.43	10.24	10.81	9.12	7.96	8.51	13.01	12.00	12.46
95% CI-Lower Bound	23.94	21.74	22.88	11.15	10.01	10.61	8.84	7.72	8.31	12.66	11.68	12.22
t-value		-7.616			-6.359			-6.186			-4.19	
p-value		0.0001			0.0001			0.0001			0.0001	

There was no statistically significant difference between the two age groups (20-39 years and 40-60 years) different variables on the right side except for SB to IB which showed

“Separated” type in 50% males and in 52% females and the least common appearance was found to be “Diffused” type in 10% males and 12% females. However in both age groups

(Group I and Group II) majority of MF appeared to be “Separated” type in 52% cases in Group I (20-39 years) and 48% cases in Group II (40-60 years) respectively and the least common appearance appeared to be “Diffused” type in 11% cases in Group I (20-39 years) and 11% cases in Group II (40-60 years) respectively. The test results however showed a statistically non significant association of gender ( $p = 0.8059$ ) and age ( $p = 0.6614$ )(Table 2)

- Diameter - Diameter of mental foramen itself
  - b. Distance from the lower border of foramen to the lower border of mandible.
- a/b – Vertical position of the mental foramen

Emphasize the new and important aspects of the study and the conclusions that follow from them. Do not repeat in detail data or other material given in the Introduction or Results section. Relate observations to other relevant studies and point out the

**Table 2** The appearance of mental foramina on panoramic radiograph

Appearance	GENDER				AGE					
	Males	%	Females	%	Grand Total	20-39 years	%	40-60 years	%	Grand Total
Continuous	40	40	36	36	76	35	35	41	41	76
Diffuse	10	10	12	12	22	11	11	11	11	22
Separated	50	50	52	52	102	54	54	48	48	102
Grand Total	100	100	100	100	200	100	100	100	100	200

\*  $X^2 = 0.431560183882$ ,  $df = 2$ ,  $p = 0.805912509044$

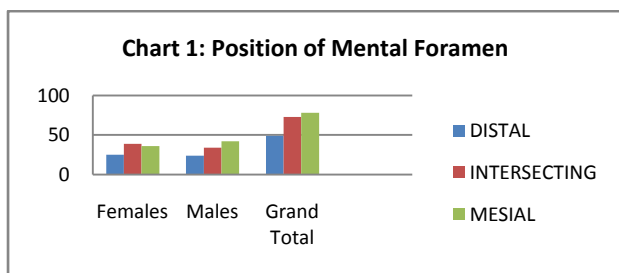
#  $X^2 = 0.826625386997$ ,  $df = 2$ ,  $p = 0.661455417678$

X2 is chi square and df is degree of freedom

The most common horizontal location of MF was found to be Location “4” accounting to be 56% and 58% in males and females respectively. The least common horizontal location of MF was found to be Location “2” accounting to be 1% and 1% in males and females respectively.

No cases were recorded with horizontal location 1. Location “4” was again commonest among both the age groups with 53% cases in Group I and 61% cases in Group II. However there was no significant association of gender ( $p = 0.9415$ ) and age ( $p = 0.1898$ ) with the horizontal location of MF.(Table 3)

The position of MF relative to the apex of second premolar was found to be 78 on the mesial side, 49 on the distal side and 73 intersecting with the apex of respective second premolar. However there was no statistical significant association with gender ( $p = 0.6621$ ). The commonest position of MF relative to the apex of second premolar was found to be intersecting (39 cases) in females and mesial (42 cases) in males.(Chart 1)



The vertical location of MF (a/b) was found to be  $1.419 \pm 0.2878$  mm on the right side. The mean value for the distance from alveolar ridge to the upper border of mental foramen (A) was recorded as  $12.8194 \pm 1.8073$ . The mean value for the distance from the lower border of foramen to the lower border of mandible (B) was recorded as  $9.2425 \pm 1.4799$ . The mean value for the diameter was recorded as  $2.3225 \pm 0.6674$ . (Table 4)

**Table 4** Vertical Location of mental foramen (mm)

	MEAN	SD
A	12.8194	1.807303
Diameter	2.32255	0.667467
B	9.2425	1.479918
a/b	1.41934	0.287825

a. Distance from the alveolar ridge to the upper border of mental foramen

implications of the findings and their limitations.

## DISCUSSION

### Gender Determination

Present study showed that there was a statistically significant difference in the measurements between males and females on the right side in relation to the height of the mandible, SM to IB, IM to IB and SM to AC. There was no statistically significant difference between the two age groups for different variables on the right side.

Similar result was observed by Aspalilah Alias *et al.* (2017) that height of mandible was significantly greater in males than in females ( $p < 0.05$ ). It was found to be  $24.6 \pm 0.04$ mm in males and  $24.3 \pm 0.03$ mm in females<sup>[11]</sup>. Similarly Girish Suragimath *et al.* (2016) assessed that the height of the mandible (AC to LBM) was 29.2mm in males and 21.1mm in females on the right side and comparison showed statistically extremely significant differences as the value was more in males<sup>[12]</sup>. Similar result was concluded by Moni Thakur *et al.* (2014) that the height of the mandible was  $34.54 \pm 2.40$ mm in males and  $33.08 \pm 2.47$ mm in females which showed statistically significant difference ( $p = 0.0031$ )<sup>[3]</sup>. In this study the mean value for the IM to IB was recorded at (Table 3)  $8.98 \pm 1.39$  mm for males and  $7.84 \pm 1.21$  mm for females which was statistically highly significant at p-value 0.0001 (t value = -6.186). Similar results was observed by Akhilesh Chandra *et al.* (2013) that the mean distance from the lower border of the mental foramen to the lower border of the mandible (I-L) on the right side in males was 12.670 mm, whereas it was 11.462 mm in females which was significantly higher in males.<sup>13</sup> Similar result was concluded by Moni Thakur *et al.* (2014) that the mean value for IM to IB was 13.88mm in males and 13.08mm in females which was significantly higher in males<sup>[3]</sup>.

On the contrary, Girish Suragimath *et al.* (2016) observed that the distance from IMF to LBM on the right side in females was more than the left side, with no significant differences. The average distance from IMF to LBM in males was 11.8 mm and in females 11.4 mm<sup>[12]</sup>. On the contrary, Vodanovic *et al.* (2006) found that the mean value of IM-IB does not exhibit sexual dimorphism<sup>[14]</sup>.

Similar result was assessed by Marin Vodanovic *et al.* (2006) that the mean value for distance between mental foramen and alveolar border of the mandible (MF-AIB) was 15.21 in males and 13.63 in females which was significantly higher in males [14]. Similar result was observed by Juan Muinelo-Lorenzo *et al.* (2016) that the mean value of MF-MIB (distances from the

foramen to the lower border of mandible was recorded as  $8.55 \pm 4.84$  [6]. Similar result was assessed by Gershenson A *et al.* (1986) that shape of MF was round in 34.48% with an average diameter of 1.68 mm and oval in 65.52% with an average long diameter of 2.37 mm<sup>[18]</sup>.

**Table 3** Frequency of horizontal location of mental foramen (in relation to the apices of the teeth on the panoramic radiograph)

Location of Mental Foramen	GENDER				AGE						
	Males	%	Females	%	Grand Total	20-39 years	%	40-60 years	%	Grand Total	%
Location 1	0		0			0		0		0	
Location 2	1	1	1	1	2	2	2	0	0	2	1
Location 3	9	9	8	8	17	12	12	5	5	17	8.5
Location 4	56	56	58	58	114	53	53	61	61	114	57
Location 5	30	30	31	31	61	31	31	30	30	61	30.5
Location 6	4	4	2	2	6	2	2	4	4	6	3
Grand Total	100	100	100	100	200	100	100	100	100	200	100

X<sup>2</sup> = 0.776971358, df = 4, p = 0.941508441139  
 # X<sup>2</sup> = 6.126816559238, df = 4, p = 0.189875595759  
 X<sup>2</sup> is chi square and df is degree of freedom

Location 1: Anterior to first premolar, Location 2: In line with first premolar, Location 3: Between first and second premolar, Location 4: In line with second premolar, Location 5: Between second premolar and first molar, Location: In line with first molar

alveolar bone crest to the MF) was  $13.55 \pm 1.06$  mm in males and  $11.42 \pm 3.34$  mm in females. The result showed statistically significant difference which was higher in males<sup>[15]</sup>.

**Age Estimation**

Vaibhav Gupta *et al.* (2015) observed that the appearance of MF was found to be “Continuous” type in 34.3% males and “Separated” in 33.1% females. However, in both age groups Group A (19-40 years) and Group B (41-65 years) majority of MF appeared to be continuous type in 28.1% and 37.3% cases respectively. The test results however showed a significant association of age (p = 0.0004) and gender (p = 0.006) [6]. Youse *et al.* (1989) evaluated 297 patients, and reported that the most frequent appearance was separated (43%), followed by diffuse (24%), continuous (21%), and unidentified (12%) whereas in our study most frequent appearance was continuous (30.4%) followed by separated (28.6%), unidentified (22.2%) and the diffuse (18.8%) variant respectively [16]. Navya N. Swamy *et al.* (2015) concluded that the most common Type I is mental canal is continuous with the mandibular canal of mental foramen (53.5%)<sup>[17]</sup>.

Similar result was observed by Gershenson A *et al.* (1986) that the most common location of MF was in front of the apex of the root of the second premolar which was 43.66% [18]. Similar results were assessed by Luay N. Kaka *et al.* (2010) that the most common location of MF was close to the second premolar in all age groups and there are no significant differences between groups<sup>[19]</sup>.

Vaibhav Gupta *et al.* (2015) concluded that the average position of MF relative to the apex of second premolar was found to be 47% on the mesial side, 34.7% on the distal side and 18.3% intersecting with the apex of respective second premolar [6]. Also, that the vertical location of MF was found to vary on left and right sides (X: Z =  $1.34 \pm 0.99$  on left and  $1.48 \pm 1.12$  on the right). The results of t test were not significant. The average horizontal dimension of MF on right side was  $2.61 \pm 1.83$ mm and  $2.81 \pm 1.71$ mm. The average vertical dimension of MF on right side was  $2.24 \pm 1.55$ mm. The mean value for the diameter of MF on the right side was recorded as  $2.24 \pm 1.32$ mm. The mean value for the distance from alveolar ridge to the upper border of mental foramen was recorded as  $14.11 \pm 7.55$ mm. The mean value for the distance from the lower border of

**CONCLUSIONS**

The knowledge on the variations in the position, appearance and size of the mental foramen may be of much use to dental surgeons. Analyzing mental foramen can be considered as an additional radiographic method for gender determination and age estimation. From the present study it is possible to conclude that statistically significant results were observed which was higher in males for the mean value of height of the mandible, SM to IB, IM to IB and SM to AC when compared between males and females. There was no statistically significant difference between the two age groups (20-39 years and 40-60 years) different variables on the right side except for SB to IB which showed significant difference and higher in males. It is possible to conclude that the various measurements in this study can be used to determine the gender. The test results for appearance, horizontal location and position of MF however showed a statistically non-significant association of gender and age.

However, large study groups and comprehensive assessment of various other parameters related to the height of the mandible and mental foramen may be required for more definitive and confirmatory results.

**References**

1. Ghouse, N., Nagaraj, T., James, L., Swamy, N.N., Jagdish, C., & Bhavana, T.V. (2016). Digital analysis of linear measurements related to the mental and mandibular foramina in sex determination. *Journal of Medicine, Radiology, Pathology & Surgery* 2016; 2:5-9.
2. Muskaan A, Sarkar S. Mandible-An Indicator for age and sex determination using digital Orthopantomogram. *Scholars. Journal of Dental Sciences (SJDS)* 2015; 2(1):82-95.
3. Thakur M, K. Vinay Kumar Reddy, Y.Sivaranjani, Khaja S. Gender Determination by Mental Foramen and Height of the Body of the Mandible in Dentulous Patients: A Radiographic Study. *J Indian Acad Forensic Med.*2014; 36:13-18.

4. Karaarslan B, Karaarslan E.S, Ozsevik A.S, Ertas E. Age Estimation for Dental Patients Using Orthopantomographs, *European Journal of Dentistry*. October 2010 - Vol.4; 289-294.
5. Al-Shamout R, Ammouh M, Alrbata R, Al-Hababbah A. Age and gender differences in gonial angle, ramus height and bigonial width, *Pakistan Oral & Dental Journal* Vol 32, No. 1 (April 2012): 81-87.
6. Gupta V, Pitti P, Sholapurkar A. Panoramic radiographic study of mental foramen in selected Dravidians of south Indian population: A hospital-based study. *J Clin Exp Dent*. 2015; 7(4):e451-6.
7. Sahni P, Ronak J. Patel, Shylaja, Jaydeva H. M, Anil Patel. Gender Determination by Pantomographic (OPG) Analysis of Mental Foramen in North Gujarat Population- A Retrospective Study. *Med. Res. Chron* 2015; 2 (5):701-706.
8. Malik M, Laller S, S Saini R, Mishra R.K, Hora I, Dahiya N. Mental foramen: An Indicator for Gender Determination - A Radiographic Study. *Santosh University Journal of Health Sciences* 2016; 2(1):12-14.
9. Haghnegahdar A, Bronoosh P. Accuracy of linear vertical measurements in posterior mandible on panoramic view. *Dent Res J (Isfahan)* 2013; 10(2):220-224.
10. Ural C, Bereket C , Şener I, Aktan A.M , Akpınar Y.A. Bone height measurement of maxillary and mandibular bones in panoramic radiographs of edentulous patients. *J Clin Exp Dent* 2011;3(1):e5-9.
11. Alias A, Ibrahim A.N, Bakar N.A, Shafie M.S, Srijit Das, Nor M.F. Morphometric and Morphological Study of Mental Foramen in the Malaysian Population: Anatomy and Forensic Implications. *International Medical Journal Malaysia*, Volume 16, Issue 2, 2017, pp. 47-53.
12. Suragimath G, S.R.Ashwinirani, Christopher V, Bijjargi S, Pawar R, and Nayak A. Gender determination by radiographic analysis of mental foramen in the Maharashtra population of India. *J Forensic Dent Sci*. 2016 Sep-Dec; 8(3): 176.
13. Chandra A, Singh A, Badni M, Jaiswal R, Agnihotri A. Determination of sex by radiographic analysis of mental foramen in North Indian population. *J Forensic Dent Sci*. 2013 Jan-Jun; 5(1): 52-55.
14. Vodanovic M, Dumancic J, Demo Z, Mihelic D. Determination of sex by discriminant function analysis of mandibles from two Croatian archeological sites. *Acta Stomatol Croat*. 2006; 40(3):263-77.
15. Lorenzo J.M, Suárez-Quintanilla J.A, Alonso A.F, Mallou J.V, Suárez-Cunqueiro M.M. Radiographic study of the mental foramen variations. *Med Oral Patol Oral Cir Bucal*. 2015 Nov 1; 20 (6):e707-14.
16. Youse T, Brooks SL. The appearance of mental foramen on panoramic radiographs. I. Evaluation of patients. *Oral Surg Oral Med Oral Pathol*. 1989; 68:360-4.
17. Navya N. Swamy, Tejavathi Nagaraj, Noori Ghouse, C. D. Jagadish, N. Sreelakshmi, Rahul Dev Goswami. Radiographic study of mental foramen type and position in Bangalore population. *Journal of Medicine, Radiology, Pathology & Surgery* (2015), 1, 5-8.
18. Gershenson A, Nathan H, Luchansky E. Mental foramen and mental nerve: changes with age. *Acta Anat (Basel)*. 1986; 126(1):21-8.
19. Luay N. Kaka, Amal R S. Mohammed, Fatin Kh. Abbas. Estimation of the position of mental foramen and its relation to lower premolars and base border of the mandible during aging. *J Bagh College Dentistry*. 2010 Vol. 22(3).

\*\*\*\*\*