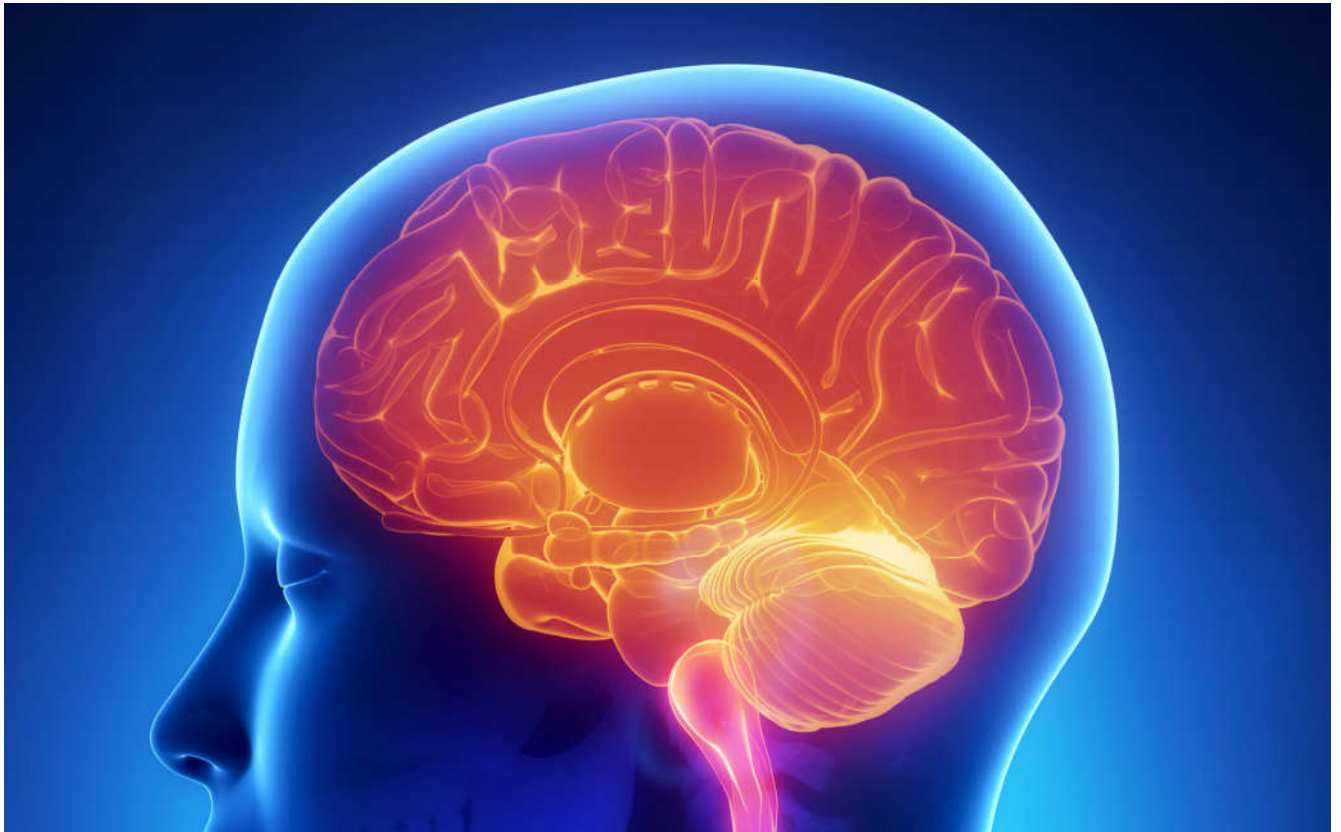



International Journal Of
**Recent Scientific
Research**

ISSN: 0976-3031
Volume: 7(11) November -2015

MANAGEMENT OF SEVERLY RESORBED MANDIBULAR RIDGE USING
NEUTRAL ZONE TECHNIQUE- A CASE REPORT

Savita Dandekeri, Kamalakanth Shenoy,
Rajesh Shetty, Vidya Bhat,
Mallikarjuna Ragher, Reshma Banu



THE OFFICIAL PUBLICATION OF
INTERNATIONAL JOURNAL OF RECENT SCIENTIFIC RESEARCH (IJRSR)
<http://www.recentscientific.com/> recentscientific@gmail.com



ISSN: 0976-3031

Available Online at <http://www.recentscientific.com>

International Journal of Recent Scientific Research
Vol. 6, Issue, 11, pp. 7469-7471, November, 2015

**International Journal
of Recent Scientific
Research**

CASE REPORT

MANAGEMENT OF SEVERLY RESORBED MANDIBULAR RIDGE USING NEUTRAL ZONE TECHNIQUE- A CASE REPORT

**Savita Dandekeri, Kamalakanth Shenoy, Rajesh Shetty, Vidya Bhat,
Mallikarjuna Ragher, Reshma Banu***

Department of prosthodontics, Yenepoya Dental College, Yenepoya University,
Mangalore, Karnataka – India

ARTICLE INFO

Article History:

Received 05th August, 2015
Received in revised form
08th September, 2015
Accepted 10th October, 2015
Published online 28st November,
2015

Key words

Neutral zone, Denture stability,
Resorbed mandibular ridge

ABSTRACT

Neutral zone is defined as the potential space between the lips and cheeks on one side and the tongue on the other, that area or position where the forces between the tongue and cheeks or lips are equal. When optimum denture stability is difficult to achieve especially in case of resorbed mandibular ridges either in conventional complete dentures or not possible to place implants in some situations on the grounds of medical, surgical or economic factors, the neutral zone technique is an alternative approach for the fabrication of complete denture. This article describes the fabrication of mandibular complete denture using neutral zone technique in severely resorbed mandibular ridge.

Copyright © Reshma Banu, et al 2015 This is an open-access article distributed under the terms of the Creative Commons Attribution License, which permits unrestricted use, distribution and reproduction in any medium, provided the original work is properly cited.

INTRODUCTION

The most common complaint and difficulty in lower denture is pain and looseness¹. As the mandible atrophies at a greater rate than the maxilla and has a lesser residual ridge for retention and support^{1,2}. It is also observed patients with highly atrophic mandible there has been difficulty in positioning the teeth which has led to reduced stability. So one of the most effective techniques is the neutral zone technique to counteract the problems of positioning the posterior teeth leading to a stable and retentive denture³. Other method for stabilization of mandibular complete dentures is dental implants for the atrophic mandible, it is however not possible to provide implants in some situations on the grounds of medical, surgical or economic factors⁴. The objectives of positioning the artificial teeth in the neutral zone is that the teeth does not interfere with the normal muscle function and the forces exerted by the musculature against the denture are more favourable for stability and retention⁵. The facial appearance is also improved with improved support of the facial musculature.⁶

Case Report

A 51-year-old woman reported to the Department of Prosthodontics, Yenepoya Dental College and Hospital, with the chief complaint of loose denture. Clinical examination revealed a severely resorbed, flat mandibular alveolar ridge (fig-1). It was decided to use the neutral zone technique for the fabrication of mandibular denture.

Procedure

- Maxillary and mandibular preliminary impressions were made using irreversible hydrocolloid impression material.
- Border moulding was done with green stick impression compound and a wash impression was made with zinc oxide eugenol.
- To record the neutral zone and the jaw relation, denture bases were fabricated on mandibular cast.
- Retentive tags with orthodontic wire were made on mandibular denture base and impression compound

*Corresponding author: **Reshma Banu**

Department of prosthodontics, Yenepoya Dental College, Yenepoya University, Mangalore, Karnataka – India

mixed with a green stick in the ratio of 3:1 was used to record the neutral zone.

- A water bath, preheated to the adequate temperature, was used to soften the material. The softened compound was kneaded and a roll was made according to the crest and was attached to the mandibular denture base. The attached roll of compound was placed in a hot water bath and was carried into the patient's mouth. With the record base firmly seated, the patient was instructed to perform a series of actions like swallowing, speaking, sucking, pursing lips, and slightly protruding the tongue several times which simulated physiological functioning.
- During function of the lips, cheeks, and the tongue, the forces exerted on the softened compound mold it into the shape of the neutral zone. After a few minutes when the compound has set, the denture base with the compound rim (fig-2) was removed from the mouth and placed in cool a water bath.
- Silicone Putty indices were made around the neutral zone impression (fig-3)
- On another denture base the putty index of neutral zone impression was placed.
- The index had preserved the space of the neutral zone. Wax was poured into the space giving an exact representation of the neutral zone (fig-4) and jaw relation was recorded and articulation of maxillary and mandibular cast was done.

Teeth arrangement

- Mandibular teeth were arranged first using the putty index as guide. During the arrangement of the teeth their positions were checked by placing the putty index around the wax rim (fig-5).
- Maxillary teeth were arranged according to the esthetic rules using the guidance of the lower teeth.
- Try in was done and wax was removed from the labial and buccal surfaces of mandibular trial denture leaving only minimal wax which could support the teeth that were placed.
- Patient was trained for making physiological movements likes swallowing, speaking, sucking, pursing lips, and slightly protruding the tongue. Once the patient was trained regarding the functional movements PVS light body (Aquasil Ultra LV Fast Set; Dentsply Caulk) was placed on the labial and buccal surfaces of the trial dentures (fig-6). It was then placed in the mouth and patient was asked to perform physiological movements.
- Once the try-in was satisfactory the dentures were processed and finished (fig-7).
- Care was taken during finishing and polishing of the dentures so that the contours recorded previously were unaltered.
- The dentures provided the patient with improved facial appearance, stability and retention during function (fig-8).

DISCUSSION

Providing stable mandibular dentures for patients with severely resorbed mandibular ridges is a challenge. One can overcome this problem if dentures are fabricated with their contours harmonizing neutral zone. The neutral zone is the potential space between the lips and cheeks on one side and the tongue on the other. It is the area where the forces between the tongue and cheeks or lips are equal. When the residual alveolar ridges have resorbed significantly, denture stability and retention are more dependent on the correct position of teeth and contour of the external surfaces of dentures. The advantage of this method is prosthetic teeth do not interfere with normal lower denture space, muscle function; and the forces imparted by normal oral and perioral muscle activity against the complete dentures serve to stabilize and retain the prosthesis rather than cause denture displacement⁷. Through this technique a prosthodontist attempts to duplicate the natural function with an artificial substitute. The neutral zone technique can be employed in conditions where either the implant placement is contraindicated or if the treatment is not economically feasible for the patient.

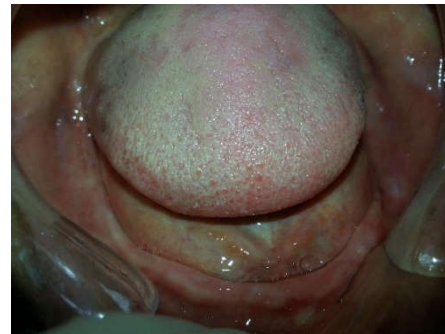

Fig 1 Resorbed mandibular ridge

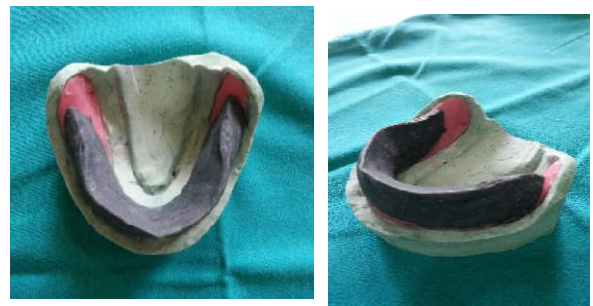

Fig 2 Neutral zone impression

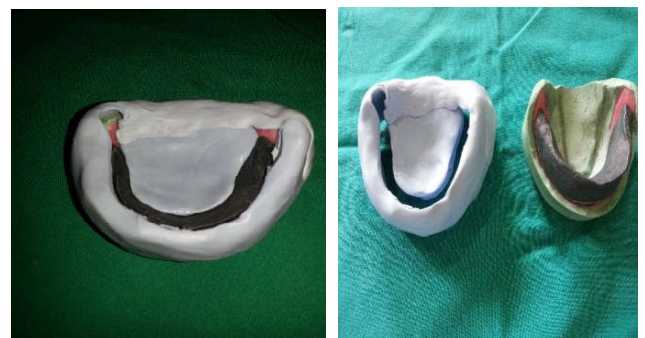

Fig 3 Putty index around the neutral zone impression

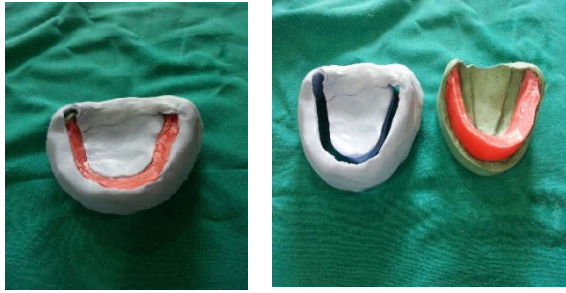


Fig 4 Wax poured in neutral zone space

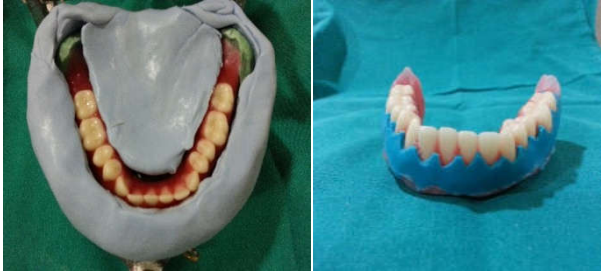

Fig 5 Mandibular teeth arrangement in neutral zone

Fig 6 External impression of polished surface

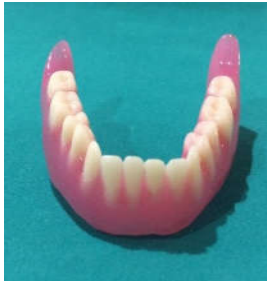

Fig 7 Mandibular complete denture



Fig8 Denture insertion

CONCLUSION

The materials and methods used in this neutral zone technique are simple and inexpensive. The neutral zone technique helps achieve a muscular control which will be main stabilizing and retentive factor during function. An improved prosthodontic therapy is achieved by thorough understanding of the anatomy and physiology of structures that aid in complete denture fabrication and function for edentulous patients, with the neutral zone technique, identifying and registering the anatomy and physiology that impact prosthesis stability.

References

1. Tinker A. Ageing in the United Kingdom-what does this mean for dentistry? *Br Dent J* 2003; 194:369-372.
2. Atwood D A. Post extraction changes in the adult mandible as illustrated by micrographs of midsagittal sections and serial cephalometric roentgenograms. *J Prosthet Dent* 1963; 13: 810-824.
3. Ohkubo C, Hanatani S, Hosoi T, Mizuno Y. Neutral zone approach for denture fabrication for a partial glossectomy patient: A clinical report. *J Prosthet Dent* 2000; 84: 390–393. Mosby Co., 1978.
4. Beresin V E, Schiesser F J. The neutral zone in complete and partial dentures p 15. C.V. Mosby Co., 1978.
5. Beresin VE, Schiesser FJ. The neutral zone in complete dentures. *J Prosthetic Dent* 2006; 95:93-100.
6. Dawson PE. *Functional Occlusion from TMJ to Smile Design*. Canada. Elsevier. 2007. 131-5.
7. Beresin VE, Schiesser FJ. The neutral zone in complete dentures. *J Prosthet Dent* 1976; 36:356-67

How to cite this article:

Reshma Banu *et al.*, Management of Severly Resorbed Mandibular Ridge Using Neutral Zone Technique- A Case Report. *International Journal of Recent Scientific Research Vol. 6, Issue, 11, pp. 7469-7471, November, 2015*

ISSN 0976-3031



9 770976 303009 >