

ISSN: 0976-3031

Available Online at <http://www.recentscientific.com>

International Journal of Recent Scientific Research  
Vol. 7, Issue, 8, pp. 12996-12999, August, 2016

**International Journal of  
Recent Scientific  
Research**

## Research Article

### RISK STRATIFICATION AND PROGNOSIS OF GASTRO-INTESTINAL STROMAL TUMOURS BASED ON IMAGING FINDINGS AND MITOTIC ACTIVITY IN HISTOPATHOLOGY

**AarthiParthasarathy and Sachin.GShatagar**

Father Mullers Medical College, Department of Radiodiagnosis Kankanady Mangalore -575002

*Article History:* Received 05<sup>th</sup> May, 2016, Received in revised form 08<sup>th</sup> June, 2016, Accepted 10<sup>th</sup> July, 2016, Published online 28<sup>st</sup> August, 2016

**Copyright © AarthiParthasarathy and Sachin.GShatagar., 2016**, this is an open-access article distributed under the terms of the Creative Commons Attribution License, which permits unrestricted use, distribution and reproduction in any medium, provided the original work is properly cited.

#### INTRODUCTION

Gastrointestinal stromal tumors (GISTs) are the most common mesenchymal neoplasms of the gastrointestinal tract. The term gastrointestinal stromal tumor defines a unique group of mesenchymal neoplasms that are distinct from true smooth muscle and neural tumors. The histogenesis of GISTs has been debated for over 50 years<sup>1</sup>

Older medical literature referred to these tumors as smooth muscle tumors, leiomyomas, leiomyosarcomas, epithelioid leiomyosarcomas, and leiomyoblastomas because these tumors were believed to originate from the smooth muscle layers of the wall of the gastrointestinal tract. This variable nomenclature has led to considerable diagnostic confusion and is indicative of the diverse radiologic and histologic manifestations of mesenchymal neoplasms<sup>2</sup>

The histological origin of the tumour has been suggested to be the interstitial cells of Cajal because of its expression of ckit and or CD34. Series of HPE criteria have been reported to predict the malignant potential of these tumours but their conclusion varied. It was reported that the prognostic of gist correlated with mitotic count, tumour size, tumour cellularity, necrosis, anatomical location, invasive growth and expression of ki-67 and PCNA index<sup>3</sup>

GISTs are the most common and may occur from the esophagus to the anus. They may also occur primarily in the omentum, mesentery, and retroperitoneum<sup>4</sup>

As a result, GISTs have a wide spectrum of radiologic appearances. This study summarizes the current literature and our recent experience with 42 cases of GIST (gastric, small intestinal, large bowel, from the small bowel mesentery)

Histological criteria have not been well established to predict the malignant potential of GIST. So far pathologists have investigated a series of factors in GIST in trying to predict the prognosis accurately. Among these mitotic count has been emphasized. The cut off of mitotic index has been used in the

older literature as  $> 2/50$  hpf or  $>5/50$  hpf for distinguishing benign and malignant cases and they are available for majority of GIST<sup>5</sup>

#### REVIEW OF LITERATURE

Armed Forces Institute of Pathology (AFIP) criteria (Miettinen's criteria)

The criteria presented by Miettinen *et al*<sup>6</sup> were based on a large series comprising more than 2,000 GISTs from different anatomic sites along the GI tract with long-term follow-up. This risk system is distinguished from the NIH system by taking the anatomic site of the tumor into consideration. Initially defining 8 prognostic subgroups based on size and mitotic count, Miettinen *et al* used in addition the anatomic site to separate four risk groups (very low, low, moderate and high risk) similar to the 4 risk groups in the NIH system with addition of a new group of "benign tumors" that carry no risk of malignancy. Being based on real data the AFIP system has the advantage of delivering numerically calculated risk of tumor relapse and/ or progression, thus enabling clinicians to make solid therapeutic decisions more reliably. The prognostic significance of anatomic site was confirmed in other studies as well [15]. The single major drawback in the eye of some clinicians and/ or general pathologists is the presumable complexity of the AFIP system being composed of 8 prognostic subgroups and that the excessive subdivision of the different subgroups might reduce the prognostic sensitivity and specificity of recurrence DeMatteo *et al*<sup>7</sup> (2008) evaluated data for 127 patients with primary GIST and confirmed the AFIP finding that tumor site (anatomical location) is an independent prognostic factor, along with tumor size and mitotic rate.

Goh *et al*<sup>8</sup> (2008) applied the NIH/Fletcher risk criteria (Table 2), a modification of the NIH/Fletcher scheme, and the Miettinen and Lasota / AFIP criteria (Table 3) to the records for all the GIST patients treated in one hospital over many years. The Miettinen and Lasota / AFIP criteria proved superior in predicting patient outcome. Goh *et al* did note that there is a wide spread of recurrence rates within the AFIP high-

\*Corresponding author: **AarthiParthasarathy**

Father Mullers Medical College, Department of Radiodiagnosis Kankanady Mangalore -575002

risk group. *Goh et al* demonstrated that it is useful for patient outcome prediction to add a "very high risk" group with tumor size > 10 cm and mitotic count > 5 per 50 HPFs. That is to say, for patients with mitotic counts >5 per 50 HPFs, those with tumors between 5 and 10 cm had fewer recurrences than those with tumor size >10 cm.

**MATERIALS AND METHODS**

**Objective:** Aim of the study was to establish any helpful and reproducible parametrs to indicate malignant potential and be used practically and objectively in the risk of malignant potential diagnosis of GIST.

This is a prospective study done on 42 patients who were suspected to have abdominal mass on ultrasound and was referred for CT scan of the abdomen to the Department of Radio Diagnosis at our hospital. The study was conducted for a period of 1year starting from December 2014 to December 2015. Ethical clearance was taken from the institutional ethical committee.

**Inclusion criteria:** All patients with clinically suspected mass or intestinal obstruction, who are referred to our department for abdominal CT scan for evaluation of obstruction and whose follow up regarding surgical or conservative management is available.

**Exclusion criteria:** Patients in whom either CECT could not be performed or for whom follow up was not available

**Imaging Protocol:** CT examinations were done on GE Bright Speed multidetector 16 slice CT.

Contrast was administered using bolus tracking technique. All patients were given intravenous contrast agent, 80-100 ml of iodinated water-soluble non-ionic contrast medium (1-1.5ml/kg wt.), by a power injector. Inj. Ultravist or Omnipaque (300 mg/ml) is used as the iodinated contrast for intravenous injection.

Intravenous contrast injection is set at 3-4 ml/sec. Plain and contrast images were acquired at 5mm thickness and 5mm intervals. Thin reconstructions to 1.25 mm thickness were obtained and axial, coronal and sagittal reformatted images were studied.

Ct criteria used included the study of tumours under the following headings necrosis, haemorrhage, ulceration, calcifications etc

Involvement of the adjacent in the form of: Metastasis, Lymphnode encasement, ascites, peritoneal deposits, Exophyticvsendophytic component

CT findings were correlated with HPE – classification of spindle cells and mitotic activity and Immunohisto chemistry to prove GIST.

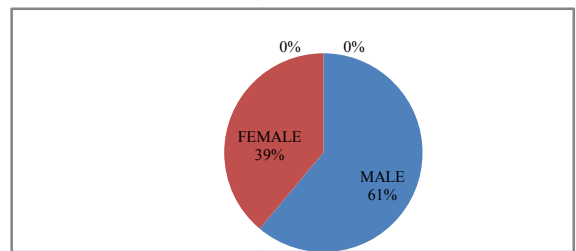
No mitosis group, low mitosis group and high mitosis group were defined depending on mitotic rates as described previously

**OBSERVATIONS AND RESULTS**

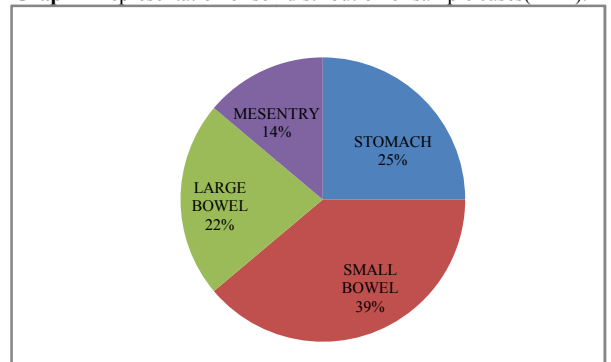
42 patients were selected from cases of tumours previously diagnosed as leiomyoma, leiomyoblastoma and

leiomyosarcoma in the time period. All specimens were from patients who underwent complete surgical excision without record of positive margin. Clinical information including tumour size was obtained from surgical and pathological records. Tumours that developed recurrence or metastasis were judged as malignant. Tumours with peripheral invasive growth microscopically were also diagnosedas malignant. The other cases without the above evidence of malignancy were classified as benign in the study although there is still a chance of malignancy in this group.

42 CT examinations of abdominal tumour like masses were studied of which 36 were proven by biopsy and immunohisto chemistry. 6 cases were deferred from surgery (16% managed conservatively) and 4 cases were not proven. The mean age of presentation of male patients was 55.4+/- 10.3 years while that of females was almost a decade later (mean=65.8+/- 9.6 years)

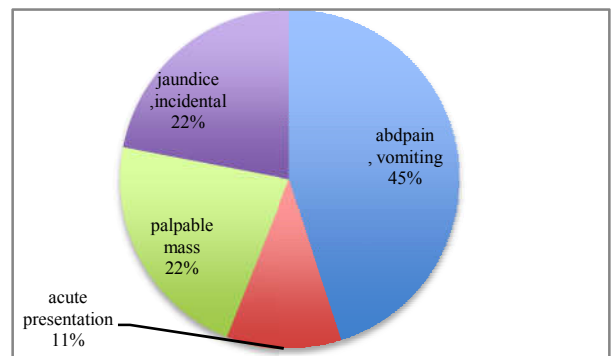


**Graph 1** Representation of sex distribution of sample cases(n=42).



**Graph 2** Representation of the various sites of occurrence of sample cases (n=42)

Among the studied cases. The sites of occurrence were broadly classified into 4 subsites stomach, small bowel, large bowel and mesentery with frequency of occurrence of GIST being most common in small bowel (35%) followed by stomach(25%).

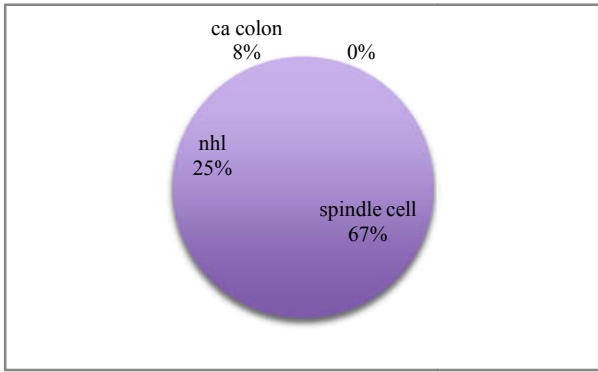


**Graph 3** Representation of various presenting complaints of sample case s(n=42)

Abdominal pain followed by vomiting was the most common complaint seen in 45% followed by similar percentage of jaundice and palpable mass. Acute presentation was seen in 11% of the cases.

Morphologically these lesions were predominantly exophytic (83%), only 4 were endophytic.

On contrast examination, majority had heterogenous enhancement (86.4%), being supplied by the major arteries based on location SMA (47.2%) followed by celiac artery (34%)

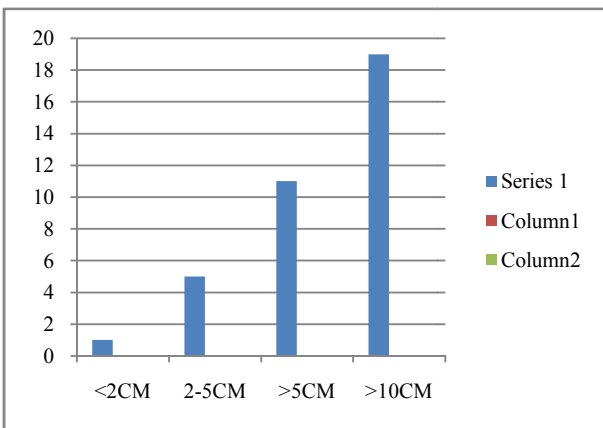


Graph 4 Representation of histopathology of sample cases (n=42)

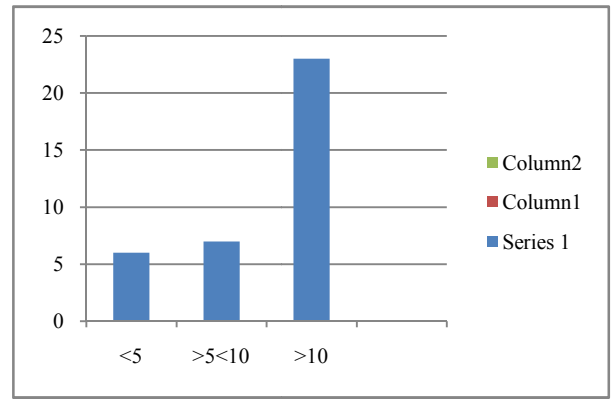
On HPE, results were as follows: spindle cell GIST (74.3%), Non Hodgkins (6%) and carcinoma colon (2.08%). Immunohisto chemistry was positive in 14 cases (41.7%)

Table 1 Representation of frequency and percentage of sample cases based on mitotic activity and tumour size.

Mitotic activity	Frequency	percentage
No mitosis	1	2.7%
<5/50 hpf	9	25%
>5/50 hpf	17	47.2%
>10/50	9	25%
Tumour size(cm)	frequency	percentage
<2	1	2.7%
2-5	4	11.1%
>5	14	38.9%
>10	17	47.2%

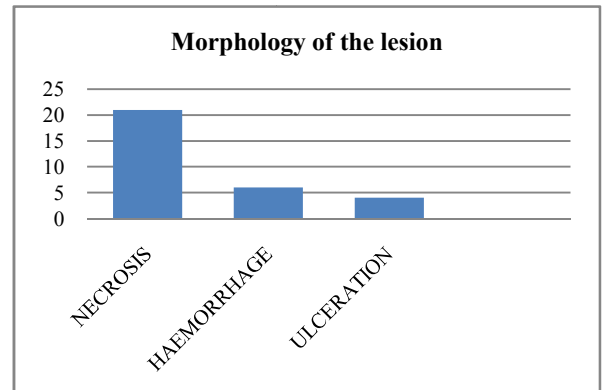


Graph 5 Representation of tumour size noticed among sample cases. Most of the lesions (18) were noted with size greater than 10 cm followed by greater than 5 cm (12).



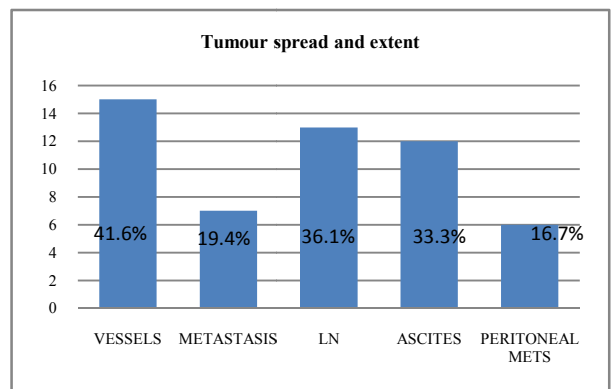
Graph 6 Representation of mitotic count on histopathology among the sample cases

Majority of the lesions on HPE showed mitotic count >10 hpf favouring malignant potential. The mitotic count in the range of 5-10 hpf and <5 hpf did not vary much in number.



Graph 7 Representation of various morphological features in sample cases

Necrosis was the most common morphological feature seen in 21 cases followed by haemorrhage in 7 cases. Other features like ulceration and calcification were appreciated in minority of cases.



Graph 8 Representation of various features demonstrating tumour spread and extent

Among the various imaging features representing tumour spread and extent in sample cases involvement of vessel was seen in 41.6% followed by lymphadenopathy in 36%. The least common feature was peritoneal involvement seen in 16.7%.

**Table 2** Significance of various morphological features and HPE used in this study

Morphology features	p values
Necrosis	0.081
Ulceration	0.075
Haemorrhage	0.67
Metastasis	0.006
Lymphnodes	0.04
Ascites	0.067
Peritoneal deposits	0.004
Morphology features	p values
Tumour size >10cm	0.045
Mitotic rate	0.067
Combination of tumour rate and mitotic rate	0.023

Univariate analysis demonstrated that mitotic count, cellularity, haemorrhage, tumour necrosis and p53 immunostaining were correlated significantly with poor prognosis. On multivariate analysis IHC and cellularity were significant independent prognostic factors, however we failed to obtain a sig p value to indicate a mitotic count as an independent variable. This was probably due to limited sample size and inclusion of cases that had surgical interventions due to obstructive features. Mitotic count and IHC markers could not be attained for all the sample cases.

### Summary

In this study we tried to classify the various morphological features in the presentations of GIST on CT and classify them as benign or malignant based on mitotic count as gold standard. However we were not able to achieve a significant correlation between malignant potential and increased mitotic count. We concluded that given potential for mitotic count in staging GIST and its prognosis according to various literature cited, a similar study can be continued to see its longterm outcome.

### References

- King DM. The radiology of gastrointestinal stromal tumours (GIST) *Cancer Imaging*. 2005;5:150–6
- Kindblom L-G, Remotti HE, Aldenborg F, Meis-Kindblom JM. Gastrointestinal pacemaker cell tumor (GIPACT): Gastrointestinal stromal tumors show phenotypic characteristics of the interstitial cells of Cajal. *Am J Pathol*. 1998; 152:1259–1269. [PMC free article]
- Hirota S, Isozaki K, Moriyama Y, Hashimoto K, Nishida T, Ishiguro S, Kawano K, Hanada M, Kurata A, Takeda M, Muhammad Tunio G, Matsuzawa Y, Kanakura Y, Shinomura Y, Kitamura Y. Gain-of-function mutations of c-kit in human gastrointestinal stromal tumors. *Science*. 1998; 279:577–80.

- Joensuu H, Roberts PJ, Sarlomo-Rikala M, Andersson LC, Tervahartiala P, Tuveson D, Silberman S, Capdeville R, Dimitrijevic S, Druker B, Demetri GD. Effect of the tyrosine kinase inhibitor STI571 in a patient with a metastatic gastrointestinal stromal tumor. *N Engl J Med*. 2001; 344:1052–6.
- Sripathi S, Rajagopal K, Srivastava RK, Ayachit A. CT features, mimics and atypical presentations of gastrointestinal stromal tumor (GIST) *Indian J Radiol Imaging*. 2011; 21:176–81.
- Miettinen M, Lasota J. Gastrointestinal stromal tumors: pathology and prognosis at different sites. *SeminDiagnPathol*. 2006; 23:70–83.
- De MatteoRP, LewisJJ, LeungD, MudanSS. Two hundred gastrointestinal stromal tumours:recurrence patterns and prognostic patterns for survival. *Ann Surg*.2000;231:51-8
- Goh, B.K.P, Chow, P.K.H, Yap, W.*et al*. Comparison of contemporary Prognostic Criteria in 171 tumours and a proposal for Modified Armed Forces Institute of Pathology Risk Criteria. *AnnSurg Oncol*.2008;15:2153
- Patnaik S, Jyotsnarani Y, Rammurti S. Radiological features of metastatic gastrointestinal stromal tumors. *J Clin Imaging Sci*. 2012;2:43
- Bearzi I, Mandolesi A, Arduini F, Costagliola A, Ranaldi R. Gastrointestinal stromal tumor. A study of 158 cases: clinicopathological features and prognostic factors. *Anal Quant CytolHistol*. 2006 Jun; 28(3):137-47.
- Cho S, Kitadai Y, Yoshida S, Tanaka S, Yoshihara M, Yoshida K, ChayamaK. Deletion of the KIT gene is associated with liver metastasis and poor prognosis in patients with gastrointestinal stromal tumor in the stomach. *Int J Oncol*. 2006 Jun;28(6):1361-8
- Fletcher CD, Berman JJ, Corless C, Gorstein F, Lasota J, Longley BJ, Miettinen M, O'Leary TJ, Remotti H, Rubin BP, Shmookler B, Sobin LH, Weiss SW. Diagnosis of gastrointestinal stromal tumors: A consensus approach. *Hum Pathol*. 2002 May; 33(5):459-65. PMID: 12094370
- Tryggvason G, Kristmundsson T, Orvar K, Jónasson JG, Magnússon MK, Gíslason HG. Clinical study on gastrointestinal stromal tumors (GIST) in Iceland, 1990-2003. *Dig Dis Sci*. 2007;52:2249–2253
- Tran T, Davila JA, El-Serag HB. The epidemiology of malignant gastrointestinal stromal tumors: an analysis of 1,458 cases from 1992 to 2000. *Am J Gastroenterol*. 2005; 100:162–168.
- Lau S, Lui CY, Yeung YP, Lam HS, Mak KL. Gastrointestinal stromal tumor of rectum: a report of 2 cases. *J Comput Assist Tomogr*. 2003; 27:609–615.

\*\*\*\*\*

### How to cite this article:

AarthiParthasarathy and Sachin.GShatagar.2016, Risk Stratification and Prognosis of Gastro-Intestinal Stromal Tumours Based on Imaging Findings and Mitotic Activity In Histopathology. *Int J Recent Sci Res*. 7(8), pp. 12996-12999.