



RESEARCH ARTICLE

**HISTOPATHOLOGICAL EFFECTS OF SUB LETHAL EXPOSURE TO 1, 2-DICHLOROBENZENE ON GILLS AND LIVER OF *CATLA CATLA* (HAMILTON)**

**NirmalaGanesan<sup>a</sup> G.N., Kantha Devi Arunachalam\* and Selvam Ganapthy<sup>b</sup>**

Center for Environmental Nuclear Research, Directorate of Research, SRM University, Chennai- 603203

**ARTICLE INFO**

**Article History:**

Received 12<sup>th</sup>, August, 2013  
Received in revised form 26<sup>th</sup>, August, 2013  
Accepted 16<sup>th</sup>, September, 2013  
Published online 30<sup>th</sup> September, 2013

**Key words:**

1,2dichlorobenzene, *Catla catla*, Histopathology, Gill, Liver

**ABSTRACT**

Histopathological studies in organs like gill and liver of *Catla catla* (Hamilton) were made to assess tissue damage due to sublethal concentration of 1, 2 dichlorobenzene and provides a real picture of the detrimental effects and the involvement of the volatile organic compound toxicants in the major vital functions such as respiration metabolism and reproduction in aquatic animals. The gill of 1, 2 dichlorobenzene exposed fish exhibited edema, secondary lamellar with severe cytoplasmic vacuolation and mononuclear cell infiltration surrounding the stem of the primary lamellae, lamellar degeneration and haemorrhage. The liver of *Catla catla* exposed to 1, 2 dichlorobenzene showed multifocal necrosis of hepatocytes, psychosis, disintegration of cells and vacuolization. In addition internal haemorrhage was also seen. Such pathological changes were observed in all the tissues were more pronounced in sublethal concentration for 28 days of exposure at One-second, one-fourth, one-sixth and one- eighth of the LC<sub>50</sub>, i.e., (0.7, 0.35, 0.23 and 0.175 mg/L) of the 96hrs LC<sub>50</sub> value. The observation of the present study is to suggest that the damage of these tissues is caused by cumulative accumulation of 1, 2 dichlorobenzene in tissues. The results suggest that the 1, 2 DCB even in low concentration might be harmful to the aquatic organisms.

© Copy Right, IJRSR, 2013, Academic Journals. All rights reserved.

**INTRODUCTION**

Dichlorobenzene are used primarily as reactants in chemical synthesis, as process solvents, and as formulation solvents (International Agency for Research on Cancer (IARC 1999; U.S. EPA 1981). It is used in the production of 3,4dichloroaniline, a base material for herbicides; as a solvent for waxes, gums, resins, tars, rubbers, oils, and asphalts; as an insecticide for termites and locust borers; as a degreasing agent for metals, leather, paper, dry cleaning, bricks, upholstery, and wool; as an ingredient in metal polishes; in motor oil additive formulations; and in paints. The lipid solubility of dichlorobenzene suggests the potential for bio concentration such that consumption of fish or shellfish may result in exposure to 1, 2-DCB (Azouz 1955). 1, 2-Dichlorobenzene has been tested on a wide range of aquatic organisms under acute exposure, although chronic data are scarce. 1, 2-dichlorobenzene has the potential to bio accumulate, and in the fatty tissue of aquatic species (Mensink et al, 1995). The aquatic environment is continuously being contaminated with toxic chemicals from industrial agricultural and domestic activities.

Histopathological studies have been conducted to help establish causal relationship between contaminated exposure and various biological responses. It should also be given equal importance to bioassay and ethological studies, in determining the causes of death and predicting the mode of action of toxicants. Bioassays are important tools to evaluate toxic effects and impact of volatile organic compounds on fresh water fish and estuarine organisms (Hansen 1978). Therefore the investigations have proved to be

sensitive tool to detect direct effects of chemical compounds within target organs of fish in laboratory experiments. The present study is carried out in *Catla catla* (Hamilton) is the prime cultured species in India that occupies a prominent position in aquatic system. Hence, an attempt is made to study the histopathological changes in tissues of the fish *catla catla* when exposed to sub lethal concentrations. The objectives of such bioassays are to determine the pollutant concentration that is harmful to organisms, its persistence and degradability, rate of accumulation (Coppage 1976). The extent of severity of tissue damage is a consequence of the concentration of toxicant and is time dependent. Also the severity of damage depends on the toxic potentiality of a particular compound or volatile organic compound accumulated in the tissues. Histopathological alterations in the fish gills have been used in biomonitoring the effects of various pollutants in the aquatic environment (Paulose 1989; Dhanapakiam et al. 1998). Environmental stress causes a variety of detectable and recognizable behavioral changes in fish which constitute an index to measure the toxicity of any pollutant (Palanichamy & Baskaran, 1995; Murugaian, et.al. 2008). However the studies on the histopathological effect of 1, 2 DCB on the fresh water fishes are very limited. Therefore, the present study is proposed to assess the 1, 2 DCB toxicity on the histopathological changes of vital organs like gill and liver of fish *Catla catla* and to find out the possible histological alterations on exposure to sub lethal concentrations of 1, 2 dichlorobenzene.

\* Corresponding author: **Kantha Devi Arunachalam**

Center for Environmental Nuclear Research, Directorate of Research, SRM University, Chennai- 603203

## MATERIALS AND METHODS

### Fish

For this experiment, *Catla catla*, were obtained from Bharath fish seed farm, poondi, Tamil Nadu and acclimatized to laboratory condition for 15 days prior to the experiment in a glass aquarium (150L) filled with dechlorinated water. Water quality characteristics were determined by standard method (APHA 1988). The mean values for test water qualities were as follows: pH  $7.5 \pm 0.03$ , dissolved oxygen  $6.4 \pm 0.2 \text{ mg/l}$ , alkalinity  $250 \pm 2.8 \text{ mg/L}$  as  $\text{CaCO}_3$ , total hardness  $456 \pm 3.5 \text{ mg/L}$ . Fish were fed on commercial pellets contain 30% protein twice a day for 15 days. Feeding rate was made by 4% of fish weight. The fishes were maintained on a photoperiod with 12h light/12h dark. For the present investigation, sigma grade 1, 2 dichlorobenzene (99.99%) was obtained from SISCO, INDIA. The stock solution was prepared in alcohol, which was found to be non-toxic to fish.

### Experimental design

Approximately 150 healthy fish (10 fish/aquarium, 3 replicates/treatment) at equal size and length were divided in groups in aquaria and then fish was starved 1 day before the test was performed. Fish were exposed to series of concentrations of the tested 1,2 DCB (volatile organic compound) to determine 50% lethal concentration ( $\text{LC}_{50}$ ); (0-control, 0.2ppm, 0.4ppm, 0.6ppm, 0.8ppm, 1.6ppm and 3.2ppm for 96h. Acute toxicity tests were conducted to measure the impact of toxicity on the fishes within a short period (Sprague, 1969). Control fish was maintained in similar aquaria that contain only clean dechlorinated tap water. Dead fish was removed from the aquaria as soon as possible to avoid polluting the contaminated water causing changes in the aquaria's maintained conditions. The concentration of 1,2 dichlorobenzene at which 50% mortality occurred was taken as the median lethal concentration ( $\text{LC}_{50}$ ) for 96h, was found to be  $1.4 \text{ mg/L}$ . Results were then subjected to probit analysis (Finney 1971) to determine  $\text{LC}_{50}$ . The toxicity studies were conducted following the static bioassay method (OECD). During this experiment the behavioural changes were also observed.

The fish were divided into five groups and placed in separate glass aquaria. A total of 15 fish were used for each group. Groups 2, group 3, group 4 and group 5 were exposed to sub lethal concentration of 1, 2 DCB. Group 1 was maintained in 1, 2 DCB-free water to serve as control. After treatment, both the experimental and control fishes were sacrificed 1, 7, 14, 21 and 28<sup>th</sup> day at 5 days interval. Gill and liver tissues were removed and dropped in aqueous Bouin's fluid. After fixation, tissues were dehydrated through a graded series of ethanol, cleared in xylene and infiltrated in the paraffin. Sections of  $4\text{-}6 \mu\text{m}$  were prepared from paraffin blocks by using a rotary microtome. These sections were then stained with Haematoxylin-Eosin. Histopathological lesions were examined and photographed, using Lecia photomicroscope

## RESULTS

### Clinical signs

There were changes in the frequency of movement of the fish subjected to different concentrations of 1, 2 dichlorobenzene. Behavioural changes such as uncoordinated movements, somersaulting, convulsion, excess secretion of mucus, erratic swimming and increase in operculum ventilation, respiratory distress, strong spasm, paralysis, sudden quick movement and

prior to the death, darkening of fish were observed during the exposure of fish to 1,2 dichlorobenzene. The colour of the skin of fish exposed to the toxicant changed from normal darkly pigmentation in the dorsal of and lateral parts.

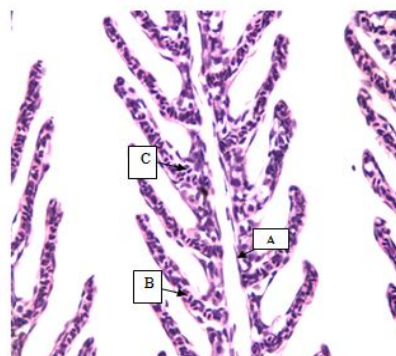


Figure 1 Photomicrograph of gill of control *Catla catla* showing normal structure A- Primary lamellae, B-Secondary lamellae, C- Epithelial cell (H&E, 400 x).

### Histology

#### Gills

The gills of the control fish showed no significant lesion normal gill architecture seen in (Fig.1A). In the controlled set no histopathological changes were observed. All the structures like gill racker, primary lamellae, secondary lamellae, epithelial cell was seen in (Fig.1).

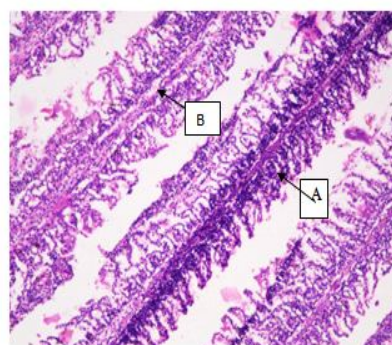


Figure 2. Photomicrograph of gill of exposed to *Catla catla* showing A- Secondary lamellae with severe cytoplasmic vacuolation, B- Mononuclear cell infiltration surrounding the stem of the primary lamellae (H&E, 400 x).

In 7<sup>th</sup> day treated section edema, secondary lamellar with severe cytoplasmic vacuolation and Mononuclear cell infiltration surrounding the stem of the primary lamellae was seen (Fig.2).

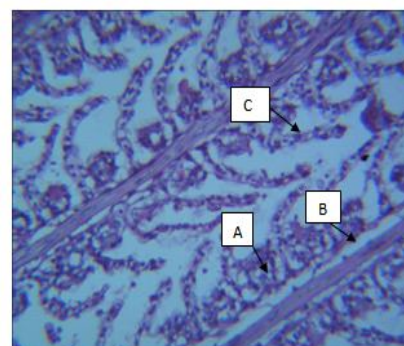
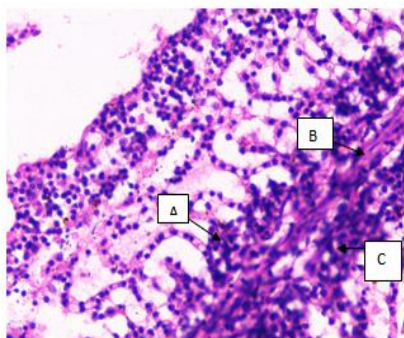
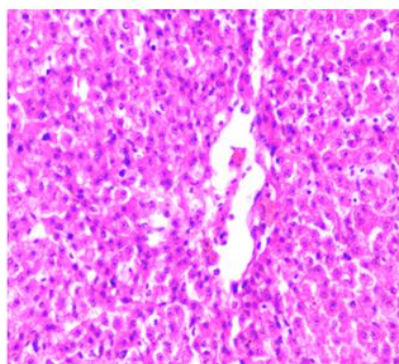


Figure 3. Photomicrograph of gill of exposed to *Catla catla* showing A- Edema, B- Desquamation, C- Epithelial lifting (H&E, 400 x).



**Figure 4.** Photomicrograph of gill of exposed to *Catla catla* showing A- Shortening of secondary lamellae, B- Lamellar degeneration, C- Haemorrhage (H&E, 400 x).

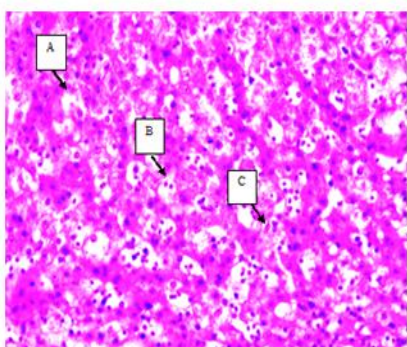
In 14<sup>th</sup> and 21<sup>st</sup> day treated section desquamation in primary and secondary lamellae, Epithelial lifting was evident, (Fig.3). In 28<sup>th</sup> day treated section shows shortening of secondary lamellae, lamellar degeneration and haemorrhage were visible (Fig.4).



**Figure 5.** Photomicrograph of liver of control *Catla catla* showing normal structure (H&E, 400 x).

### Liver

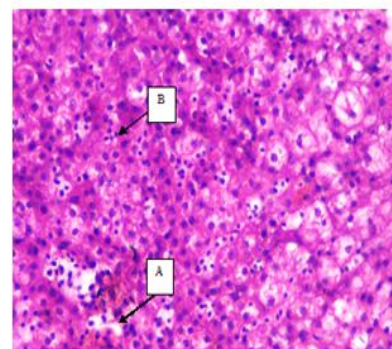
The liver of control fish *Catla catla* showing normal structure seen in (Fig.5). The histopathology alterations in the liver of fish exposed to 1,2 DCB indicated the haemorrhage in central lobular vein, psychosis, fibrosis and degeneration of hepatocytes seen in 7<sup>th</sup> and 14<sup>th</sup> day was seen in (Fig. 6).



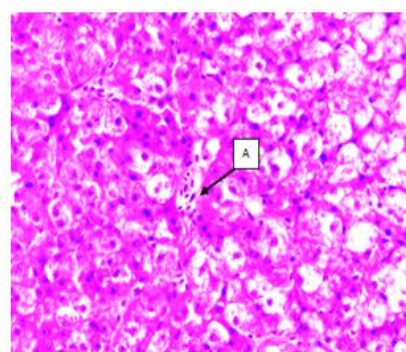
**Figure 6.** Photomicrograph of liver of exposed to *Catla catla* showing A-Haemorrhage in central lobular vein, B-Pyknotic nuclei, C- Fibrosis (H&E, 400 x).

Whereas, these effects were severe in the liver tissue of fish exposed to 1, 2 DCB on 21<sup>st</sup> day vacuolization in perinuclear space, diffuse sinusoidal dilatation was seen in (Fig. 7). On day 28<sup>th</sup> multifocal necrosis of hepatocytes surrounded with hemorrhage and mononuclear infiltration was seen (Fig. 8). DCB caused a number of pathological changes in the liver since it is the

first organ to face any foreign molecule that is carried through portal circulation. 1, 2 dichlorobenzene has induced discrete pathological changes in the liver tissues of fish *Catla catla*. A high concentration of 1, 2 DCB had been correlated with liver damage.



**Figure 7.** Photomicrograph of liver exposed to *Catla catla* showing A- Vacuolization in perinuclear space, B- Diffuse sinusoidal dilatation (H&E, 400 x).



**Figure 8.** Photomicrograph of liver of exposed to *Catla catla* showing A- multifocal necrosis of hepatocytes surrounded with hemorrhage and mononuclear infiltration (H&E, 400 x).

### DISCUSSION

Toxicity of 1, 2 dichlorobenzene to *catla* is relatively lower when compared with other species of fishes. The 96r LC<sub>50</sub> value (1.4mg/L) obtained in the present study is lower than the values reported in literature for other species of fishes *Brachydanio rerio* (zebra fish) LC<sub>50</sub>=6.8mg/L (Calamari et al. 1983), *Oncorhynchus mykiss* (Rainbow trout), LC<sub>50</sub>=1.61mg/L (Ahmad et al. 1984) *Cyprinodon variegatus* (Sheeps head minnow) LC<sub>50</sub>=9.3mg/L (Heitmuller et al.1981) *Lepomis macrochirus* (Bluegill sunfish) LC<sub>50</sub>=6.3mg/L (Buccafusco et al.1981) *Pimephales promelas* (Fathead minnow) LC<sub>50</sub>=57mg/L (Curtis and Ward 1981). These values indicate that these compounds are more toxic to fish than 1, 2 dichlorobenzene. Changes in behavioral patterns exhibited by fish were possibly to counteract aquatic hypoxia condition possibly caused by the agrochemical (Kind et al., 2002). When there is impossibility of escape from hypoxic stress, physiological alterations may be evoked to compensate for low oxygen supply (Graham, 2003).

Histopathological changes were well pronounced in the tissues of *Catla catla* exposed to different concentrations. The alterations in the behavioural pattern are the most sensitive indication of potential toxic effectsills are the first target organ of several pollutants because of their very large interface area between external and internal fish environment, performing vital functions such as gas exchange and ion osmoregulation and they are partially sensitive to adverse environmental conditions. In this study, no recognizable changes were observed in the gills of the

control fishes each gill consists of primary filament and secondary lamellae. Large variations occurred in the pattern of 1, 2 dichlorobenzene accumulation in different tissues of *catla catla* after the exposure to (0.7, 0.35, 0.23 and 0.175 mg/L) for a sub acute (28 days). The high 1, 2 dichlorobenzene levels in gill tissue can possibly be due to the fact that they are the main sites for 1, 2 dichlorobenzene uptake, particularly in freshwater fish and due to the large surface that is in contact with environmental water and the very thin barrier separating the external and internal media of the animal. Organ-wise distribution of residual of 1, 2 dichlorobenzene revealed that the gills are the prime site of accumulation with highest persistence, which followed by liver in the test fish throughout the exposure period. The Present findings are strongly supported by the works of (Cengiz 2006; Tilak et al. 2001; Velmurugan et al. 2007; Fernandes et al. 2006) who studied histopathological changes in the gills of *Channa punctatus* (Bloch.) observed histopathological effects of  $\delta$ -methrin on the gill of the common carp; *Cyprinus Carpio* (Linn.) were reported.

As compared to the gills of controlled fish indicating that the 1, 2 DCB of aquatic ecosystem induced considerable chemical stress on fish populations. The present findings are in agreement with who also observed the same histopathological changes in the gills of various fishes on exposure to different toxins resulting in necrosis, vacuolar degeneration, desquamation, epithelial lifting, edema, shorting of secondary lamellae and lamellar fusion. All these histopathological research studies on the gills of fishes proved to be supporting the results of the present investigation. Considerable interest has been shown in recent years in histopathological study while conducting sublethal tests in fish. Tissue changes in test organisms exposed to a sub-lethal concentration of toxicant are a functional response of organisms which provides information on the nature of the toxicant. The study of histopathological effects of pollutants on the different organs of fish is an important basic effort leading to understanding the impact of pollutants on a given ecosystem (Balah et al., 1993; Banerjee and Chandra, 2005; Mohamed, 2008; Vinodhini and Narayanan, 2009; Gurcu et al., 2010). The gills are not only the prime organs for gaseous exchange; they also perform several other physiological functions including osmoregulation and excretion. They remain in close contact with the external environment, and particularly sensitive to changes in the quality of the water. Gills are the first target of waterborne pollutants due to the constant contact with the external environment. Changes in environmental parameters often damage this vital organ because of its delicate structure. It is well known that changes in fish gill are among the most commonly recognized responses to environmental pollutants (Mallatt, 1985, Laurent and Perry, 1991; Perry and Laurent, 1993). The liver has the ability to degrade toxic compound, but its regulating mechanisms can be overwhelmed by elevated concentrations of this compound, and could subsequently result in structural damage (Brusle et al. 1996). Similarly, in the present study, an apparent structural damage could be seen in the liver of fishes exposed to 1, 2 dichlorobenzene with compared to control. The high incidence of histopathological score reflects the degenerative effect of 1, 2 DCB on fish liver. Very few reports are available on animals other than fish exposed to different Volatile organic compounds. Although 1, 2 DCB is an important waterborne toxicant to aquatic organisms, particularly fish, when ambient concentrations exceed physiological thresholds. Fish samples can be considered as one of the most significant indicators in freshwater systems for the estimation of volatile organic compounds pollution level. Recent

evidence indicates that fish, an extremely valuable resource, are quickly becoming scarce. The commercial and edible species have been widely investigated in order to check for those hazardous to human health.

## CONCLUSION

The results of present study indicate that 1, 2 dichlorobenzene exerts toxic effects on fish. The 96h LC50 values 1.4mg/L for *catla catla* suggest that the fish show a quick response to toxicant. This is an agreement with the findings of (Joshi et al 2002). The use of histopathological techniques is a promising area of research in aquatic toxicology as it gives the real picture of the effects imposed and the involvement of the volatile organic compounds in either disturbing or destroying the vital organ of living organisms.

## Reference

- Ahmad N, Benoit D, Brooke L, Call D, Carlson A, DeFoe D, Huot J, Morairity A and Richter J (1984) Aquatic Toxicity Tests to Characterise the Hazard of Volatile Organic Chemicals in Water: Toxicity Data Summary – Parts I and II. EAP 600/3-84-009, US EPA Environmental Research Lab, Duluth, MN: 103p.
- APHA (1980) Standard methods for examination of water and waste water 15th Ed. N. Y. USA.
- Azouz, W.M., Parke, D.V. & Williams, R.T (1955) Studies in detoxication. 62. The metabolism of halogenobenzenes. *ortho*- and *para*-Dichlorobenzenes. *Biochem. J.*, **59**, 410–415.
- Balah, A. Z. El-Bouhy and M. Easa, (1993) Histologic and histopathologic studies on the gills of *Tilapia niloticus* (*Oreochromis niloticus*) under the effect of some heavy metals. *Zagazig Veterinary Journal*, 21: 351-364.
- Banerjee, T.K. and Chandra S (2005) Estimation of zinc chloride contamination by histopathological analysis of the respiratory organs of the air breathing 'murrel' *Channa striata* (Bloch, 1797) (Channiformes, Pisces). *Vet. arhiv* 75, 253-26.
- Brusle J., Gonzalez I., Anadon G., In Munshi JSD., Dutta HM (1996) the structure and function of fish liver. *Fish Morphology*. New York: Science Publishers Inc.
- Buccafusco, R.J., Ells, S.J. and LeBlanc, G.A (1981) Acute Toxicity of Priority Pollutants to Bluegill Sunfish (*Lepomis macrochirus*)"; *Bull. Environ. Contam. Toxicol.* 26, pp 446-452.
- Calamari, D., Galassi, S., Setti, F. and Vighi, M (1983) Toxicity of Selected Chlorobenzenes to Aquatic Organisms"; *Chemosphere*, 12, pp 253-262.
- Cengiz E I (2006) Histopathological of gill and kidney in the fresh water; *Cyprinus carpio* (Linn.) after acute exposure to  $\delta$ -methrin. *Environmental Toxicology Pharma* 2: 13-16.
- Coppage DL., (1976) River pollution by anticholinesterase agents USEDA Environ. Res. Lab., Gulf Breeze, contribution No. 227: 19-24.
- Curtis, M. W. and Ward, C. H. (1981) Aquatic Toxicity of Forty Industrial Chemicals: Testing in Support of Hazardous Substance Spill Regulation"; *J. Hydrol.* 51, pp 359-367.
- Dhanapakiam P, Ramasamy V K and Poorani S (1998) A study on the histopathological changes in gills of *Channa punctatus* (Bloch.) in Cauvery river water. *Journal of Environmental Biology* 19(3): 265-269.

- Dhanapakiam, P. et al (1998) A Study on the histopathological changes in gills of *Channa punctatus* in Cauvery river water J. Environ Biol. 19(3) -265-269.
- EPA (Environmental Protection Agency (1981) an exposure and risk assessment for dichlorobenzenes. Office of Water, Regulations and Standards, Washington, DC; EPA/440/481/019.
- Fernades A F, Cardoso J V F, Sontos S G and Carrola S M J (2006) Histopathological changes in the liver and gill epithelium of *Oreochromis niloticus*, exposed to copper. *Bulletin of Environmental Contamination Toxicology* 76(2): 249-255.
- Finney, P.J (1971) Probit analysis 3<sup>rd</sup> edition. Cambridge University Press, Cambridge, London.
- Graham M, Iwama GK (2003). The physiological effects of anaesthetic ketamine hydrochloride on two *Salmorid* species. *Aquaculture* 90:3-4; 323-331.
- Hansen DJ, Schimmel SL and Goodman LR. (1978) Life cycle toxicity tests using sheephead minnow *Cyprinodon variegatus*. In: Bioassay Procedures for the Ocean Disposal Permit Programme, EPA- 600/ 19- 78- 010. P 109- 117.
- Heitmuller P, Hollister T and Parrish P (1981) Acute Toxicity of 54 Industrial Chemicals to Sheepshead Minnows (*Cyprinodon variegatus*). *Bull. Environ. Contam. Toxicol.* 27(5): 596-604.
- IARC (International Agency for Research on Cancer) (1999) IARC monographs on the evaluation of carcinogenic risk of chemicals to humans. Vol. 73. Some chemicals that cause tumors of the kidney or urinary bladder in rodents and some other substances. Lyon, France: International Agency for Research on Cancer, pp. 223-276.
- Joshi, P., D. Harish and M. Bose (2002) Effect of lindane and Malathion exposure to certain Blood Parameters in freshwater teleost fish *Clarias batrachus*. *Poll. Res.*, 4: 1-6. 21: 55-57.
- Kind PK, Grigg GC, Booth GT (2002). Physiological responses to prolonged aquatic hypoxia in the Queensland lungfish, *Neoceratodus forsteri*. *Resp. Physiol. Neurobiol.* 132:179-190.
- Laurent P. and Perry, S.F. 1991. Environmental effects on fish gill morphology. *Physiol. Zool.* 53:4-25.
- Mallatt J (1985) Fish gill structural changes induced by toxicants and other irritants: a statistical review. *Can. J. Fish. Aquat. Sci.* 42: 630 – 648.
- Mensink, B. J. W. G., Montforts M., Kijkhuizen-Maslankiewicz, I., Tibosch H., and Linders, J. B.H. J (1995) Manual for summarising and evaluating the environmental aspects of pesticides. Report no. 679101022. National Institute of Public Health and Environmental Protection, Bilthoven, the Netherlands.
- Mohamed, F.A.S (2008) Bioaccumulation of selected metals and histopathological alterations in tissues of *Oreochromis niloticus* and *Lates niloticus* from lake Nasser, Egypt. *Global Veterinaria*, 2 (4): 205-218.
- Murugaian, P et al (2008) Effect of Temperature on the behavioural and physiological responses of catfish *Mystusgulis*(Hamilton). *J. Appl. Sci Res* 4(11):1454-1457.
- OECD, Organization for Economic Cooperation and Development (1992) Guideline for the testing of chemicals: *Fish Acute Toxicity Test*, No 203.
- Palanichamy, S and P Baskaran (1995) Selected biochemical and physiological responses of the fish *Channa striatus* as biomonitor to assess heavy metal pollution in fresh water environment, *J. Ectoxicol. Environ. Monit.* 5:131-138.
- Paulose, P.V (1989) Histological changes in relation to accumulation and elimination of inorganic and methyl mercury in gills of *Labeo rohita* (Hamilton) *Indian J Exp. Biol.* 27: 146-150.
- Perry S.F. & Laurent P (1993) Environmental effects on fish gill structure and function. In: Rankin J.C. & Jensen F.B. (ed.), *Fish Ecophysiology*. Chapman and Hall, London, pp. 231-264.
- Sprague, J. B (1969) Measurement of pollutant toxicity to fish I. Bioassay methods for acute toxicity. *Wat. Res.*, 8: 793–821.
- Tilak K S, Veeraiah K and Yacobi K. (2001) Studies on histopathological changes in the gills liver and kidney of *Ctenopharyngodon indellus* (Valen.) exposed to technical fenvalerate and EC 20%. *Pollution Research* 20 (3): 387-393.
- Velmurugan B, Selvanayagam M, Cengiz E I and Unlu E. (2007) Histopathology of  $\lambda$ -cyhalothrin on tissues such as the gills, kidney, liver and intestine of *Cirrhinus mrigala* (Ham.). *Environmental Toxicology and Pharmacology* 24: 286-

\*\*\*\*\*